

Pink Tooth –Diagnosis & Management- A Case Report

Pravin Patil¹, Sandeep Pimpale^{*2}, Ashish Mandwe³, Anil Ricchawal⁴, Santosh Kiswe⁵

¹Assistant Professor & MDS in the Department of Conservative Dentistry and Endodontics, Nair Hospital Dental College, Mumbai, Maharashtra, India

^{*2}Assistant Professor & MDS in the Department of Periodontics, Nair Hospital Dental College, Mumbai, Maharashtra, India

³Associate Professor & MDS in the Department of Conservative Dentistry and Endodontics, Nair Hospital Dental College, Mumbai, Maharashtra, India

⁴Assistant Professor & MDS in the Department of General Dentistry, Grant Medical college & J.J Group of Hospitals, Mumbai, Maharashtra, India

⁵Senior Lecturer & MDS in the Department of Conservative Dentistry and Endodontics, Dhanwantari Dental College, Parbhani, Maharashtra, India

ABSTRACT

Internal root resorption is described as a resorptive defect of the internal aspect of the root with formation of granulation tissue or deposition of metaplastic tissue as a result of chronic inflammation and bacterial invasion of the pulp tissue. It is generally discovered in teeth with previous history of trauma and the affected tooth is usually asymptomatic. Proper history, good diagnosis and early treatment improve the overall prognosis of such teeth. The present report demonstrates a progressive, non-perforating, inflammatory internal resorption involving the middle third of permanent maxillary left central incisor which was treated by non-surgical orthograde means and obturated with thermoplastized gutta percha technique.

Keywords: Inflammatory internal resorption, Diagnosis, Management.

Introduction

Resorption is defined as a condition associated with either a physiologic or a pathologic process resulting in loss of dentin, cementum or bone.[1] Based on the location, root resorption can be internal or external.[2] Internal resorption (IR) is rare in permanent teeth. Rather external resorption is more common & often misdiagnosed as internal resorption[3]. The exact pathogenesis of IR is unknown. The most accepted explanation states that the chronic inflammation of the coronal pulp caused by continuous bacterial stimulation triggers transformation of normal pulp tissue which is relatively apically situated into granulation tissue with multinucleated giant cells. This granulation tissue accompanied by damage to predentin layer initiates the resorption of underlying dentin[3].

**Correspondence*

Dr. Sandeep Pimpale

Assistant Professor & MDS in the Department Of Periodontics, Nair Hospital Dental College, Mumbai, Maharashtra, India.

E Mail: sandeepudentist3@gmail.com

The etiological factors proposed for the loss of predentin, includes trauma, caries, periodontal infections, dystrophic changes in vital pulp induced by calcium hydroxide, the heat generated during restorative procedures on vital teeth.[4-10] Trauma is found to be the most common predisposing factor(45% cases) for IR followed by carious/periodontal lesions (14% cases).[11]Clinically, internal root resorption is usually asymptomatic and it is often coincidentally diagnosed on periapical radiograph which was targeted for some other teeth in the area. Internal resorption can be found in all areas of the root canal but when it is located in the cervical part of the canal, a clinical aspect of “pink spot” which is pathognomonic of IR can be observed. The pink colour is related to the highly vascularized granulation tissue. As the pulp becomes necrotic this colour turns dark grey.[12]

Case Report Proper

A 32-year-old male patient was referred to the Department of Conservative Dentistry & Endodontics

from Oral & Maxillofacial Surgery Department regarding radiolucency involving mid-root portion of upper left central incisor evident on a orthopentograph which was shot regarding the disimpaction of mandibular third molars. The patient's medical history was absolutely non-contributory. No episode of pain in relation to upper left central incisor but the patient did give history of minor trauma to his anterior teeth about

9 years back. On clinical examination, tooth no 21 (Federation Dentaire Internationale) was discoloured and showed proximal surface caries involving mesial surface of the tooth. No fracture was evident in relation to the tooth. [Fig 1 & 2]The vertical and the axial percussions were unproductive. No swelling, sinus tract or erythema was detected.

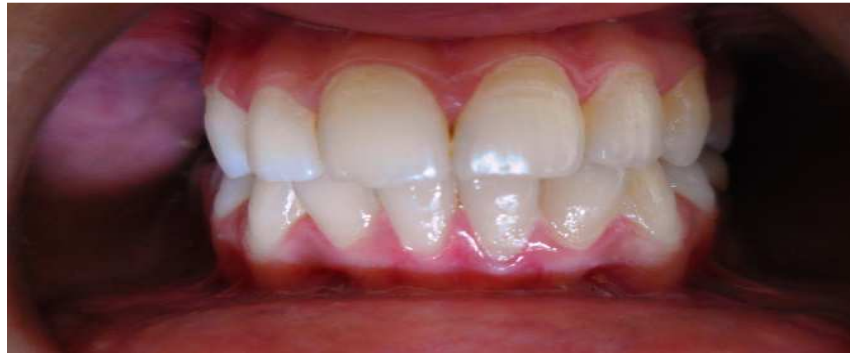

Figure 1: Pre-operative photograph – labial view – tooth # 21

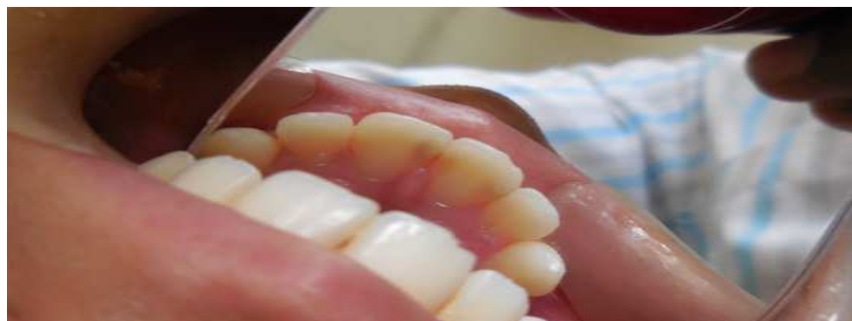

Figure 2: Pre-operative photograph – palatal view – tooth # 21

The tooth 21 responded normally to thermal and electric pulp testing. Intra-oral periapical radiograph revealed a well-defined, radiolucent, round to oval enlargement of the root canal space mainly involving

the middle third portion of the canal. The outline of root canal wall was distorted in the area of resorptive defect. [Fig 3]

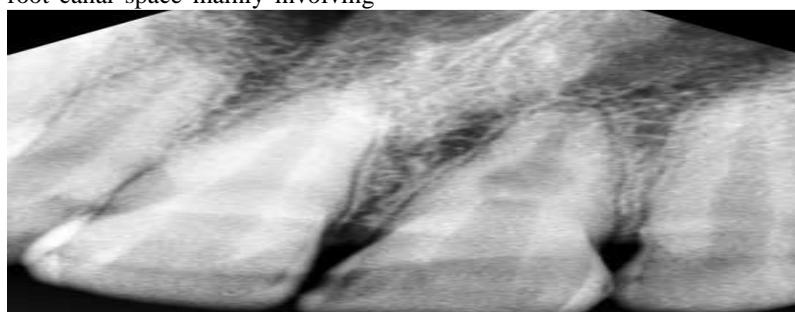


Figure 3: Pre-operative intra-oral periapical radiograph showing internal resorptive defect in the mid-root portion of tooth # 21

No radioopacity indicating deposition of any metaplastic tissue was evident in the resorptive defect. Based on history, clinical and radiographic findings a diagnosis of an internal inflammatory root resorption was established. As the diagnosis was done, vital pulpectomy followed by completion of root canal treatment was the treatment planned for the patient. Tooth no 21 was isolated under rubber dam and it was disinfected with 5.2 % sodium hypochlorite. A

conservative access opening was done & the canal was negotiated with precurved no 10 K-File upto the apex. The coronal pulp was non-vital while the bleeding was induced on negotiation of middle third of the canal space. Coronal flaring of the canal was carried out by Gates–Glidden drills (sizes 3&4).The working length was established with an electronic apex locator (Root ZX-2 J-Morita, USA).Radiograph was taken to reconfirm the working length. [Fig 4]

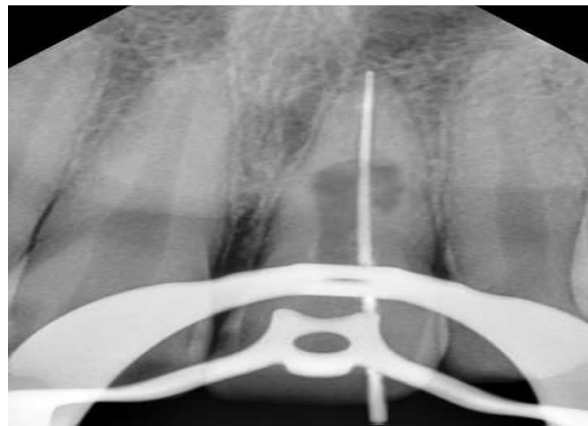

Figure 4: Working length determination

The root canal shaping & cleaning was performed with manual stainless- steel hand files which was accompanied by copious irrigation of 5.2% sodium hypochlorite [NaOCl] .The NaOCl irrigation was passively activated using ultrasonic files.[

EndoActivator ,Dentsply Maillefer] The master apical file was ISO 0.50.The canal was dried with paper points and calcium hydroxide [Ca(OH)₂] intracanal medicament was placed in the canal.[Fig 5]

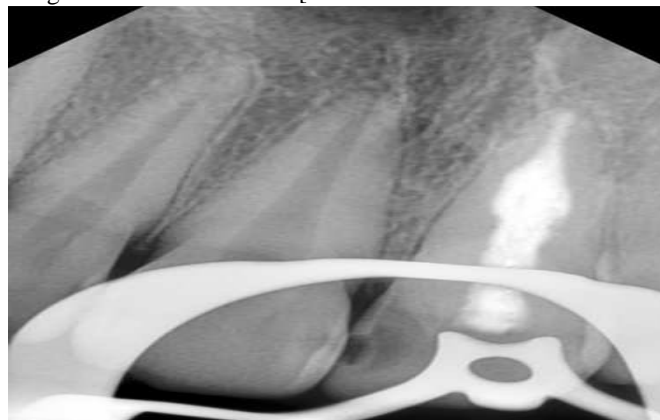


Figure 5: Placement of calcium hydroxide intracanal medicament in tooth # 21.

After 1 week, sterile water was used to flush the calcium hydroxide from the canal. After drying the canal, obturation was done with AH-Plus sealer (Dentsply, Maillefer) and gutta percha using warm

verticle compaction technique [System B and Obtura III gun].Post-endodontic restoration was done with composite resin restoration. Root canal filling was verified with the postoperative radiograph. [Fig 6]

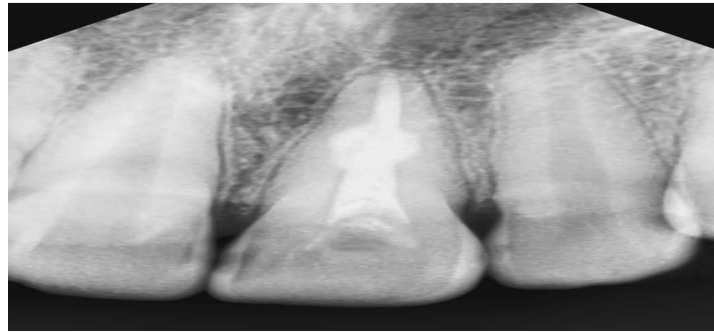


Figure 6: Post obturation intra-oral periapical radiograph–tooth # 21

Discussion

The case report demonstrates inflammatory internal resorption of a permanent maxillary central incisor which was progressive and non-perforating. Internal root resorption can be either inflammatory resorption or replacement resorption.[3] The current case exemplifies 'inflammatory 'internal resorption as radiographically the resorptive defect is appearing as a well-defined radiolucent area distorting the original outline of root canal with no trace of radiopaque metaplastic tissue deposition in the area of resorption [Fig 3] Internal inflammatory resorption can be transient or progressive. [1, 13] In progressive internal resorption , the pulp tissue which is apical to the resorptive lesion is usually vital. A vital pulp can only provide clastic cells to the resorptive defect so that the resorption can continue[1,14].The present case demonstrates a progressive internal resorption since the pulp was vital in middle third portion as indicated by pulp vitality tests and confirmed during shaping & cleaning of the root canal .The differential diagnosis of the current case of internal root resorption mainly includes external root resorption which is nothing but the external form of pathological root resorption. These two types of resorptions can be easily differentiated radiographically by changing the horizontal angulation of X-ray exposure.[3]In external resorption, the lesion moves in opposite direction (mesial or distal)as the horizontal angulation of X-ray exposure is changed . In current case the IR lesion is located next to the root canal outline with no change in lesion position even after the change of the exposure angle. In external root resorption the lesion is always associated with surrounding bone resorption which is evident radiographically on the lateral aspect of the root. No such bone loss is evident radiographically in present case.[Fig 3]Unlike in external root resorption where root canal outline can be seen running undistorted through the defect area,in current case the canal outline

is completely distorted in resorption area [Fig 3]A conservative access cavity preparation was done. Rather, in IR cases the access cavity preparation should be as conservative as possible to preserve tooth structure and avoid further weakening of the tooth which is already weak due to the resorptive defect.As in present IR case the tooth was still vital in apical portion, the treatment of choice was pulpectomy and thorough debridement of the canal. The resorptive process of root canal walls is immediately stopped after removal of the chronically inflamed pulp tissue, as the resorbing cells are cut off from the blood supply and nutrients.[15]Thus the successful outcome of IR depends completely upon the removal of all chronic inflamed or necrotic pulp remnants from the root canal. However in IR case this therapeutic objective cannot be achieved within the boundary of the oval-shaped resorptive defect simply with manual or rotary file instrumentation. Ultrasonic activation of irrigants is a very effective method to remove debris lodged in inaccessible resorptive sites.[16] Hence for the complete debridement of the resorptive defect, the manual instrumentation was accompanied by ultrasonically activated NaOCL irrigation.[17]Ca(OH)₂ was placed as intracanal medicament for 1 week as the use of calcium hydroxide as an intracanal dressing has proven to necrotize residual pulp tissue & maximize the effect of disinfection procedures.[18-20] In present case the obturation was completed with warm vertical compaction and thermoplasticized gutta-percha techniques.The resorptive defects are found to be efficiently sealed with the warm vertical compaction and thermoplasticized gutta-percha techniques.[21]

Conclusion

Inflammatory internal root resorption (IRR) is usually asymptomatic and is commonly detected during routine radiographic examination. As far as management is

concerned, root canal treatment remains the only treatment of choice for such teeth. Recent advances in endodontic diagnostic techniques, ultrasonic activation of chemical irrigants, thermoplastic root canal filling techniques etc. offer high opportunities for the complete rehabilitation of even severely resorbed teeth.

References

1. Ne RF, Witherspoon DE, Gutmann JL: Tooth resorption. *Quintessence Int.* 1999;30(1):9–25.
2. Patel S, Kanagasingham S, Pitt Ford T: External cervical resorption: A review. *J Endod.* 2009;35(5):616–25
3. Sigurdsson A, Trop M, Chivian M: The role of endodontics after dental traumatic injuries. Cohen S, Hargreves KM, *Pathways of the pulp* 9 th edition, 2006, 635.
4. Andreasen JO : Luxation of permanent teeth due to trauma: a clinical and radiographic follow up study of 189 injured teeth. *Scand J Dent Res* 1970;19:273–286.
5. Silveria FF, Nunes E, Soares JA, Ferreria CL, Rotstein I: Double ‘pink tooth’ associated with extensive internal root resorption after orthodontic treatment: a case report. *Dent Traumatol* 2009;25(3):43–47.
6. Cabrini R, Maisto O, Manfredi E : Internal resorption of dentin: his- topathologic control of eight cases after pulp amputation and cap- ping with calcium hydroxide. *Oral Surg Oral Med Oral Pathol* 1957; 10:90–96.
7. Rabinowitch BZ: Internal resorption. *Oral Surg Oral Med Oral Pathol* 1972;33(2):263–282
8. Ashrafi MH, Sadeghi EM: Idiopathic multiple internal resorptions: report of case. *ASDC J Dent Child* 1980;47(3):196–199.
9. Brady J, Lewis DH: Internal resorption complicating orthodontic tooth movement. *Br J Orthod* 1984;11(3):155–157.
10. Walton RE, Leonard LA: Cracked tooth: an etiology for ‘idiopathic’ internal resorption? *J Endod* 1986;12:167–169
11. Caliskan MK, Türkün M: Prognosis of permanent teeth with internal resorption: a clinical review. *Endod Dent Traumatol* 1997;13:75–81.
12. F. F. Silveira, E. Nunes, J. A. Soares, C. L. Ferreira, and I. Rotstein: “Double “pink tooth” associated with extensive internal root resorption after orthodontic treatment: a case report,” *Dental Traumatology* 2009;25(3) ;43–47.
13. Tronstad L: *Clinical endodontics.* 2nd ed. New York: Thieme; 2003; 146–6
14. Patel S, Ricucci D, Durak C, Tay F. Internal root resorption: A review. *J Endod.* 2010;36(7):1107–21.
15. Andreasen JO, Bakland LK: Pathologic tooth resorption. In: Ingle JI, Bakland LK, Baumgartner JG (eds). *Ingle’s endo- dontics* 6. 6th edition, BC Decker, Inc., Hamilton, 2008, 1358– 1382.
16. Burleson A, Nusstein J, Reader A, Beck M: The in vivo evaluation of hand/rotary/ultrasound instrumentation in necrotic, human mandibular molars. *J Endod.* 2007;33:782–7.
17. M. Haapasalo and U. Endal: “Internal inflammatory root resorption: the unknown resorption of the tooth,” *Endodontic Topics*, vol. 14, pp. 60–79, 2006.
18. Bystrom A, Claesson R, Sundqvist G: The antibacterial effect of camphorated paramonochlorophenol, camphorated phenol and calcium hydroxide in the treatment of infected root canals. *Endod Dent Traumatol.* 1985;1(5):170–5.
19. Han GY, Park SH, Yoon TC: Antimicrobial activity of calcium hydroxide containing pastes with enterococcus faecalis in vitro. *J Endod.* 2001;27:328–32.
20. Buck RA, Cai J, Eleazer PD, Staat RH, Hurst HE: Detoxification of endotoxin by endodontic irrigants and calcium hydroxide. *J Endod.* 2001;27(5):325–7.
21. Gencoglu N, Yildirim T, Garip Y, Karagenc B, Yilmaz H : Effectiveness of different gutta-percha techniques when filling experimental internal resorptive cavities. *Int Endod J.* 2008;41(10):836–42.

Source of Support: Nil

Conflict of Interest: None