

---

## Radiographic manifestations of systemic diseases in jaw bones: A systematic review

Preeti Dhir<sup>1</sup>, Chaya M David<sup>2</sup>, Keerthi G<sup>3</sup>

<sup>1</sup>Senior Lecturer, Department of Oral Medicine, Diagnosis and Radiology, Desh Bhagat Dental College and Hospital, Muksar (Punjab), India

<sup>2</sup>Professor and Head, Department of Oral Medicine, Diagnosis and Radiology, Dayananda Sagar College of Dental Sciences, Bangalore (Karnataka), India

<sup>3</sup>Senior Lecturer, Department of Oral Medicine, Diagnosis and Radiology, KLE Society's Dental College, Bangalore (Karnataka), India

---

### ABSTRACT

Disorders of the endocrine system, bone metabolism and other systemic diseases may have an effect on the form and function of bone and teeth. The dental radiograph provides information which is valuable in the diagnosis of systemic disease. It provides the first clue that leads to an early diagnosis of the disease. Oral radiographic manifestations are not always present in given patient and the degree of expression is highly variable and it may reflect the severity and duration of the systemic disease. Many systemic diseases have oral manifestations. The oral cavity might well be thought of as the window to the body because oral manifestations accompany many systemic diseases. These oral manifestations must be properly recognized if the patient is to receive appropriate diagnosis and referral for treatment. This article highlight the radiographic manifestations of systemic diseases in jaw bones so as to enable the dental practitioner to diagnose the systemic diseases that manifest in the jaw bones for early diagnosis and treatment of the disease.

**Keywords:** Blood Disorders; Endocrine disorders; Metabolic disorders; Radiographic features.

---

### Introduction

Systemic diseases include those lesions that affect the whole of the body. In many instances, oral involvement precedes the appearance of other symptoms or lesions at other locations. The teeth become malformed or hypo plastic due to systemic, nutritional or environmental influences during odontogenesis. Any of the factors which regulate bone metabolism such as dietary calcium, phosphate, vitamin D and hormones such as parathormone and calcitonin, may influence the alveolar bone in health and disease.[1] More than 99% of the total body calcium is contained within skeletal structure.

The bone is constantly remodeling and approximately 5 to 10% of the total bone mass is replaced each year. The turnover rate of trabecular bone is 20% which is higher than that for cortical bone which has turnover rate of 5%. The effects of systemic diseases of bone are brought about by changes in the number and activity of osteoclasts, osteoblasts and osteocytes.[2] Despite development of various cross sectional imaging modalities, the radiograph still remains the first and the most important investigation.[3] Diseases which are now known to have an effect upon the teeth and supporting structures are numerous, and include endocrine disturbances, skeletal, developmental disturbances of unknown cause and many others.

---

\*Correspondence

**Dr. Preeti Dhir**

Kumra Dental Clinic  
Railway road, Zira, Ferozepur,  
Punjab, India  
Ph no: 919646866684  
Email: [drpreetikumra@yahoo.in](mailto:drpreetikumra@yahoo.in)

### Endocrine disorders

The teeth and jaws reflect endocrine dysfunction as the other parts of the skeleton and the dental defects produced may remain as permanent record of the disorder. Any quantitative change in the hormones secreted by these glands, be it overproduction or

underproduction, may lead to disturbances in growth and maturation of bones and teeth.[4]

### **Hyperpituitarism**

Hyperpituitarism results from hyper functioning of the anterior lobe of the pituitary gland, which increases the production of growth hormones. An excess of growth hormone causes overgrowth of all tissues in the body still capable of growth.

### **Radiographic features**

The enlargement of the jaws occur especially the mandible. The increase in length of dental arches results in spacing of the teeth and the angle between the ramus and body of the mandible may increase in acromegaly. (Fig 1) Thickness and height of alveolar processes may also increase.[2] In case of acromegaly, the palatal vault may become flattened because of downward growth. The tooth crowns are usually normal in size, although the roots of posterior teeth often enlarge as a result of hypercementosis. The permanent teeth are normally shaped but macrodontia is noted in about 50% of cases.[5] In some cases the growth at the condyle exceeds that of the alveolar processes so that the increase in the vertical depth of the ramus is greater than that of the body of the jaw and consequently the upper and lower teeth fail to come into the proper occlusion.[6]

### **Hypopituitarism**

Hypopituitarism results from reduced secretion of pituitary hormones. [2]

### **Radiographic features**

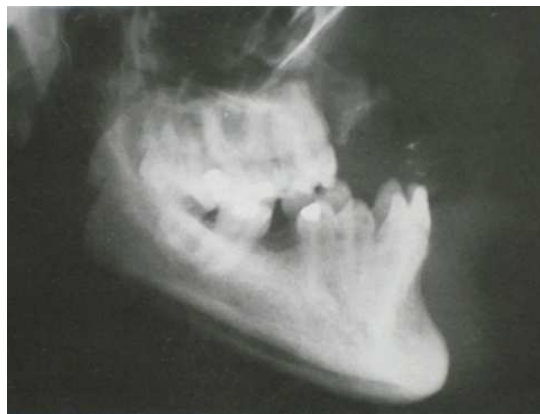Small size of the maxilla and mandible with overcrowding of the teeth in these bones and retention of permanent teeth in the maxillary and mandibular shafts occur.[2] The crowns of permanent teeth are of normal size and shape but root formation is incomplete and the apical foramen and pulp chamber are wider than normal.[5] A study conducted showed that, delay in skeletal age ranged from 24.8% to 32.3%, the average being 27.9%. There was much delay in dental age ranging from only 4.3 to 19.7% the average delay being approximately 9%. [7]

### **Hyperthyroidism**

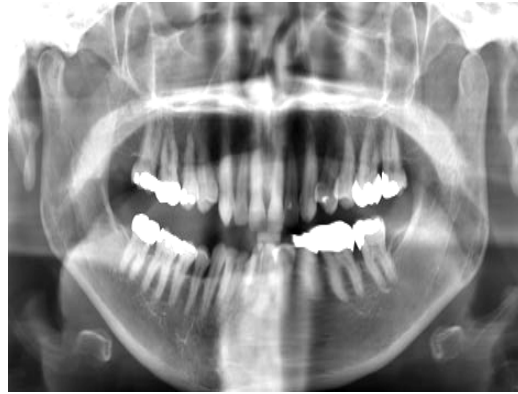
Hyperthyroidism is a disorder that occurs when the thyroid gland makes more thyroid hormone than the body needs. It is sometimes called thyrotoxicosis.[2]

### **Radiographic features**

There may be generalized osteoporosis and generalized decrease in bone density occurs. (Fig 2)



**Fig 1: Acromegaly manifested as excessive growth of the mandible, resulting in a Class III skeletal relationship of the jaws**



**Fig 2: Panoramic radiograph showing generalized decrease in bone density**

### ***Hypothyroidism***

Hypothyroidism usually results from insufficient secretion of thyroid hormones by the thyroid glands despite the presence of thyroid stimulating hormone.[2]

### ***Radiographic features***

The maxilla appears widened and due to shortening of the base of the skull, the bridge of nose is retracted and mandible appears under developed. The jaws may reveal hypocalcification. The roots of the teeth are short with thinning of lamina dura and external root resorption.<sup>2</sup> (Fig 3) The patients with adult myxedema often exhibit alveolar bone resorption.[5]

### ***Hyperparathyroidism***

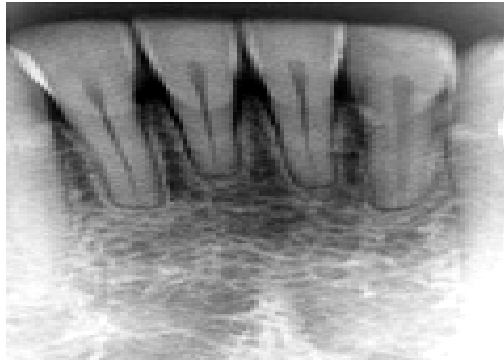Hyperparathyroidism was first described as a bone disease in **1891 by Von Recklinghausen**. In **1904 Askanazy** was the first to describe a patient with a parathyroid tumor and osteitis fibrosa cystica. **Jackson and Frame in 1972** estimated that 1 in 1000 patients examined in a general diagnostic clinic will have hyperparathyroidism.[8]

### ***Radiographic features***

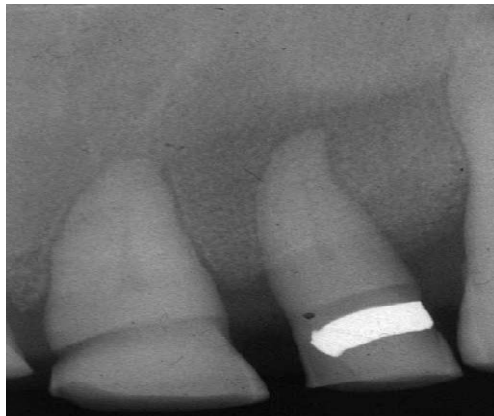
Hyperparathyroidism is the most common cause of osteoporosis of jaws. Demineralization and thinning of cortical boundaries often occur in jaws in cortical boundaries such as the inferior border, mandibular

canal and the cortical outline of the maxillary sinuses. A change in normal trabecular pattern occurs resulting in a **ground glass** appearance (Fig 4) of numerous small randomly oriented trabeculae.[2] Another manifestation of hyperparathyroidism in the jaws is the presence of a cyst. One or many cysts may be present at the same time. They present as area of having well defined margin but without any cortical border at the periphery.[6]

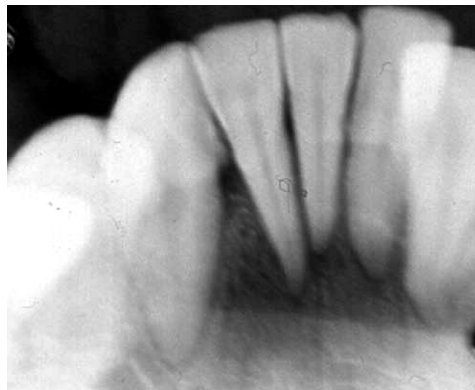As the disease progresses other bony lesions occur, such as brown tumor of hyperparathyroidism so named due to the brown color that results due to hemorrhage and hemosiderin deposition within the tumor. Radiographically the tumor appears as a unilocular or multilocular radiolucency.[9] The lesions have variably defined margin and may produce cortical expansion.[2] Osteitis fibrosa cystica develops in long-standing brown tumors and is the result of central degeneration and fibrosis of the tumor.<sup>2</sup> In some of the cases, it was possible to mould the shape of the jaw with the fingers but the teeth returned to their original position when the pressure was released refer to as the rubber jaw.[6] Dental changes have been described in detail by **Worth in 1963**: There may be the loss of the crypt wall; eruption appears too far advanced for the degree of root development; the roots appear very pointed and tapered especially at the apical third and the pulp chambers appear to be abnormally enlarged. Periapical radiograph reveal loss of the lamina dura in patients with hyperparathyroidism. (Fig 5)



**Fig 3: IOPA radiographs showing external root resorption**



**Fig 4: Demineralized maxillary bone with ground-glass appearance and loss of lamina dura**



**Fig 5: IOPA radiograph showing loss of lamina dura**

**Hypoparathyroidism**

Decreased secretion of parathyroid hormone is called hypoparathyroidism. It is an uncommon condition. It leads to hypocalcemia.[10]

**Radiographic features**

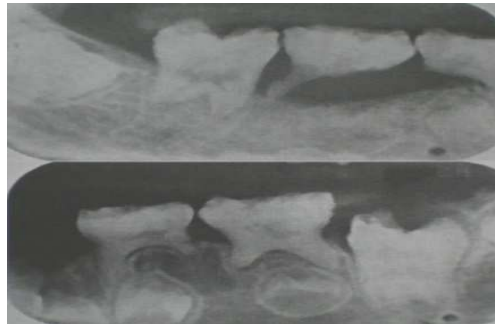
The maxilla and mandible may become abnormally dense despite a lowered serum calcium level. The trabeculae are increased in number, presenting an unusually well calcified appearance. Teeth reveal enamel hypoplasia which is manifested by irregular and malformed crowns. (Fig 6) Radio graphically hypoplasia reveals spot like radiolucencies and horizontal bands of decreased density. [5] The dilacerations of root and external root resorption occur. [2, 11]

**Metabolic disorders****Rickets**

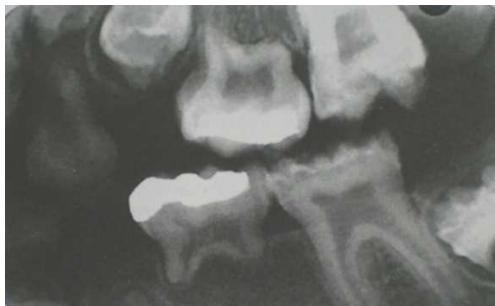Defective mineralization of cartilage taking place in the epiphyseal growth plate, leading to widening of the long ends of bones, growth retardation and skeletal deformities in children.

**Radiographic features**

In rickets, jaw cortical structures, such as the inferior mandibular border or the walls of the mandibular canal, may be thin. Within the cancellous portion of the jaws, the trabeculae become reduced in density, number, and thickness. In severe cases, the jaws appear so radiolucent that the teeth appear to be bereft of bony support. Most cases of osteomalacia produce no radiographic manifestations in the jaws. However, when present there may be an overall radiolucent appearance and sparse trabeculae. Rickets in infancy or early childhood may result in hypoplasia of developing dental enamel. (Fig 7) If the disease occurs before 3 years, such enamel hypoplasia is fairly common. Grossly enlarged pulp chambers of deciduous teeth and narrowing of the periodontal ligament space is seen.[2]



**Fig 6: A) Pseudohypoparathyroidism- induced dental anomalies B) IOPA radiograph showing coronal area of hypocalcification**



**Fig 7: Rickets may cause thinning (hypoplasia) or decreased mineralization (hypocalcification) of the enamel as is seen in this bitewing view**

***Hypophosphatemia/ Hypophosphatemic Rickets/  
Familial Hypophosphatemia/ Refractory Rickets/  
Phosphate diabetes***

Hypophosphatemic Rickets was first reported by **Albright et al in 1937**, is a syndrome showing marked hypophosphatemia, short stature and rickets.[12] Hypophosphatemia represents a group of inherited conditions that produce renal tubular disorders resulting in excessive loss of phosphorus. Normal calcification of the osseous structures requires the correct amount and ratio of serum calcium and phosphorus.[2]

***Radiographic features***

The jaws are usually osteoporotic and in extreme cases are remarkably radiolucent. Cortical boundaries may be unusually radiolucent or not apparent. Other possibilities include fewer visible trabeculae and a granular trabecular pattern. There is no evidence of the normal cortical layer of bone around the follicle of developing teeth as a result they appear unsupported by solid tissue.<sup>2</sup> **Worth in 1963** described a step defect at the apex of primary teeth, where the pulpal margin of dentin appears intact and outside margin is resorbed. The enamel hypoplasia may also be seen in some patients, as the condition is a hereditary effect often occurs before the patient is 3 years of age, when the enamel is forming. The teeth may be poorly formed, with thin enamel caps and large pulp chambers which extend up to the dentinoenamel junction and root canals. The lamina dura may become sparse, and cortical boundaries around tooth crypts may be thin or entirely absent.[2] The presence of taurodontism in the first and second permanent molars in many male patients has been reported.[13]

***Hypophosphatasia***

Hypophosphatasia, a hereditary disease was first recognized as entity by **Rathbun in 1948**. [14] Hypophosphatasia is a rare inherited disorder that is caused by either a reduced production or a defective function of alkaline phosphatase. This enzyme is required for normal mineralization of osteoid.[2] Hypophosphatasia is caused by a basic defect in the gene-encoding for tissue nonspecific alkaline phosphatase (TNSALP); in humans it hydrolyses phosphate from pyridoxal 5'-phosphate, pyrophosphate and phosphoethanolamine. The resulting inorganic phosphate is utilized in the production of hydroxy-

apatite crystals which are necessary for bone, enamel, dentin and cementum formation.

***Radiographic features***

A generalized radiolucency of the mandible and maxilla is evident. The cortical bone and lamina dura are thin, and the alveolar bone is poorly calcified and may appear deficient.[2] Both primary and permanent teeth have a thin enamel layer and large pulp chambers and root canals. (Fig 8) The crowns appeared small and bulbous reach the cervical area. Cervical constriction was also present.[2, 15]

***Renal osteodystrophy***

Renal osteodystrophy refers to skeletal changes that result from chronic renal disease and that are caused by disorders in calcium and phosphorous metabolism, abnormal vitamin D metabolism and increased parathyroid activity.[16]

***Radiographic features***

In renal osteodystrophy the density of the mandible and maxilla may be less than normal and occasionally may be greater than normal. The manifestations include loss of trabeculation, ground glass appearance, giant cell lesions or brown tumors and metastatic calcification. The compact bone of the jaws may become thinned and eventually disappear evident by the loss of the lower border of the mandible, the cortical margins of the inferior dental canal and floor of antrum and the loss of lamina dura. Spontaneous and pathologic fractures may occur with the thinning of these areas of compact bone and may complicate dental extractions. In the presence of significant decalcification the teeth will appear more radiopaque. The lamina dura may be absent or less apparent in instances of bone sclerosis. Periapical radiolucencies and root resorption also may be associated with this gradual loosening of the dentition.[16]

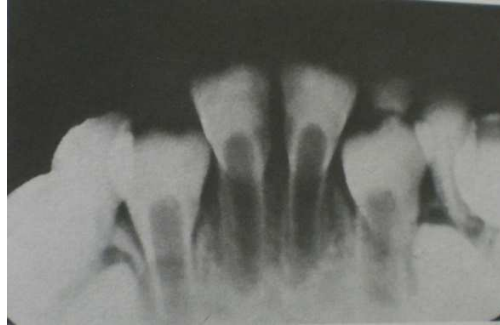***Osteopetrosis/ Marble bone disease/ Albers Schonberg disease***

The term osteopetrosis is derived from greek word "osteo" meaning bone and "sclerosis" meaning bone. It was first described by Albers Schonberg in 1904. Osteopetrosis is an inherited skeletal condition characterized by increased bone radiodensity [17]

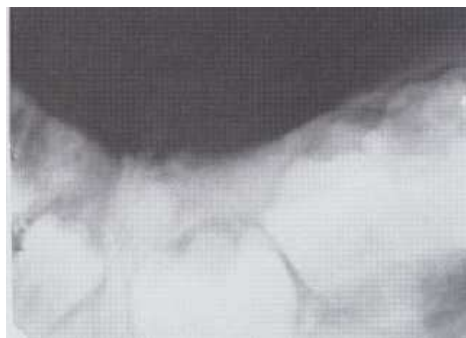
**Radiographic features**

The increased radiopacity of the jaws may be so great that the radiographic image may fail to reveal any internal structure and even the roots of the teeth may not be apparent. (Fig 9) The increased bone density and

relatively poor vascularity results in a susceptibility of the mandible to osteomyelitis, usually from odontogenic inflammatory lesions. The lamina dura and cortical borders may appear thicker than normal.[2]



**Fig 8: Hypophosphatasia results in teeth with thin enamel, thin root dentin, and large pulp chambers**



**Fig 9: Osteopetrosis, showing dense alveolar bone and embedded, poorly formed teeth**

**Sickle cell anemia:** Sickle cell anemia was first described by **Herrick in 1910**. The name is derived from the peculiar appearance of sickle or crescent shaped erythrocytes found in the circulating blood.8 Sickle cell anemia is a hereditary type of chronic hemolytic anemia transmitted as a mendelian dominant non sex linked characteristic, which occurs almost exclusively in blacks and in whites of Mediterranean origin.[14]

**Radiographic features**

Radiologic features of sickle cell anemia result from one of the characteristics of the disease: marrow hyperplasia producing bone resorption and prominence and rearrangement of trabeculae, thrombosis and infarction causing mainly sclerotic change, secondary

osteomyelitis resulting in bone rarefaction.[8] **Robinson and Sarnat** first described alterations of the trabecular pattern in the jaws of patients with sickle cell anemia. The major pattern of change is an increase in the area of marrow generally accompanied by a reduction in the complexity of the trabecular pattern. This pattern is consistent with the erythroblastic hyperplasia and coarsening of the residual trabeculae.[18] There is generalized osteoporosis which occurs because of a decrease in the volume of trabecular bone which becomes coarser giving ground glass appearance. There is thinning of cortical plates of the inferior border of mandible. The lamina dura appears more prominent against the background of increased radiolucency. In the interdental portions of the jaws, the trabeculae are coarser and appear as horizontal rows creating **step ladder effect**. Bone

marrow hyperplasia may cause enlargement and protrusion of the maxillary alveolar ridge.[2, 19]

**Thalassemia/ Cooley's anemia/ Mediterranean disease/ Erythroblastic anemia**

The earliest case was described in 1925; it was only after 1940, that the genetic variants of this disorder were appreciated.[20] The thalassemia group of anemia is a heterogeneous group characterized by diminished synthesis of  $\alpha$  or  $\beta$  globin chain of hemoglobin A. The disease is inherited as an autosomal dominant trait and exhibits a racial predilection.[14]

**Radiographic features**

Severe bone marrow hyperplasia prevents pneumatization of the paranasal sinuses, especially the maxillary sinus and causes expansion of the sinus that result in malocclusion. The jaw appears radiolucent with thinning of the cortical borders and enlargement of the marrow spaces.[19] The trabecular pattern is characterized by the apparent coarsening of the some trabeculae and the blurring and disappearance of others resulting in **salt and pepper** effect. [14] The lamina dura is thinned and the roots of the teeth may be short. The roots of the first molar and central incisors

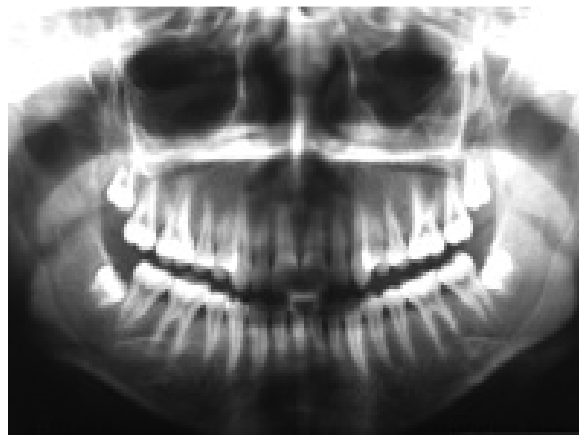are spike shaped and taurodontism was present. (Fig 10) [21]

**Progressive systemic sclerosis/ Scleroderma / Dermatosclerosis/ Hidebound disease**

Progressive systemic sclerosis is a generalized connective tissue disease that causes excessive collagen deposition resulting in hardening i.e. sclerosis of the skin and other tissues. The involvement of the gastrointestinal tract, heart, lungs and kidneys usually results in more serious complications. The cause of the disease is unknown.[22]

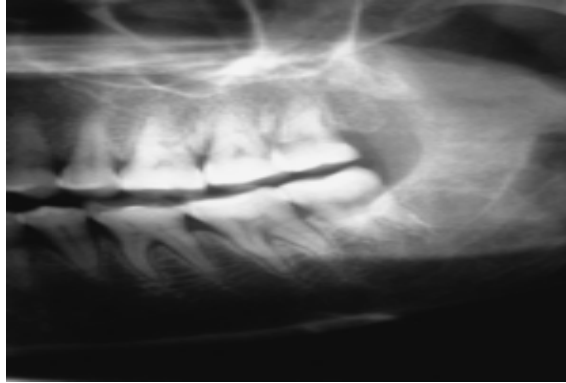
**Radiographic features**

An unusual pattern of mandibular resorption at the site of muscle attachment involving the ascending ramus, condyle, mandibular angle, coronoid process and antegonial notch. The tightness of the skin in the disease causes pressure resorption of the bone. 22 The increase in the width of the periodontal ligament spaces around the teeth. The increased collagen synthesis in the periodontal ligament leads to increase in the bulk of the ligament, which is accommodated at the expense of alveolar bone, thus causing an increase in the width of the periodontal ligament space. (Fig 11)The lamina dura remains normal. [23, 24]



**Fig 10: Panoramic radiograph demonstrating mandibular molars with thin, spiky roots**





**Fig 11: Cropped panoramic radiograph of a patient with systemic sclerosis showing widening of the periodontal ligament space with respect to mandibular molars**

***Differential diagnosis of diseases causing generalized rarefactions of jaw bones***

The diseases causing generalized rarefactions of jaw bones are hyperparathyroidism, osteomalacia, hereditary hemolytic anemia, hypoparathyroidism, hypophosphatemia. The differential diagnosis of diseases manifesting as rarefactions in jaw bones requires a detailed history and careful physical examination. In addition to causing rarefactions of the skeleton the conditions produce other systemic changes which are identified by the general clinical examination and laboratory tests supplementing the radiographic findings. There is tendency to diagnose a rarefaction of

the jaw bones accompanied by a loss of lamina dura as hyperparathyroidism. The lamina dura is more apt to be deficient in osteoporosis than osteomalacia. The lamina dura characteristically appears normal in the hemolytic anemia especially sickle cell anemia. Pseudofractures and green stick fractures in adults are almost pathognomonic for osteomalacia. The diseases that occur primarily in young persons are thalassemia and sickle cell anemia. The older persons over 40 years are affected primarily by hyperparathyroidism especially secondary and tertiary; osteoporosis and osteomalacia.[25] Laboratory values may be useful in differentiating among the different diseases. (Table 1)

**Table 1: Laboratory values of the different metabolic diseases**

Comparison of serum values in metabolic diseases			
Disease	Calcium	Phosphorus	Alkaline phosphatase
Primary hyperparathyroidism	Increased	Decreased	Increased
Secondary hyperparathyroidism	Normal to decreased	Increased	Increased
Tertiary hyperparathyroidism	Increased	Normal to increased	Increased
Osteoporosis	Normal	Normal	Normal
Vitamin D deficiency	Decreased	Decreased	Increased
Hypophosphatemia	Normal	Decreased	Increased

**Conclusion**

The mouth is frequently involved in conditions that affect the skin or other multiorgan diseases. In many instances, oral involvement precedes the appearance of other symptoms or lesions at other locations. Due to the complexity of the human body, it is only natural that the dental, oral or maxillary regions exhibit anomalies which arise systemically.

Radiography of the oral and maxillary regions which is mainly concerned with the teeth and bones play a crucial role in diagnosis. The clinical images often provide significant information for the identification and diagnosis of systemic diseases. Although, biochemical and histological examinations are also necessary but radiographic diagnosis is significant. With the present widespread use of the dental roentgenogram has come an increased opportunity to observe abnormalities of the teeth and their supporting structures which are attributable to systemic disease. As a result, there have been increased understanding and knowledge as to both the recognition and significance of these abnormalities.

Hence the dental care professionals should be aware that a dental abnormality could be the first radiographic evidence of a previously undiagnosed systemic condition, the early recognition and treatment of which may modify the course or reduce the severity of the underlying disease and thus render a profound service to the patient.

**References**

1. Jones JH and Mason DK. Oral Manifestation of Systemic Diseases. London: W B Saunders Company; 1980.
2. White SC, Pharoah MJ. Oral radiology .6th ed. New Delhi: Elsevier; 2009.
3. Neyaz Z, Gadodia A, Gamanagatti S, Mukhopadhyay S. Radiographical approach to jaw lesions. Singapore *Med J* 2008;49(2):165-177.
4. Stafnes EC. Oral radiographic diagnosis. 5<sup>th</sup> ed. USA: W B Saunders Company; 1985.
5. Zegarelli EV, Kutcher AH and Hyman GA. Diagnosis of diseases of the mouth and jaws. 2<sup>nd</sup> ed Philadelphia USA.
6. Worth HM. Principles and Practice of Oral Radiographic Interpretation. Chicago:Year Book;1963; p 344-345,354-365.
7. Edler RJ. Dental and Skeletal Ages in Hypopituitary Patients. *J Dent Res* 1977; 56; 1145-1153.
8. Langlais RP, Langland OE and Nortje CJ. Diagnostic imaging of the jaws. 1<sup>st</sup>ed.USA:Waverly Company;1995: p 459-466.
9. Aldred MJ et al. Dental findings in a family with hyperparathyroidismjaw tumor syndrome and a novel HRPT2 gene mutation. *Oral Surg Oral Med Oral Pathol Oral Radiol Endod* 2006; 101:212-8.
10. Sembulingam K and Sembulingam P. Essentials of medical physiology.4<sup>th</sup> ed. New Delhi: Jaypee; 2006: p 383-397.
11. Kelly A, Pomarico L and Ribeiro IP. Cessation of dental development in a child with idiopathic hypoparathyroidism: a 5-year follow up study. *Oral Surg Oral Med Oral Pathol Oral Radiol Endod* 2009; 107:673-677.
12. Ji-mei SU, Yun LI, Xiao-wei YE, Zhi-fang WU. Oral findings of hypophosphatemic vitamin D-resistant rickets: report of two cases. *Chinese medical journal* 2007;120:1468-1470.
13. Batra P, Tejani Z, Mars M. X-Linked Hypophosphatemia: Dental and Histologic Findings. *J Can Dent Assoc* 2006; 72(1):69-72.
14. Shafer, Hine, Levy. Oral pathology. 6th edn. New Delhi: Saunders; 2009: p 698-701, 760-763.
15. Olsson A, Matsson L, Blomquist HK, Larsson A, Sjödin B. Hypophosphatasia affecting the permanent dentition. *J Oral Pathol Med.* 1996 Jul;25(6):343-7.
16. Greenberg MS, Glick M, Ship JA. Burkets. Oral medicine.11<sup>th</sup> Ed. New Delhi: CBS; 2008: p 372-375.
17. Stark Z and Savarirayan R. Osteopetrosis: *Orphanet Journal of Rare Diseases* 2009;45:1172-1186.
18. White SC, Cohen JM and Mourshed FM. Digital analysis of trabecular pattern in jaws of patients with sickle cell anemia. *Dentomaxillofacial Radiology* 2000;29:119 - 124.
19. Karjodkar FR. Textbook of Dental and Maxillofacial Radiology. 2<sup>nd</sup> ed. New Delhi: Jaypee; 2009: p 694- 697.
20. Agarwal MB, Mehta BC. Genotypic analysis of symptomatic thalassemia syndromes (A study of 292 unrelated cases from Bombay). *JPGM* 1982;28(1):1-3.
21. Hazza AM and Jamal GAL. Radiographic features of the jaws and teeth in thalassaemia major. *Dentomaxillofacial Radiology.* 2006;35:283-288.

- 
22. Auluck A, Pai KM, Shetty C, Shenoi SD. Mandibular resorption in progressive systemic sclerosis: a report of three cases. *Dentomaxillofac Radiol* 2005;34:384–386.
  23. Auluck A. Widening of periodontal ligament space and mandibular resorption in patients with systemic sclerosis. *Dentomaxillofac Radiol* 2007;36:441–442.
  24. Mehra A. Periodontal space widening in patients with systemic sclerosis: a probable explanation *Dentomaxillofac Radiology* 2008;37:183-185.
  25. Wood NK and Goaz PW. Differential diagnosis of Oral and Maxillofacial lesions. 5<sup>th</sup> ed. New Delhi: Elsevier;2006: p 392-413.