

Diagnostic criteria and management of trigeminal neuralgia: A review

Rahul Srivastava^{1*}, Bhuvan Jyoti², Ashutosh Shukla³, Pankaj Priyadarshi⁴

¹Senior Lecturer, Department of Oral Medicine & Radiology, Rama Dental College, Hospital & Research Centre Kanpur (U.P), India

²Dental Surgeon, Department of Dental Surgery, Ranchi Institute of Neuro-Psychiatry and Allied Sciences, India

³Senior Lecturer, Department of Oral & Maxillofacial surgery Rama Dental College, Hospital & Research Centre Kanpur (U.P)

⁴Post Graduate student, Department of Conservative and Endodontics, Rama Dental College, Hospital & Research Centre Kanpur (U.P)

ABSTRACT

Trigeminal neuralgia, often called tic douloureux, has been described as one of the worst painful human afflictions. It is a craniofacial pain disorder that is characterized by episodes of sharp, severe, lancinating, “electric - like” bolts of pain. Pain of trigeminal neuralgia has been compared to severe toothache or even labor pain. The International Association for the Study of Pain defines classical idiopathic trigeminal neuralgia (TN) as “a sudden, usually unilateral, severe, brief, stabbing, recurrent pain in the distribution of one or more branches of the fifth cranial nerve.” However, there are variations in presentation that are more difficult to diagnose trigeminal neuralgia. The purpose of this article is to review the recent developments, new criteria for diagnosis, medical and surgical management. The review article has been prepared doing a literature review from the World Wide Web and pubmed/medline.

Keywords: Trigeminal neuralgia,cranial,fifth

Introduction

The trigeminal nerve (the fifth cranial nerve, also called the fifth nerve, or simply CNV or CN5) is responsible for sensation in the face. The trigeminal nerve is the largest of the cranial nerves and it is thought to be one of the factors involved in the cause of migraine. Its name - “trigeminal” - is derived from the fact that each nerve, one on each side of the pons, has three major branches: the ophthalmic nerve (V1), the maxillary nerve (V2) and the mandibular nerve (V3). The ophthalmic and maxillary nerves are purely sensory. The mandibular nerve has both sensory and motor functions.[1] Pain, thermal, tactile and kinaesthetic sensory stimuli are received from facial skin, oropharynx, oral mucous membranes, sinuses, teeth, palate, dura and masticatory muscles.

*Correspondence

Dr. Rahul Srivastava

Senior Lecturer, Department of Oral Medicine & Radiology, Rama Dental College, Hospital & Research Centre Kanpur (U.P), India

Email: dr Rahul_osmf@yahoo.com

Motor fibers extend to the muscles of mastication as well as the tensor tympani and tensor veli palatini. The trigeminal brain stem nuclei are the spinal trigeminal nucleus and tract, the main (or principal) sensory nucleus, the mesencephalic nucleus, and the motor trigeminal nucleus. The branches of trigeminal nerve have their cell bodies in the gasserian (or semilunar) ganglion (with the exception of jaw proprioceptive fibers). The gasserian ganglion resides in Meckel’s cave in the temporal bone.[2]There are various other health conditions that can cause facial pain, such as trigeminal neuralgia.[1]International Association For the Study of Pain (IASP) defined trigeminal neuralgia as “sudden usually unilateral severe brief stabbing recurrent pain in the distribution of one or more branches of the Vth cranial nerve”. According to the International Headache Society (IHS) the trigeminal neuralgia may be defined as “painful unilateral affliction of the face characterized by brief electric shock like pain limited to the distribution of one or more divisions of trigeminal nerve”. Pain is commonly evoked by trivial stimuli including washing, shaving, smoking, talking and brushing the teeth but may also occur spontaneously. The pain is abrupt in onset and termination and may remit for varying periods.[3]

Historical perspectives of TGN

Historical reviews of facial pain have attempted to describe this severe pain over the past 2.5 millennia. The ancient Greek physicians Hippocrates, Aretaeus, and Galen, described cephalalgias, but their accounts were vague and did not clearly correspond with what we now term trigeminal neuralgia. The first adequate description of trigeminal neuralgia was given in 1671 by German physician, Johannes Laurentius Bausch, who suffered from a lightning like pain in the right face. He became unable to speak or eat properly and apparently succumbed to malnutrition. John Locke, a physician and well-known philosopher, provided the first full description of TN by a medical practitioner, along with an account of its treatment. In 1677, while in Paris, Locke was called in to evaluate the wife of the English ambassador, the Countess of Northumberland, who was suffering from excruciating pain in the face and lower jaw. Locke deliberated whether to prescribe "opening medicine" (laxative therapy), because of the wintry weather at the time. In spite of the cold and the inconvenience he would cause his patient, he eventually overcame his reluctance and thoroughly purged the Countess. Her pain improved several weeks later. Nearly a century after that, two prominent clinical accounts were reported, one by Nicolas André (Fig. 1) and one by John Fothergill (Fig. 2) that further characterized this disease's entity. In 1756, André reported two cases of TN, which he termed *tic douloureux*. He conceptualized the disease in terms of convulsions, and he believed that true tonic convulsions, tetanus, and spasm clinique belonged in a

single disease spectrum. The term *tic douloureux* was used to imply contortions and grimaces accompanied by violent and unbearable pain. André believed that the cause was "vicious nervous liquids" that distressed the nerve and caused painful shocks. Using this reasoning, he followed the proposal of Maréchal (a contemporary surgeon) by applying caustic substances to the infraorbital nerve at the infraorbital foramen over a period of days until the nerve was destroyed. Fothergill described trigeminal neuralgia as "a painful affection of the face". He presented 14 cases of a painful affliction of the face. His description of TN has been considered an accurate and clear account. In Fothergill's description he made the following comments: "The affection seems to be peculiar to persons advancing in years, and to women more than to men....". The pain comes suddenly and is excruciating; it lasts but a short time, perhaps a quarter or half a minute, and then goes off; it returns at irregular intervals, sometimes in half an hour, sometimes there are two or three repetitions in a few minutes. Eating will bring it on some persons. Talking, or the least motion of the muscles of the face affects others; the gentlest touch of a hand or a handkerchief will sometimes bring on the pain, whilst a strong pressure on the part has no effect. Fothergill asserted that TN was not within the spectrum of a convulsive disorder. Instead, he postulated that this disease might be the manifestation of some type of cancer; he found a hard tumor of the breast in two of the 14 cases he presented. Given his meticulous description of the clinical symptoms, many thereafter referred to this condition as "Fothergill's disease."



Fig 1: Portrait of Nicolas Andre



Fig 2: Portrait of John Fothergill

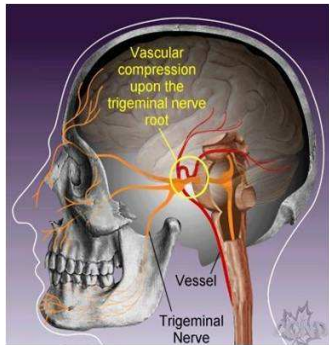


Fig 3: Patient with typical trigeminal neuralgia, vessels compress the trigeminal nerve root.

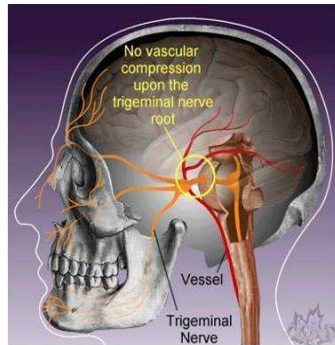


Fig 4: No vascular compression upon the trigeminal nerve root in patient with no TN

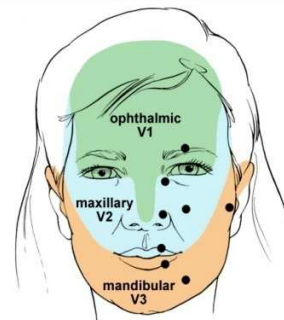


Fig 5: Trigger zones in facial areas, trigger points (circles) have greatest sensitivity

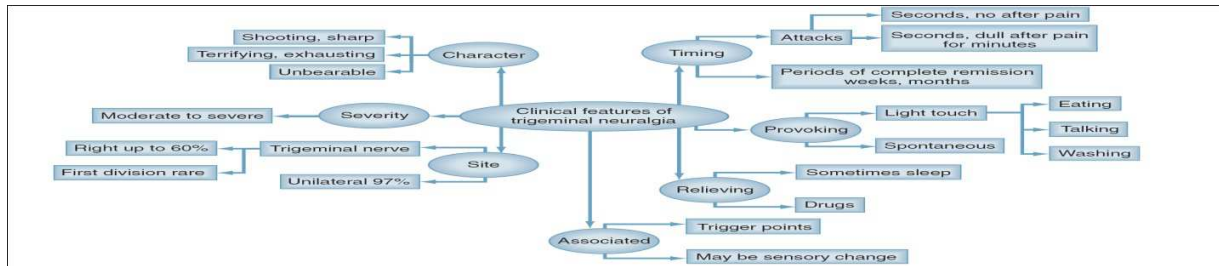


Fig 6: Important clinical features of trigeminal neuralgia

In 1779, John Hunter more clearly characterized the entity as a form of "nervous disorder" with reference to pain of the teeth, gums, or tongue where the disease "does not reside." One hundred fifty years later, the neurological surgeon Walter Dandy equated neurovascular compression of the trigeminal nerve with trigeminal neuralgia.[4-6]

Etiologic/predisposing factors

Trigeminal nerve is the largest of all the cranial nerves. Trigeminal neuralgia, also called tic douloureux, causes extreme, sporadic, sudden burning or shock-like facial pain that lasts from few seconds to several minutes and can be physically and mentally incapacitating. Most cases are still referred to as idiopathic, although many are associated with vascular compression of the trigeminal nerve. According to the National Institute of Neurological Disorders and Stroke, heredity may be a cause of trigeminal neuralgia.[7]

Compression of trigeminal nerve root is the most common cause of trigeminal neuralgia. The compression occurs usually within few millimeters of

entering in to the pons. The primary demyelinating disorders can also lead to this condition. A few rare conditions that can cause trigeminal neuralgia are:

- Infiltration of nerve root (due to carcinomatous deposit within nerve root, gasserian ganglion and nerve)
- Small infarcts or angiomas in the pons or medulla.
- Infiltration of gasserian ganglion or the nerve by a tumour or amyloid.

Most widely accepted theory is that majority of cases of trigeminal neuralgia are caused by atherosclerotic blood vessel (usually the superior cerebellar artery) pressing on and grooving the root of trigeminal nerve. This pressure results in focal demyelination and hyperexcitability of nerve fibers, which will then fire in response to light touch, resulting in brief episodes of intense pain.[8]

Jannetta in 1967 first recognized the focal compression of trigeminal nerve root as a major etiological factor for the trigeminal neuralgia. Now it is considered as an important cause of trigeminal neuralgia in 80-90% of cases. The part of nerve root that commonly compressed is actually within CNS tissue. There are

following compressing lesions that can lead to TGN are:

- Vestibular schwannomas.
- Meningiomas.
- Epidermoid cyst etc.[8,9]

Primary demyelinating disorders

A well known complication of multiple sclerosis is TGN. The plaque of demyelination encompasses the root entry zone of trigeminal nerve in the pons. The compression of blood vessel may also contribute in the compression of root entry of trigeminal nerve in some patient with multiple sclerosis suffering from trigeminal neuralgia.[10-14]

Nondemyelinating lesions

Nakamura et al, Golby et al have reported some patients with trigeminal neuralgia who were suffering from angiomas and small infarcts within the brain stem.[15,16]

Familial trigeminal neuralgia

In 1979 Knuckey and Gubbay reported several individuals in three generations of family were suffering from trigeminal / glossopharyngeal neuralgia.[17]

Coffey et al reported a familial occurrence in Charcot-Marie-Tooth neuropathy. He described the patients from two different families with Charcot-Marie-Tooth disease and medically intractable trigeminal neuralgia. The patients were treated with percutaneous retrogasserian glycerol rhizolysis successfully.[18]

Diabetes

Neuralgia anywhere in the body including the trigeminal neuralgia can also cause by diabetes. Diabetes causes the damage of tiny arteries that provide circulation to the nerves which lead to nerve fibers malfunctions and sometimes nerve loss.

Infectious conditions

The trigeminal neuralgia can also manifest by infectious conditions cerebellopontine angle cysticercosis, pons abscess and cases of bacterial infections like Mycobacterium leprae, Secondary syphilis, Leptospirosis, Shigella etc.

Stress

According to Beth Israel Medical Center Department of Pain Medicine and Palliative Care the trigeminal

neuralgia can be caused by stress also. Stress leads to inflammation of blood vessel which can compress or irritate the trigeminal nerve. Patient having the trigeminal neuralgia with another cause, the severity of painful attacks can worsen by stress.[7]

Pre-trigeminal neuralgia

A typical initial manifestation that, in some patients, precedes the classic presentation of TN, was introduced by Symonds. He described a dull continuous, aching pain in the upper or lower jaw that later developed in to classic paroxysmal pain. This prodromal pain is termed as "pre-trigeminal neuralgia" by Mitchell. Similar prodromal sensations have also been reported in some cases of glossopharyngeal neuralgia. Descriptions of PTN have included pain that is mild to moderate in intensity, dull, aching, burning, throbbing, soreness of gums and toothache.[19,20]

Fromm GH et al reported 18 patients who subsequently developed typical trigeminal neuralgia experienced a prodromal pain termed "pre-trigeminal neuralgia." The prodromal pain was described as a toothache or sinusitis-like pain lasting up to several hours, sometimes triggered by jaw movements or by drinking hot or cold liquids. Typical trigeminal neuralgia develops a few days to 12 years later, and in all cases affected the same division of the trigeminal nerve. Six additional patients experiencing what appeared to be pre-trigeminal neuralgia became pain-free when taking carbamazepine or baclofen.[21]

Classification of trigeminal neuralgia

Based on etiology

The international headache society (IHS) has classified trigeminal neuralgia in to two categories according to etiology:

1. **Classical trigeminal neuralgia** – In classical trigeminal neuralgia there is no cause of the symptoms can be identified other than vascular compression.
2. **Symptomatic trigeminal neuralgia** - Symptomatic trigeminal neuralgia has the same clinical criteria, but another underlying cause is responsible for the symptoms.[22]

Based upon the specific objective and reproducible criteria a classification scheme for trigeminal neuralgia was proposed by Eller JL. The classification was based on information provided in the patient's history and incorporates seven diagnostic criteria, as follows:

1 and 2- Trigeminal neuralgia Types 1 and 2(TN1andTN2) refer to idiopathic, spontaneous facial pain that is predominantly episodic (as in TN1) or constant (as in TN2) as in nature.

3- Trigeminal neuropathic pain results from unintentional injury to the trigeminal nerve from trauma or surgery.

4- Trigeminal deafferentation pain results from intentional injury to the nerve by peripheral nerve ablation, gangliolysis or rhizotomy in attempt to treat either TN or other related facial pain.

5- Symptomatic TN results from multiple sclerosis.

6- Post-herpetic TN follows a cutaneous herpes zoster outbreak in the trigeminal distribution.

7- The category of atypical facial pain is reversed for facial pain secondary to somatoform pain disorder and requires psychological testing for diagnostic confirmation.

Based on symptoms

From symptomatic point of view the trigeminal neuralgia is classified in to following:

1-Typical Trigeminal Neuralgia (Tic Douloureux)

This is the most common form of TN, which has previously been termed Classical, Idiopathic and Essential TN. Nearly all cases of typical TN are caused by blood vessels compressing the trigeminal nerve root as it enters the brain stem. This neurovascular or microvascular compression at the trigeminal nerve root entry zone may be caused by arteries of veins, large or small, that may simply contact or indent the trigeminal nerve. (Fig 3) In people without TN, blood vessels are usually not in contact with the trigeminal nerve root entry zone. (Fig 4) Pulsation of vessels upon the trigeminal nerve root do not visibly damage the nerve. However, irritation from repeated pulsations may lead to changes of nerve function, and delivery of abnormal signals to the trigeminal nerve nucleus. Over time, this is thought to cause hyperactivity of the trigeminal nerve nucleus, resulting in the generation of TN pain. The superior cerebellar artery is the vessel most often responsible for neurovascular compression upon the trigeminal nerve root, although other arteries or veins may be the culprit vessels.

2 - Atypical trigeminal neuralgia

Atypical TN is characterized by a unilateral, prominent constant and severe aching, boring or burning pain superimposed upon otherwise typical TN symptoms. This should be differentiated from cases of typical TN that develop a minor aching or burning pain within the affected distribution of the trigeminal nerve. As in typical TN vascular compression, is thought to be the cause of many cases of atypical TN. Some authors also believe that atypical TN is due to vascular compression upon a specific part of the trigeminal nerve (the portio minor); while others theorize that atypical TN

represents a more severe form or progression of typical TN.[23] The disorder is sometimes broken down into type 1 and type 2. TN type 1 (TN1) is characterized by attacks of intense, stabbing pain affecting the mouth, cheek, nose, and/or other areas on one side of the face. TN type 2 (TN2) is characterized by less intense pain, but a constant dull aching or burning pain. Both types of pain can occur in the same individual, even at the same time. In some cases, the pain can be excruciating and incapacitating. TN1 develops due to a blood vessel pressing against the trigeminal nerve, but sometimes no underlying cause can be identified (idiopathic). TN2 can be idiopathic, due to compression of the trigeminal nerve, or can occur due to a known underlying cause such as a tumor or multiple sclerosis. There is no consensus or agreed upon classification system for TN. TN1 is also known as classical trigeminal neuralgia. TN2 was once known as atypical or symptomatic TN.[24]

Clinical presentaion

- Recurring episodes of intense, short-lived spasms of pain of the lower portion of the face and the jaw.
- In most cases, pain is limited to one side of the face (unilateral).
- The pain has been compared to a series of "electrical shocks" followed by a steady dull ache.
- The pain often starts and stops rapidly.
- Intense pain usually lessens rapidly (usually within several seconds), but the following dull aching pain may persist for as much as one to two minutes. For many individuals, pain is completely gone in between episodes. However, for some individuals, even some individuals with TN1, some degree of pain may persist.
- Some patients are sensitive in certain areas of face called trigger zone, which when touched cause an attack. These zones are usually near the nose, lips, eyes, ears or inside the mouth. (Fig. 5)
- Pain may be triggered by mild tactile stimuli including brushing one's teeth, washing one's face, shaving, drinking hot or cold drinks, chewing, talking, blowing one's nose, a cool breeze, or a light touch to the face.
- Some episodes may occur without an apparent trigger (spontaneously). Consequently, episodes can occur repeatedly throughout the day.
- Episodes rarely occur during sleep.
- Attacks typically stop for a period of time and then return.
- Over time, the pain tends to grow worse with fewer pain-free periods.

Major clinical features are summarized in Fig.6[24-27]

Diagnosis

The diagnostic criteria of the International Headache Society (IHS) (1988) are as follows:

- 1- Paroxysmal attacks of facial pain which last a few seconds to less than two minutes.
- 2- Pain has at least 4 of the following characteristics:
 - Distribution along one or more divisions of the trigeminal nerve.
 - Sudden, intense, sharp, superficial, stabbing or burning in quality.
 - Pain intensity is severe.
 - Precipitation from trigger areas, or by certain activities such as eating, talking, washing the teeth or cleaning the face.
 - Between paroxysms the patient is entirely asymptomatic.
- 3- Attacks are stereotyped in the individual patient.
- 4- No neurological deficit and exclusion of other causes.[28]

The IHS describes TN as unilateral disorder characterized by brief electric shock like pain, abrupt in onset and termination limited to the distribution of one or more division of the trigeminal nerve in the second edition. In the second edition the diagnostic criteria for classical trigeminal neuralgia are as follows:

- A- Paroxysmal attacks of pain lasting from fraction of a second to two minutes, affecting one or more division of trigeminal nerve and fulfilling criteria B&C.
- B. Pain has at least one of the following characteristics:
 - 1- Intense, sharp, superficial or stabbing.
 - 1- Precipitated from trigger area or by trigger factor.
- C- Attacks are stereotype in the individual patients.
- D- There is no clinically evident neurological defect.
- E- Not attributed to another disorder.

The IHS description states that between paroxysms the patient is usually asymptomatic, but a dull background pain may present in some longstanding cases and that many, possibly most, patient with this condition have compression of the trigeminal root by tortuous or aberrant vessels.[29]

The trigeminal neuralgia association, UK has given the following clues that point to a correct diagnosis of trigeminal neuralgia:

- 1- The degree of pain exceeds the evidence.
- 2- Painkillers do not kill the pain.
- 3- The pain cannot be pinned down to one specific tooth.[30]

The diagnosis of TN is purely clinical. Haematological investigations at regular intervals are important in patient on drug therapy. Radiologic investigations are

important. Secondary TN (e.g. multiple sclerosis, cysts, vascular pathologies etc.) can be rule out with help of MRI. Sensory testing is not done routinely, but quantitative sensory testing (QST) and evoked potentials may play an important role in differentiating between symptomatic and idiopathic TN.[27]Nurmikko and Edridge have proposed their own diagnostic criteria for the trigeminal neuralgia (Table:1)

Management of pain

Administration of anticonvulsant drug was first treatment of choice initially, but nowadays varieties of effective treatments are available in both forms pharmacological as well as surgery. Drugs used as pharmacological treatment for trigeminal neuralgia is summarized in Table 2.[33-36]

Surgical management

When trigeminal neuralgia cases become refractory then they are referred to a neurosurgeon with special interest and experience with trigeminal neuralgia. There are following surgical options for the treatment of trigeminal neuralgia:

1. Microvascular decompression

Target area in microvascular decompression lies at the nerve-pons junction. The posterior fossa approached through a suboccipital craniotomy. After aspiration of cerebrospinal fluid, the operator advances toward the nerve by gently retracting the superolateral margin of the cerebellum. The most common finding is a segment of the superior cerebellar artery compressing the nerve at the root entry zone. Anterior inferior cerebellar artery or the superior petrosal veins are the less frequent cause of the compression. After the arachnoid is dissected and the vessel freed, the operator places a piece of shredded Teflon left between the vessel and the nerve to separate them.[37]

2. Glycerol gangliolysis

The procedure can be done under local anesthesia in fully awake patients although mild sedation is usually used. The needle is inserted into the trigeminal cistern through the foramen ovale using similar trajectories as in radio-frequency lesioning and balloon compression. Needle positioning must be precise to ensure the tip lies in ganglion and not the subarachnoid space beneath the temporal lobe. Free CSF flow is the norm, except in previously treated cases. Fluoroscopic control is mandatory but use of radio opaque contrast to visualise the cistern varies from centre –to- centre. Once needle is optimally placed, the patient is brought in to a sitting position and a small test of sterile anhydrous glycerol injected. This is followed by small dose increments up to a total of 0.1-0.4 ml depending upon the divisions involved. Patient is usually able to perceive the effect

of injection as tingling or burning sensation in the affected divisions. Patient remains in the sitting position for 2 hour after injections.

3. Radiofrequency gangliolysis

This procedure is carried out under fluoroscopic control in intermittently anaesthetized patient. A radiofrequency needle is inserted through the foramen ovale into Meckel's cave using bony landmarks. The relationship of trigeminal rootlets to the foramen ovale is such that by stepwise advancement of the needle the third, second and first divisions will be in succession stimulated, the closer to the clival line the needle tip is. As soon as the needle has entered Meckel's cave, aspiration will usually yield CSF. Once the needle has travelled the pre-planned distance, the patient is allowed to awake, the stylet replaced by the electrode and stimulation of the nerve root carried out. The paraesthesia elicited must confirm to the location of the neuralgia, otherwise the needle must be repositioned. Once appropriate siting has taken place, the patient is anaesthetized again for thermal lesioning. This is performed in cycles of 45 to 90 s at temperatures of 60-90⁰. After each lesioning the patient is awakened and manual sensory testing of the face carried out. Additional thermal lesions are performed until clear hypalgesia has ensued.[31]

Balloon compression

This procedure is performed under general anesthesia. Using fluoroscopic control, a guide needle is inserted in to foramen ovale, but not beyond it. Through the needle, the fogarty catheter is advanced until its tip lies in Meckel's cave and balloon is slowly inflated with 0.5 – 1.0 ml of contrast dye until it occupies the cave, ensuring adequate compression. Total compression times vary from 1-6 min. This produces only a mild sensory loss with immediate pain relief in practically all patients. There is complete recovery in a matter of weeks. The patient usually only requires an overnight stay.[31]

Stereotactic radiosurgery

Several reports have documented the efficacy of Gamma Knife® stereotactic radiosurgery for TN. Because radiosurgery is the least invasive procedure for TN, it is a good treatment option for patients with co-morbidities, high-risk medical illness, or pain refractory to prior surgical procedures. Radiosurgery is a good alternative for most patients with medically refractory trigeminal neuralgia, especially those who do not want to accept the greater risk of an MVD for a greater chance of pain relief[32].

Gamma Knife treatment is a simple, relatively painless and quite straight-forward process that consists of four steps:

1. Attaching the head frame;
2. Imaging with MRI or CT scan (for patients with pacemakers)
3. Treatment planning
4. Treatment

The head frame

Placement of the frame on the head of the patient is a very important part of the procedure. This frame allows the doctor to pinpoint the target area with extremely high accuracy. For trigeminal neuralgia patients, the target is usually in the vicinity of the root entry zone of the fifth cranial nerve.

Imaging

During this part of the procedure, most patients are awake and alert; however, patients who experience anxiety about the MRI or CT scan can be given further sedation so that the imaging can be carried out.

Treatment planning

During treatment planning, data from the images is transferred to a special, highly sophisticated computer. Unlike gamma knife treatment for brain tumors in which the tumor is outlined, trigeminal neuralgia patients will have the nerve outlined in multiple imaging sequences. Neurosurgeon and the rest of the team will go through a quality assurance process and everyone will review and confirm the plan before embarking on the actual treatment.

Treatment

Patient will then be taken to the actual Gamma Knife Suite where patient will be allowed to lie down in a comfortable position. The head frame is now attached to the automatic position system (APS). This is a very sophisticated computerized robotic system with high accuracy. At this point, patient may move his arms and legs, but head will actually be fixed. All of this will be explained by the nurses and doctors once inside the unit.[38,39]

Cyber knife in trigeminal neuralgia

Because of the intrinsic limitations of current stereotactic radiosurgical devices, image-guided robotic radiosurgery was developed, and these principles are embodied in the CyberKnife® System. For patients who had undergone balloon nerve compression, glycerol rhizotomy, or percutaneous thermorhizotomy, one complication is facial paresthesia and/or numbness of varying magnitude. This adverse effect may result from injury of the trigeminal nerve, causing impairment of sensory nerve

transmission. In a recent Stanford CyberKnife radiosurgery study, no patient with prior surgery developed facial paresthesia following radiosurgery treatment. The reduced rate of facial sensory disturbance indicates that the effects of radiosurgery are both physiologic and histologic due to lesser irritation on nerve tissue than other ablative surgeries. Cyber Knife technology allows conformal treatment along the nerve and permits highly collimator radiation beams near the dorsal root entry zone.

Conclusion

Trigeminal neuralgia has an enormous psychological effect that can affect the quality and lifestyle of a person. A definitive diagnosis of trigeminal neuralgia is one of the greatest problems among clinician and patients. Trigeminal neuralgia is a rare condition and clinician may only see a few cases in their dental practice career. Diagnosis of trigeminal neuralgia is made clinically with the help of characteristic signs and symptoms. Certain imaging modalities such as MRI can be used to rule out the underlying cause of trigeminal neuralgia including tumour and multiple sclerosis. A clinician must be aware of proper diagnosis and management of this type of craniofacial pain disorder.

References

1. Migraine and the trigeminal nerve. Migraine Action, Leicester [Internet].2010 [cited on 2015 Feb 19]. Available from: <http://www.nhs.uk/ipgmedia/national/migraine%20action/assets/migraineandthetrigeminalnerve.pdf>
2. Prasad S, Galetta S. The Trigeminal Nerve. Neuroanatomical localization and syndromes. In: Goetz C, Editor. Textbook of Clinical Neurology. 3rd Ed. Philadelphia. WB Saunders; c2007. pp 165-83.
3. Agrawal A, Cincu R, Borle RM, Bholra N. Trigeminal Neuralgia : An Overview. J MGIMS.2008; 13 (1):40-4.
4. Eboli P , Stone JL, Aydin S, Slavin KV. Historical characterization of trigeminal neuralgia. Neurosurgery. 2009; 64(6):1183-6.
5. Pearce JM. Trigeminal neuralgia (Fothergill's disease) in the 17th and 18th centuries. J Neurol Neurosurg Psychiatry. 2003; 74 (12):1688.
6. Cole CD, Liu JK, Apfelbaum RI. Historical Perspectives on the Diagnosis and Treatment of Trigeminal Neuralgia. Neurosurg Focus. 2005 May 15;18(5):E4.
7. Popovici F, Mergeani A, Popescu D, Antochi F. Review on the causes of trigeminal neuralgia symptomatic to other diseases. Rom J Neurol. 2011; 10(2):69-72.
8. Blasberg B, Greenberg MS. Orofacial Pain. In: Greenberg MS, Glick M, editors. Burket's Oral medicine diagnosis and treatment.10th edition. Hamilton, Ontario. BC Decker Inc; 2003.
9. Jannetta PJ. Arterial compression of the trigeminal nerve at the pons in patients with trigeminal neuralgia. J Neurosurg.1967; 26(1):159-62.
10. Moulin DE. Pain in central and peripheral demyelinating disorders. Neurol Clin. 1998; 16(4):889-98.
11. Soustiel JF, Hafner H, Chistyakov AV, Yarnitzky D, Sharf B, Guilburd JN, Feinsod M. Brain stem trigeminal and auditory evoked potentials in multiple sclerosis: physiological insights. Electroencephalogr Clin Neurophysiol. 1996; 100(2):152-7.
12. Lazar ML, Kirkpatrick JB. Trigeminal neuralgia and multiple sclerosis: demonstration of the plaque in an operative case. Neurosurgery. 1979; 5(6): 711-7.
13. Crooks DA, Miles JB. Trigeminal neuralgia due to vascular compression in multiple sclerosis—post-mortem findings. Br J Neurosurg. 1996; 10: 85-8.
14. Gass A, Kitchen N, MacManus DG, Moseley IF, Hennerici MG, Miller DH. Trigeminal neuralgia in patients with multiple sclerosis: lesion localization with magnetic resonance imaging. Neurology.1997; 49: 1142-44
15. Nakamura K, Yamamoto T, Yamashita M. Small medullary infarction presenting as painful trigeminal sensory neuropathy. J Neurol Neurosurg Psychiatry. 1996; 61: 138.
16. Golby AJ, Norbash A, Silverberg GD. Trigeminal neuralgia resulting from infarction of the root entry zone of the trigeminal nerve: case report. Neurosurgery. 1998; 43: 620-2.
17. Knuckey NW, Gubbay SS. Familial trigeminal and glossopharyngeal neuralgia. Clin Exp Neurol. 1979; 16: 315-9.
18. Coffey RJ, Fromm GH. Familial trigeminal neuralgia and Charcot-Marie-Tooth neuropathy. Report of two families and review. Surg Neurol. 1991; 35: 49-53.
19. Symonds C. Facial pain. Ann R Coll Surg Engl. 1949; 4:206-12.
20. Mitchell RG. Pre-trigeminal neuralgia. Br Dent J. 1980; 149:167-70.
21. Fromm GH, Graff-Radford SB, Terrence CF, Sweet WH. Pre-trigeminal neuralgia. Neurology. 1990; 40:1493-5.
22. Krafft RM. Trigeminal neuralgia. Am Fam Physician. 2008; 77(9):1291-6.
23. Kaufmann AM, Patel M. Characteristics and causes of trigeminal neuralgia. Winnipeg (Manitoba): Centre for Cranial Disorders [Internet]. 2001 [cited on 2015 Feb 21]. Available from: http://www.umanitoba.ca/cranial_nerves/trigeminal_neuralgia/manuscript/types.html
24. Cohen J. Trigeminal Neuralgia. Danbury (CT): The National Organization for Rare Disorders [Internet]. 2014 [cited on 2015 Feb 21]. Available from: <http://www.rarediseases.org/rare-disease-information/rare-diseases/byID/273/printFullReport>

25. Santos MM, Freire AR, Rossi AC, Prado FB, Caria PHF, Botacin PR. Trigeminal neuralgia: literature review. *J. Morphol. Sci.*, 2013; 30(1):1-5.
26. Tew J, McMohan N. Trigeminal neuralgia. Mayfield Certified Health Info. Mayfield Clinic and Spine Institute; 2013. pp 1-5.
27. Mathews MS, Binder DK, Linskey ME. Trigeminal Neuralgia: Diagnosis and Nonoperative Management [Internet]. Winn; 2010. Chapter 163 [cited on 2015 Feb 21]. Available from: http://www.bestcenteroc.com/files/5013/0800/5095/Trigeminal_neuralgia.pdf
28. Joffroy A, Levivier M, Massager N. Trigeminal neuralgia Pathophysiology and treatment. *Acta neurol. belg.* 2001; 101:20-5.
29. Toda K. Trigeminal neuralgia – symptoms, diagnosis, classification and related disorders. *Oral Sci Int.* 2007; 4(1):1-9.
30. Abbot J, Zakrzewska J. Would you recognise trigeminal neuralgia? Oxted (Surrey):Trigeminal neuralgia association UK; 2012.pp1-3.
31. Nurmikko TJ, Eldridge PR. Trigeminal Neuralgia-pathophysiology, diagnosis and current treatment. *Br J Anaesth.* 2001; 87(1):117-32.
32. Hasan S, Khan NI, Sherwani OA, Bhatt V, Asif S. Trigeminal neuralgia: An overview of literature with emphasis on medical management. *I Res J Pharm.* 2012; 3(11):235-8.
33. Green MW, Selman JE. Review article: the medical management of trigeminal neuralgia. *Headache.* 1991; 31(9):588-92.
34. Clark GT. Top 60 most important medications used in an orofacial pain treatment center. In: Clark GT, Dianne RA, editors. *Orofacial Pain.* West Sussex. Wiley Blackwell; 2012.
35. Levetiracetam (Keppra). Thomson Micromedex [Internet]. 2007 [cited on 2015 Feb 20]. Available from: http://www.hopkinsmedicine.org/neurology_neurosurgery/centers_clinics/peripheral_nerve/patient_info/LEVETIRACETAM_2007.pdf
36. George M, Selvarajan S, Indumathi C. Drug therapy for trigeminal neuralgia. *e-Journal of Dentistry.* 2011; 1(2):28-31
37. Rhoton AL Jr. The cerebellopontine angle and posterior fossa cranial nerves by retrosigmoid approach. *Neurosurgery.* 2000; 47(3 Suppl):S93-129
38. Sahni KS. A Patient's Guide to Understanding of TN. Trigeminal neuralgia treatment center of Virginia [Internet].2006[cited on 2015 Feb 20]. Available from: <http://www.neurosurgicalva.com/pdf/trigeminal-glycerol.pdf>
39. Adler JR Jr , Pham CJ, Chang SD, Rodas RA. Image-guided Robotic Radiosurgery: The CyberKnife. *Perspective in Neuroscience.* Bloomington(IL): Central Illinois Neuroscience Foundation; 2003 Nov.

Source of Support: NIL

Conflict of Interest: None

Table 1: Diagnostic criteria for the trigeminal neuralgia proposed by Nurmikko and Edridge

	Typical TGN(Liverpool criteria)	Atypical TGN(Liverpool criteria)	TGN(IASP and IHS definition)	Trigeminal neuropathy (Liverpool criteria)
Site	Unilateral	Unilateral	Unilateral	Unilateral or bilateral
Quality of pain	Sharp, shooting, stabbing, lingering aftersensations	Sharp, shooting, stabbing, lingering aftersensations, burning, smarting	Sharp, stabbing, burning, superficial	Dull or sharp, smarting, steady pain with shooting sensations superimposed.
Duration of pain	A few seconds at most	Several seconds	Brief	Any duration, usually hours
Duration of paroxysms	Seconds to minutes	Seconds to minutes	Seconds to two minutes	Continuous with pain-free spells.
Refractory period	yes	yes	yes	No
Continuous pain	No	Yes, not severe	No	Dominant feature

Allodynia	Small trigger zones.	Small trigger zones	Limited trigger zones	Large allodynic areas
Associated features	Vasodilation, swelling seen with severe pain	Vasodilation, swelling seen with severe pain.	Slight flush	Variable vasodilation and swelling, may be constantly present
Radiation	None outside affected division	None outside affected division	None outside affected division	May extend outside trigeminal territory
Provoking factors	Touching, speaking, eating, drinking, cold, not heat, movement	Touching, speaking, eating, drinking, cold, occasionally heat, movement	Eating, talking, washing face, brushing teeth and smoking.	Same as atypical TGN
Variability of pain	Some Variation	Definite variation	stereotyped	Definite variation
Sensory loss	Not detectable with bedside test QST may be abnormal	May be detectable with bedside tests QST usually abnormal	None	Prominent, easily detected with bedside tests confirmed by QST
Pain behaviour	Aversion to touch guarded speech	Aversion to touch guarded speech	Not discussed	Tolerates touching speech not affected
Course of pain	Early remissions pre- TGN	Early remissions previously typical TGN	Spontaneous remissions	No remission; slow progression

Table 2: Drugs used as pharmacological treatment for trigeminal neuralgia

Drugs	Mechanism of action	Dosage	Adverse effect
Carbamazepine	Slow the recovery rate of voltage – gated sodium channels, modulates activated calcium channel activity and activates descending inhibitory modulation system	200-1200 mg daily in 2 divided doses	Memory problems, diplopia, drowsiness, fatigue, nausea, nystagmus liver dysfunction, hematosupression
Baclofen	Act by facilitating segmental inhibition of the trigeminal complex.	Initial dose is 5mg TID for 3 days and dose may be increase d up to 10 to 20 mg/day every 3 days and maximum tolerated dose is 50 to 60 mg/day	Drowsiness, Dizziness, weakness, Fatigue and nausea
Oxcarbazepine	Act by blocking voltage-gated sodium channel and it modulates voltage activated Ca ⁺⁺ currents.	300 to 1800 mg daily in two divided doses	Dizziness, fatigue, ataxia, fatigue, tremors, diplopia, diminished concentration.
Phenytoin	Promotes sodium reflux from neurons.	300 to 500 mg/day	Nystagmus, ataxia, slurred speech, mental confusion
Lamotrigine	It acts as a voltage sensitive sodium	Starting dose is 25 mg	Ataxia, constipation,

	channel and stabilizes neural membranes.	twice daily and it can be increased gradually to a maintenance dose of 200-400mg/day in two divided doses.	vomiting and rash
Levetiracetam	mechanism of action is thought to involve binding to the high voltage N type calcium channels as well as the synaptic vesicle protein 2A (SV2A).	effective dose range is 1000 - 4000 mg/day	sleepiness, fatigue, weakness, headache, pain, double vision, dizziness, coordination difficulties, runny nose or cough, increased infections, memory difficulties, anxiety, and behavioral problems
Gabapentin	Mechanism of action is not known but possibly includes blockage of voltage – gated calcium channels by binding to $\alpha 2/\Delta$ subunit	1200 to 3600 mg daily in 3 or 4 divided doses	dizziness, coordination problems, nausea, vomiting
Pregabalin	drug binds to the $\alpha 2\delta$ subunit of the voltage gated calcium channels causing decreased presynaptic calcium entry leading to decreased synaptic release of glutamate.	150-600 mg/day	Ataxia
Topiramate	Acts by sodium channel blockade, enhancing GABA _A activity by binding to a non-benzodiazepine site on GABA _A receptors, and selectively blocking AMPA/kainite glutamate receptors.	50 to 100 mg a day	Dizziness, sedation, cognitive impairment, fatigue, nausea, blurred vision and weight loss.