

---

## Ewing's sarcoma / Primitive Neuroectodermal tumor of uterine cervix: a rare case report

N. Rastogi\*, A. Gupta, N. Soni, P. Mandawat, R.K. Singh, R. Tanwar

Department of Pathology, Government Medical College, Kota, Rajasthan, India

---

### ABSTRACT

Ewing's sarcoma, a round cell malignancy of bone and soft tissue occurs predominantly in adolescents and young adults. Extraosseous Ewing's sarcoma is extremely rare. As such cervical sarcomas constitute less than 1% of all cervical malignancies and out of this, only 4% constitute Ewing's sarcoma i.e. 0.04 % of all cervical sarcomas.[1]. Less than 20 cases of Ewing's sarcoma of cervix have been reported in the English literature and this is probably the 20 th case.[2]. Most of these cases presented with abnormal vaginal bleeding. The rarity and probability of misdiagnosing it as small cell carcinoma creates the need to report this case to add to the available literature. We report a case of probably youngest patient till date, aged 12 years female child diagnosed as Ewing's sarcoma on Fine needle aspiration cytology(FNAC), further confirmed by biopsy, Immunohistochemistry (IHC) and t(11,22) chromosomal translocation

**Keywords:** Ewing's sarcoma, PNET, uterine cervix, youngest patient

---

### Introduction

Ewing's sarcoma / PNET is a round cell malignancy of bone and soft tissue that occurs in adolescents and young adults displaying varying degrees of neuroectodermal differentiation. It is characterized by reciprocal translocation between chromosomes 11 and 22, t(11,22). PNET of the female genital tract is very unusual, the most common site being ovary with uterine corpus being the second most common. Primary PNET of the cervix and vulva are extremely rare.[3] Different primary sites have been reported including trunk, extremities, head & neck, retroperitoneum. [4]. We present a case of primary PNET tumor of the uterine cervix in 12 years female diagnosed initially on FNAC and later confirmed by biopsy, IHC and presence of t(11,22) translocation

### Case report

A 12 year old Indian female presented with complaints of abdominal pain, irregular vaginal bleeding. Clinical examination of vagina showed a mass arising from uterine cervix. Ultrasonography and CT scan showed a large heterogenous mass with increased vascularity involving lower uterine segment measuring 12x10x09 cm with normal upper uterine segment. Mass was indenting posterior urinary bladder wall, anterior rectal wall. Multiple enlarged lymph nodes (pre-paraortic, aortocaval, retrocaval, mesenteric, iliac, inguinal, obturator) were seen. Mass encased aorta, IVC, bifurcation, iliac vessels, bilateral lower ureters leading to moderate hydronephrosis and left obstructive nephropathy changes. S.Creatinine level was raised with other biochemical parameters unremarkable. USG guided FNAC was done from the uterine cervix mass. The smears revealed predominantly round cells with two cell population, one showing hyperchromatic nucleus, the other population of larger cells with open chromatin nucleus. Vacuolations were seen in cytoplasm and nucleus. Mitotic activity was increased, 3-4/HPF with presence of rosettes and necrosis in

---

\*Correspondence

**Dr.N Rastogi**

Department of Pathology, Government Medical College, Kota, Rajasthan, India

**E Mail:** [nupurkota123@gmail.com](mailto:nupurkota123@gmail.com)

background. Periodic Acid Schiff staining was positive in few cells. Cytomorphological diagnosis of round cell

tumor , Ewing’s sarcoma/ PNET was made.

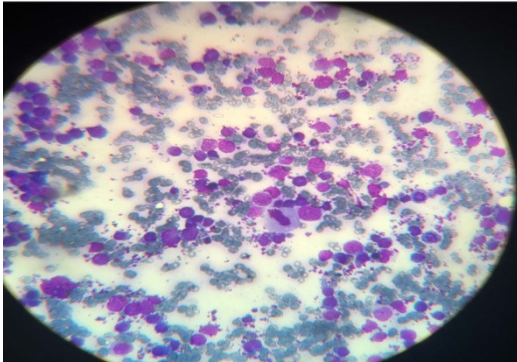


Fig 1:Cytology smears, 40x, MGG stain

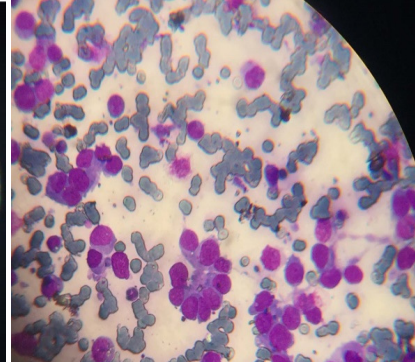


Fig 2:Cytology smears,rosette,40x,MGG

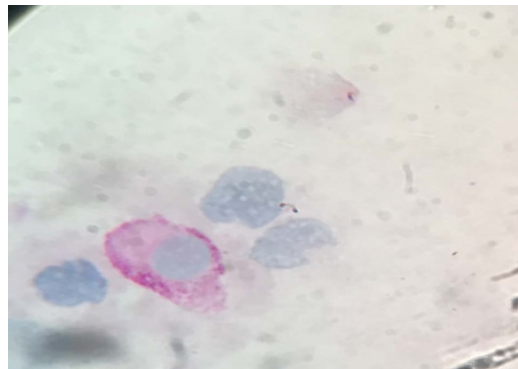


Fig 3: PAS positive stain on FNAC slide

Biopsy was done which showed round cells with salt and pepper chromatin , abundant necrosis in background. Histomorphological diagnosis of round cell tumor, Ewing’s sarcoma / PNET was confirmed. Further Immunohistochemistry markers were done which showed diffuse membranous positivity in viable cells for CD-99, synaptophysin- positive. LCA, CK, Myogenin, desmin were negative. Henceforth the diagnosis of Ewing’s sarcoma / PNET was established based on cytomorphology, histomorphology, Immunohistochemistry markers. Chromosomal study for translocation 11,22 was done which also showed presence of t(11,22) further establishing diagnosis of Ewing’s sarcoma.

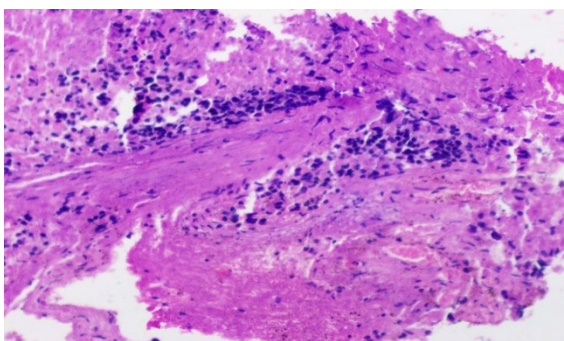


Fig 4: Histopathology slide, H & E stain,10x

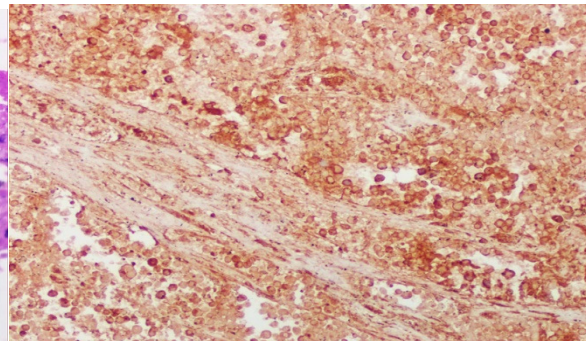
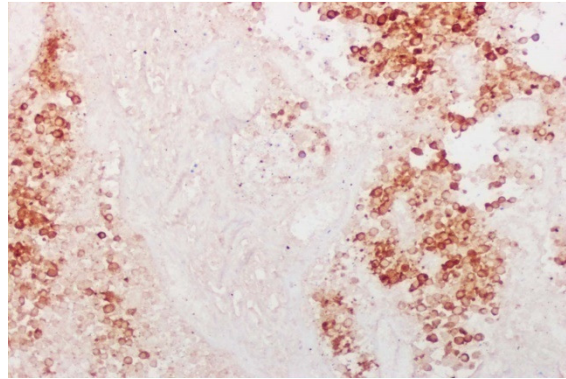


Fig 5: CD 99- diffuse membranous positivity



**Fig 6. Synaptophysin, positive**

### Discussion

Ewing's sarcoma / PNET of the uterine cervix is an extremely rare entity. Our review shows that there have been only 19 cases reported so far in the English literature, we report the 20 th case. The ages at presentation of previous cases ranged between 19 and 60 years, with the mean age being 39.[1]. This is the youngest case to be reported at 12 years age. This case is being reported for its rarity of presentation emphasizing the utility of FNAC in early diagnosis and thereby immunohistochemical staining in establishing the diagnosis of tumor at unusual sites.

### Conclusion

It is important to identify these rare cases of Ewing's sarcoma at unusual site with diagnosis on Fine needle aspiration cytology to provide early and appropriate treatment, as Ewing's sarcoma of cervix is potentially curable disease with induction chemotherapy followed

by radiation treatment and subsequent maintenance chemotherapy.

**Acknowledgements:** Patient and her relatives

### References

1. Oluwole Fadare, uncommon sarcomas of the uterine cervix: a review of selected entities, *Diagnostic pathology*, 2006;12
2. N. Mashriqii, J.K. Gujjarlapudi, J. Sidhu, M.Zur, M. Yalamanchili, Ewing's sarcoma of the cervix, a diagnostic dilemma: a case report and review of the literature, *Journal of Medical Case reports*, 2015,9:255.
3. P. Das, K. Gunaseelan, D. Basu, R. Anantha krishnan, K.S. Reddy, Case report: Primary vaginal .Ewing's sarcoma / primitive neuro ecto dermal tumor: diagnostic and treatment challenges, *J. Clin Sci Res* 2014 ; 3: 145-9
4. Z. Benbrahim, C. Haie-Meder, P. Duvillard, O. El Mesbahi, A. LeCesne, P. Pautier, primitive neuroectodermal tumor of the cervix uteri: A case report and review of literature, *IJHOSCR* 2012;6(4):12

**Source of Support:** Nil

**Conflict of Interest:** None