

## Thyroid ophthalmopathy in hashimotos thyroiditis with hypothyroidism- an unusual presentation

Vimala Sheshadri Iyengar<sup>1\*</sup>, Varun Gosain<sup>2</sup>, Karnalli Jagannatha<sup>3</sup>, Rampura Bommarayigowda Ramegowda<sup>4</sup>

<sup>1</sup> Associate Professor, Department of medicine, Adichunchanagiri Institute of Medical Sciences, Balagangadharanatha nagar, Mandya, Karnataka, India

<sup>2</sup> 2<sup>nd</sup> year resident, Department of Medicine, Adichunchanagiri Institute of Medical Sciences, Balagangadharanatha Nagar, Nagamangala, Mandya, Karnataka, India.

<sup>3</sup> Professor, Department of Medicine, Adichunchanagiri Institute of Medical Sciences, Balagangadharanatha Nagar, Nagamangala, Mandya, Karnataka, India

<sup>4</sup> Assistant Professor, Department of Medicine, Adichunchanagiri Institute of Medical Sciences, Balagangadharanatha Nagar, Nagamangala, Mandya, Karnataka, India

### ABSTRACT

Thyroid associated ophthalmopathy is an autoimmune disorder, most frequently encountered in hyperthyroid state, especially seen in Graves' disease and is rarely associated with hypothyroidism. A case of thyroid ophthalmopathy secondary to Hashimoto's thyroiditis in hypothyroid state is reported here.

**Keywords:** dysthyroidism, ophthalmopathy.

### Introduction

Thyroid ophthalmopathy is an autoimmune disorder characterized by enlargement of extra ocular muscles, increase in fatty and connective tissue volume in the orbit. It may precede, coincide or follow thyroid dysfunction. It is most frequently encountered in hyperthyroid state, especially seen in Graves' disease (80%). But it can also occur in hypothyroid (1%) or even in euthyroid state (6%) [1]. Treatment of thyroid dysfunction does not alter the course of ophthalmopathy. A case of thyroid ophthalmopathy secondary to Hashimoto's thyroiditis in hypothyroid state is reported here.

### Case report

A 35 year old male diagnosed with dengue fever was found to have bilateral proptosis (Figure 1).

There was no history suggestive of thyroid dysfunction and no ocular symptoms were present. On examination, he had bilateral exophthalmos, Mobius sign and mild thyromegaly were present. The proptosis was measured to be 23 mm in both eyes by using calipers. Systemic examination was unremarkable. Thyroid profile revealed a hypothyroid state (T3 –0.84 ng/ml, T4 – 5.43 microgram/dl., TSH – 14.73micro units/ml).

Thyroid scan showed mild enlargement of both lobes and isthmus. Heterogeneous echo structure and increased vascularity of bilateral lobes and isthmus was noted on Doppler study (Figure 2). Fine needle aspiration cytology of thyroid was suggestive of Hashimoto's thyroiditis (Figure 3). Orbital ultrasound (B scan) showed thickened medial rectus in the right eye and increased bilateral pad of fat. MRI orbit showed increased muscle belly of bilateral inferior and medial rectus sparing the tendons along with axial proptosis in both eyes. Schirmer's test was positive. Patient recovered from febrile illness completely. He was discharged with the advice of eye lubricants; thyroxine supplement and regular follow up.

\*Correspondence

**Dr. Vimala Sheshadri Iyengar**

Associate Professor, Department of medicine, Adichunchanagiri Institute of Medical Sciences, Balagangadharanatha Nagar, Mandya district, Karnataka, India. E Mail: [vimala.s.iyengar@gmail.com](mailto:vimala.s.iyengar@gmail.com)



Figure 1: Proptosis in the patient

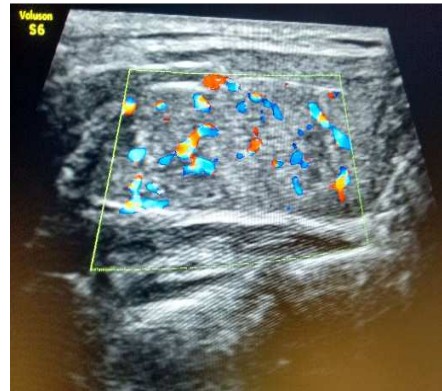

Figure 2: Thyroid scan and doppler showing thyromegaly and increased vascularity in the thyroid gland.

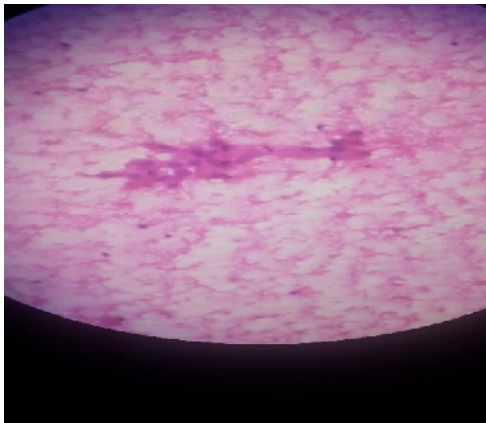


Figure 3: Fine needle aspiration cytology microphotograph showing Hurthle cell changes and infiltration of thyroid follicles with lymphocytes

### Discussion

Thyroid associated ophthalmopathy is an autoimmune disorder characterised by enlargement of extra ocular muscles, increase in fatty and connective tissue in the orbit. The circulating antigens against TSH cross react with antigen in orbit causing infiltration by T cells, release of cytokines and increase in mucopolysaccharides, collagen and orbital fat volume leading to proptosis which is usually bilateral. Our patient had bilateral proptosis. Thyroid ophthalmopathy is more common in females in the age group of 30 to 50 years of age. But in males it occurs in

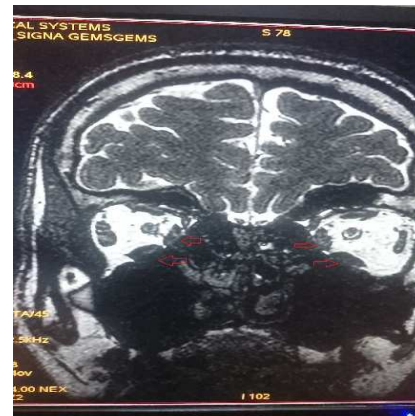


Figure 4: MRI skull and orbit showing hypertrophy of muscle belly of bilateral medial and inferior recti (sparing the tendons)

a severe form. Cigarette smoking is the strongest risk factor associated with thyroid ophthalmopathy [2]. Ocular manifestations include proptosis, lid retraction, chemosis and external ophthalmoplegia. Diplopia can be a troublesome symptom. Our patient had no ocular symptom. Orbital imaging (USG, CT and MRI) is a very useful diagnostic tool. The three important features are – 1. Enlargement of muscle belly sparing the tendons (coke bottle appearance). Extra ocular muscles are involved in a predictable fashion – inferior rectus, medial rectus, superior rectus and lateral rectus in that order. 2. Increase in orbital fat volume. 3. Crowding of optic nerve at the apex. Our patient had tendon sparing hypertrophy of bilateral medial and inferior recti. It is a self-limiting disorder resolving within 2-5 years without any treatment. The treatment options are 1-

Eye lubricants, taping and protective shields, tarsorrhaphy to prevent exposure keratitis. 2 –Systemic steroids. 3- Radiation. 4- Orbital decompression. Though self-limiting, it can lead to loss of vision due to exposure keratitis and optic nerve compression. Hence early recognition, prompt intervention and regular follow up are necessary.

#### Acknowledgement

Source of Support: Nil

Conflict of Interest: None

The patient consent was received for this case report to be published.

#### References

1. Bartley G.B. *et al.*, Clinical features of Graves' ophthalmopathy in an incidence cohort. American Journal of Ophthalmology 1996;121:284–290.
2. Maheshwari R, Weis E. Thyroid associated orbitopathy. Indian J Ophthalmol 2012;60:87-93.