
Primitive Neuroectodermal tumor / Ewing's sarcoma of the prostate in a young Indian adult – an extremely rare case report

N. Rastogi*, A. Gupta, R. K Tanwar, R. K. Singh

Department of Pathology, Government Medical College, Kota, Rajasthan, India

ABSTRACT

We present an extremely rare case of Primitive Neuroectodermal tumor (PNET) / Ewing's sarcoma of the prostate in a 40 years old Indian male who presented with pedal edema and dysuria. Ultrasonography was performed which showed a pelvic mass between urinary bladder and rectum. Fine Needle Aspiration Cytology diagnosis of a Malignant round cell tumor- PNET / Ewing's sarcoma was made, which was confirmed by Biopsy and Immunohistochemistry (IHC). The prognosis of PNET / Ewing's sarcoma of prostate is very poor since it is one of the most aggressive tumors and rare disease entity. To the best of our knowledge, this is the 10th case documented internationally and only second from Indian subcontinent.

Key words: Primitive Neuroectodermal tumor / Ewing's sarcoma, prostate, Indian adult male.

Introduction

Primitive Neuroectodermal tumor / Ewing's sarcoma is mainly a tumor of the soft tissue or bone in children and young adults, although it occurs in all ages [1]. PNET of visceral organs have now been described. These tumors have a predilection for bone and soft tissues in the paraspinal region and lower extremities. [2]. Osseous and extraosseous Ewing's sarcoma show the same chromosomal translocation t (11,22) (q24; q12) which allows the pathologists to identify immunohistochemically equivocal case. [3]. Various other translocation patterns may also be involved. [4]. PNET is divided into central PNET and peripheral PNET according to their location or origin. There are various symptoms in peripheral PNET which can occur in almost all areas of the body. A common feature of image findings of peripheral PNET is a large and infiltrative soft tissue mass with an ill defined, necrotic region and heterogenous enhancement. [5,6]. Cases of

PNET occurring in visceral sites such as brain, parotid gland, lung, kidney, urinary bladder, uterus, pancreas, testes, ureter, seminal vesicles, stomach, omentum, ovary and rarely prostate. PNET of the prostate which was also classified as peripheral PNET, was first reported in 2003. We report a case of 40 years old Indian male diagnosed on cytomorphology and confirmed by histomorphology and Immunohistochemistry.

Case report

A 40 years old Indian male patient presented with complaints of pedal edema and dysuria. Ultrasonography (USG) showed pelvic mass measuring 6.2 x 5.6 cm between the urinary bladder and rectum. USG guided Fine needle aspiration cytology was done, cytomorphology of which showed bimodal population of round cells having coarse chromatin nucleus and vacuolated cytoplasm in large cells. Rosettes formation was seen. Background showed stripped nuclei. Hence the cytomorphological diagnosis of Malignant Round cell tumor – PNET / Ewing's sarcoma was given. CT scan and MRI were done after an interval of 7 days from initial diagnosis, which showed enlarged prostate gland measuring 11.5 cm (transverse) x 9.8 cm (Anteroposterior) x 13.4 cm (supero-inferior), fairly defined, moderately enhancing, irregular shaped area

*Correspondence

Dr. N. Rastogi

Department of Pathology, Government Medical College, Kota, Rajasthan, India.

E Mail: nupurkota123@gmail.com

within the prostate. The residual prostatic gland were compressed to the periphery. No abdominal lymph nodes or invasion to adjacent organs was seen. No

lesions were seen in liver, kidney, lungs or any other organ. S. PSA level was 1.0 ng/dl.

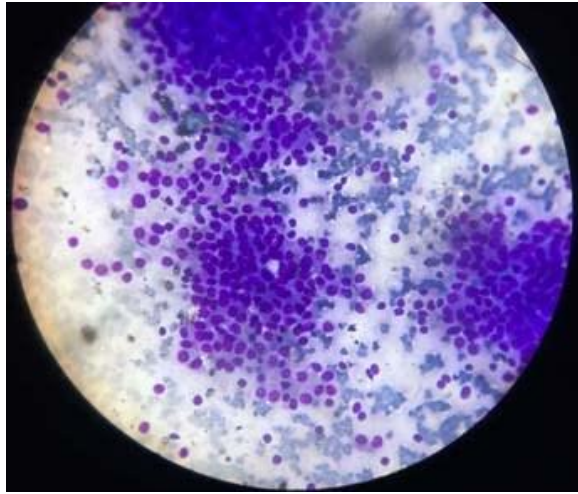


Fig 1: Cytosmear, MGG stain, 40 x

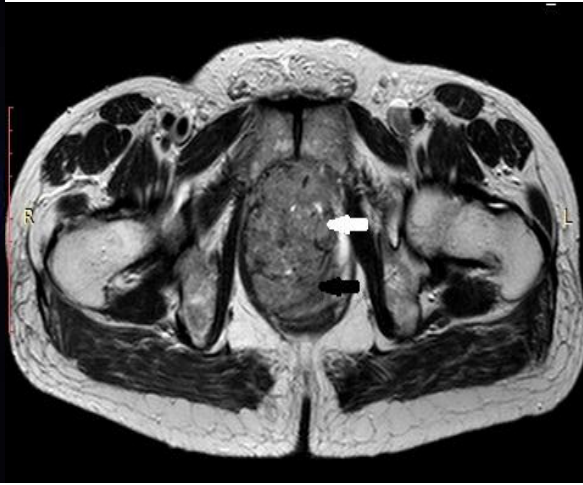


Fig 2: MRI-Lobulated heterogeneous masslesion [white arrow] which is hyperintense to muscle on T2 W image seems to be arising from prostate [black arrow].

Further, core needle biopsy using 16 G biopsy gun under Ultrasonography guidance was done. Histomorphology of the sections showed round, uniform cells with scant clear cytoplasm, indistinct cell membranes, round nuclei with indentations, and an occasional mitotic figure. Rosettes were present. Histomorphological diagnosis of Malignant round cell tumor- PNET / Ewing's sarcoma was thus made.

Immunohistochemistry marker for CD 99 showed Diffuse membranous positivity. IHC markers for Synaptophysin, Chromogranin, LCA (CD 45), and PSA were Negative. Hence on the basis of cytomorphology, histomorphology and IHC markers diagnosis of PNET / Ewing's Sarcoma of the prostate was confirmed.

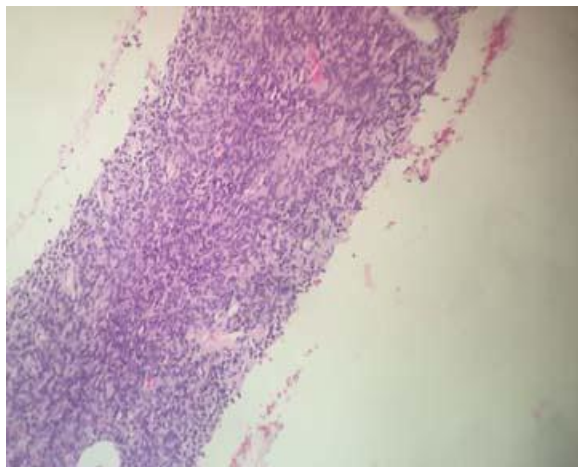


Fig3: Biopsy, H & E section, 10 X

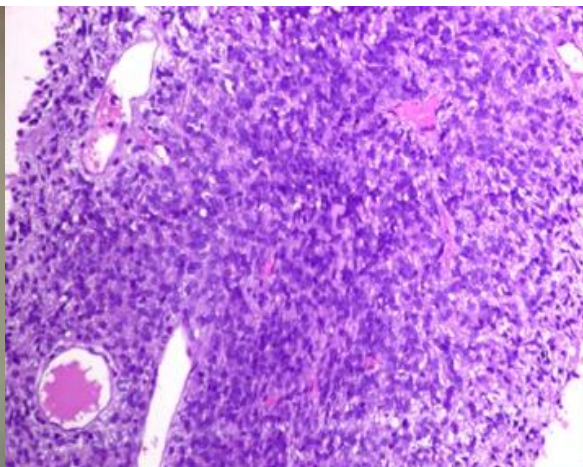


Fig 4: Biopsy, H & E section, 40 X

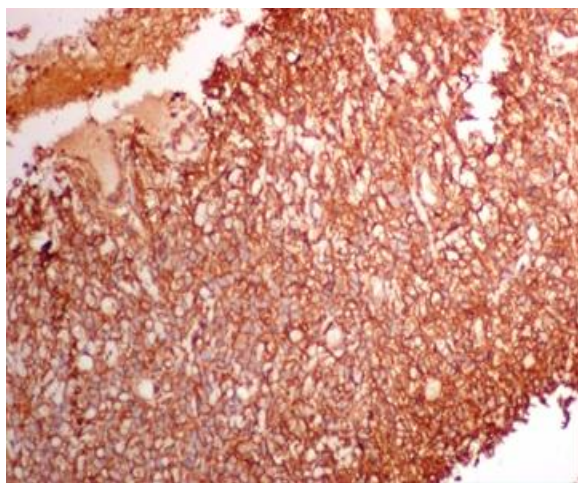


Fig 5: CD 99- Diffuse membranous positivity

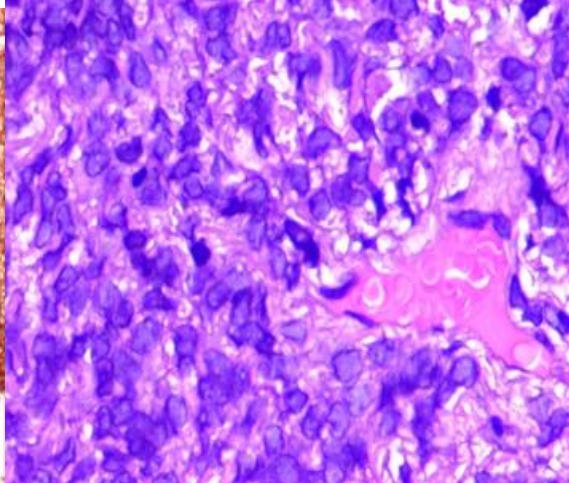


Fig 6: CD- 45, Negative

Discussion

PNET in the prostate is extremely rare, accounting for < 0.1 % of the primary prostate cancer types in adults. [7,8]. Common acinar prostatic adenocarcinoma accounts for 95 % of all malignant prostatic neoplasms. The diagnosis of PNET is based on cytological, histological examination. The main differential diagnosis considering the age of the patient and site of the tumor was Malignant Lymphoma which was easily ruled out due to negativity for CD 45. Strong diffuse membranous CD 99 positivity helped in establishing a diagnosis of primary PNET of the prostate. A multimodal therapeutic regimen that includes a combination of chemotherapy, surgery and radiotherapy is the current treatment strategy for the Ewing's sarcoma family of tumors. PNET is radiosensitive tumor. In the present case which is 10th in the series to be reported, the presentation was similar to all 9 cases reported earlier as PNET of the prostate gland. In all cases a large sized primary tumor replaced the prostate at the time of diagnosis. Despite the large size of the tumor in the pelvic area, the predominant complaint of the patient was the common symptom of dysuria. In all the 9 reported cases till date, patients were young adults (age range 20-31 years). Serum PSA was normal in all cases. Considering its rare occurrence the non specific imaging features of PNET , biopsy with IHC should be considered initially in case of delaying the illness, especially when there is a large retroperitoneal mass with aggressive characteristics.

Conclusion

PNET / Ewing's sarcoma of the prostate is extremely rare. The data in the literature are also very scarce.

PNET of the prostate gland should be considered when young male (20-40 years age) present to the hospital with the complaint of dysuria, to improve the rate of early diagnosis. FNAC helps in arriving at an early diagnosis with confirmation by histopathological examination and IHC. As the prognosis is poor, utmost attention must be made in differentiating the tumor from other round cell tumors and to the treatment. Summarising the case report , the present case of primary PNET of the prostate is 10th case in the series to be reported internationally and only 2nd from Indian subcontinent [9] in an Indian adult male patient aged 40 years.

Acknowledgements

Patient and her relatives.

References

1. V. Kumar, N. Khurana, et al. PNET of prostate, case report. Indian Journal of Pathology and Microbiology 2008;51(3):386-388
2. Dehner LP. Peripheral and central PNET: A nosologic concept seeking a consensus. Arch Pathol Lab Med 1986; 110:997-1005
3. Quezado M, Benjamin Dr, Tsokos M, EWS-FLI-1 fusion transcripts in three peripheral primitive neuroectodermal tumors of the kidney, HumPathol 1997;20:767-7
4. Balamuth NJ, women RB, Ewing's sarcoma, Lancet Oncol. 2010; 11:184-192.

5. Gupta P, Haris, Thulkar S. Imaging spectrum of peripheral primitive neuroendocrine tumors. *Singapore Med J.* 2013;54:463-472.
6. QAian X, Kai X, Shaodong L, Gaohong C, Hong M, Jingjing L. Radiological and clinic-pathological features of pPNET. *Eur J Radiol.* 2013;82:e888-e899
7. Bernard T, John RS, Bostwick DG: Soft tissue tumors. *Pathology of the Prostate*, Edited by: Bostwick GB. 1990, New York: Churchill Livingstone, 117-135
8. Paulussen M, Frohlich B, Jurgens H. Ewing's tumor: Incidence, prognosis and treatment options. *Paediatr Drugs* 2001; 3: 899-913
9. T. Shibuya, K Mori, et al. Rapidly progressive primitive neuroectodermal tumor of the prostate: A case report and review of the literature: *Oncology letters*, 2015,9(20): 634-636.

Source of Support: Nil

Conflict of Interest: None