

A study of titanium elastic nailing system in paediatric femur fractures

Ravindra S. Patil¹, Dhanish V. Mehendiratta², Nikhil V. Bothara³, Sahil Bhagat⁴, Keyur R Patel⁵,
Bajrang Singh⁶

¹Assistant Professor, Department of Orthopaedics, D.Y. Patil Medical College & Hospital, Kolhapur, Maharashtra, India.

²Junior Resident, Department of Orthopaedics, D.Y. Patil Medical College & Hospital, Kolhapur, Maharashtra, India.

³Junior Resident, Department of Orthopaedics, D.Y. Patil Medical College & Hospital, Kolhapur, Maharashtra, India.

⁴Junior Resident, Department of Orthopaedics, D.Y. Patil Medical College & Hospital, Kolhapur, Maharashtra, India.

⁵Junior Resident, Department of Orthopaedics, D.Y. Patil Medical College & Hospital, Kolhapur, Maharashtra, India.

⁶Junior Resident, Department of Orthopaedics, D.Y. Patil Medical College & Hospital, Kolhapur, Maharashtra, India.

ABSTRACT

Introduction: Treatment of fracture as such at all age groups has revolutionized today along with rapid development in bioengineering science. This has altogether changed the approach towards treatment of fractures keeping basic principles like stable, clinical and radiological union with rapid mobilization of adjacent joints. The newer techniques facilitate all these goals. In this study we have selected fracture shaft of femur in children aged between 5 to 15 years treated using multiple flexible titanium elastic nails. The aim is to study the morphology of diaphyseal fracture of femur in paediatric age group and to assess the outcome/results and complications of treatment of these fractures using titanium elastic nail fixation. **Material and methods:** The method used for fracture fixation was closed reduction & internal fixation using Titanium Elastic Nailing System. Femur was the involved bone under study. **Observation and results:** In this study 35 patients with fracture shaft femur aged between 5 to 15 years were treated with Titanium Elastic Nailing System. **Conclusion:** We recommend that elastic stable Titanium Elastic Nailing System may be a good choice for the treatment of femoral shaft fractures in skeletally immature patients in need of surgical stabilization. Titanium Elastic Nailing System is a minimally invasive technique requiring a small incision, leading to good callus formation, early mobilization, and full recovery of function with minimal complications.

Key words: Femur, fracture, titanium, nailing

Introduction

Treatment of fracture as such at all age groups has revolutionized today along with rapid development in bioengineering science. This has altogether changed the approach towards treatment of fractures keeping basic principles like stable, clinical and radiological

union with rapid mobilization of adjacent joints. The newer techniques facilitate all these goals. Fractures of the shaft of femur are one of the difficult fractures in children. Although, femur is the strongest bone in body, the bones in children have following peculiarities:

- In early childhood, the femur is relatively weak and breaks under load conditions reached in normal play.
- The union of fracture in children is always good and it unites even if left untreated. Commonly seen complications may be malunion and limb length discrepancy (though temporarily in children under

*Correspondence

Dr. Ravindra S. Patil

Assistant Professor, Department of Orthopaedics,
D.Y. Patil Medical College & Hospital, Kolhapur.

E Mail: ravipatilich@gmail.com

10 years of age) but with further growth length correction is achieved

- The bones in children are not strong to withstand trauma of usual activities like athletic activity. Muscles attached to femur are very strong such as gluteus medius over greater trochanter, iliopsoas muscle at lesser trochanter, Adductor muscles to medial and posterior surface of all most entire femur. The natural actions of these muscles produce compression forces around fracture site and their unopposed actions facilitate displacement and over riding
- There are many modalities available in management of fracture femur in paediatric age group.
- Traditionally the fractures of shaft of femur in children were treated conservatively by traction[1,2] , immobilization in Hip spica cast[3,4].In past Indications for surgical management were few & included children with associated injuries like head injury, abdominal injury, compound fracture with extensive soft tissue trauma.
- Conservative management with spica cast was associated with complications such as limb length discrepancy, torsional & angular deformities[5], also there were psychosocial problems associated with spica cast like separation of child from his environment & difficulty in taking care of child in spica cast[6-7], specially when both the parents are working.
- Because of the above complications surgical management has been a preferred modality for treating paediatric femoral shaft fractures[8,9]
- The surgical treatment is reduction and fixation either with flexible nails, rigid intramedullary nails or plates.

In this study we have selected fracture shaft of femur in children aged between 5 to 15 years treated using multiple flexible titanium elastic nails during the year 2013 to 2015. The aim is to study the morphology of diaphyseal fracture of femur in paediatric age group and to assess the outcome/results and complications of treatment of these fractures using titanium elastic nail fixation.

Material and methods

In this study, 35 cases of femoral fractures were studied between June 2013 to April 2015. The method used for fracture fixation was closed reduction & internal fixation using Titanium Elastic Nailing System. Femur was the involved bone under study

- The age of the patient ranged from 5 years to 15 years.
- Patients treated conservatively were not included in the study.
- The duration of follow up was up to one & half years.

The Following protocol was used for the management of these cases:

A) Reception:

1. Administration of first aid on reception of the patient in casualty department.
2. Thorough examination of the patient to rule out head /chest/pelvic/spinal /abdomen injury.
3. Musculoskeletal examination to rule out associated fractures.
4. Stabilization of the patient with IV Fluids, Oxygen and blood transfusion whenever required.
5. Careful assessment of the injured limb as regards the deformity, knee instability and neurovascular status.
6. Primary immobilization of the involved limb in a Thomas' splint with a cotton pad below the distal fragment and the knee joint. The Transportation of the patient to radiology department for the x-rays.
7. The patient was then admitted to the respective ward and evaluated in terms of time and mode of injury, radiological assessment with anteroposterior and true lateral x-ray of the limb.
8. Skin traction was applied to the injured lower limb. In few patients above knee slab was also applied.
9. Analgesics administered and debridement for injuries was done at the earliest possible time, if any.

B) Preoperative preparation :

All the patients admitted and selected for the operative method of treatment underwent the pre-op workup as per the standard protocol as follows -

- Hemoglobin %
- BSL, BUL, SE, Sr.bilirubin.
- Blood group and Rh, typing.
- Chest x-ray and ECG.
- Medical and Surgical references, whenever indicated for operative fitness.

After anaesthetic fitness the patients were posted for surgery as early as possible with the fulfillment of following requirements:

1. Written and Informed consent for surgery & anaesthesia.
2. Adequate blood for transfusion was kept ready.
3. Detailed pre-op planning in regards of classification of the fracture, size of Enders nail. In evaluating the radiograph, fracture lines that

propagate beyond the obvious fracture was noted. The width of the canal was measured at the narrowest point in the diaphysis on both the AP and lateral view and this number was divided by 2. This represented the minimal diameter nail that could be used, and generally a nail at least, 0.5 to 1 mm smaller than this radius was used. Therefore if the medullary canal measured 8 mm, a 3.0 - 3.5 mm nail was used

4. A greater emphasis was given on availability of complete range of Enders nails instruments, image intensifier and radiolucent table.

Procedure was explained to patient & relatives & operative consent taken and taught quadriceps exercises, preoperatively to the patients.

Inj. Tetanus toxoid 0.5cc and Inj.Cefotaxime 500mg were administered preoperatively.

Titanium Elastic Nails were used for fixation in all the 35 patients.

Operative Procedure:

We operated all our patients under general anaesthesia. The choice of approach was closed, which we had employed in our procedures, depended on the fracture classification, and the availability of 'C' arm image intensifier.

1) Patient Positioning:

We operated on all the 35 patients in a supine position on a radiolucent table. After the child was placed on the Fracture table, the leg was prepared and draped with the thigh (hip to knee) exposed. The image intensifier was used to localize the placement of skin incisions by viewing the distal femur in the AP and lateral planes.

2) Entry site:

Both Antegrade and Retrograde insertions of Titanium Elastic Nails have been described but we in our study chose Retrograde insertion to avoid damage to the trochanteric physis entry site. Incisions were made on the medial and lateral side of affected thigh distally. The nail insertion site was about 2 to 2.5 cm proximal to the distal femoral physis. A small bone awl was used to make the entry point in the bone. When opening the medial side, be careful not to let the drill bit slip posteriorly in the region of the femoral artery.

3) Closed Technique:

Titanium Elastic Nails were inserted from the medial and lateral side and driven upto the level of fracture. At this point the fracture was reduced using longitudinal

traction. The first nail was then driven across the fracture by about approximately 2-3 cm. The second nail was then driven across the fracture. The two nails then were driven into the proximal end of the femur with one driven toward the femoral neck and the other toward the greater trochanter. When placing the second nail across the fracture site and rotating it, care was taken not to wind one rod around the other. 'C' arm image intensifier was used to confirm the reduction and position of the two Titanium Elastic Nails before they were seated in the proximal end of femur. The end of the nail was made to lie adjacent to the metaphysis and we tried to keep it at least 1 cm distal to the insertion hole, to allow ease in later removal.

4) Post operative care:

We shifted the patients to the respective wards after the recovery from anaesthesia. Post-op antibiotics were continued till day three when the first dressing was done. Patients were taught static quadriceps exercises on day one and knee flexion exercises on day five. Every patient was given thomas splint post operatively for 2 weeks. Suture removal was done on day fourteen. partial weight bearing was started after suture removal. Hip spica was applied to two of our patients who had fracture of subtrochanteric region of femur.

5) Follow up:

Average Follow was 3 months (3months to 15 months). Every patient was assessed clinically and radiologically at 4 weeks post op and every 4 weekly thereafter till 3 months. Partial weight bearing was advised only after confirming radiological bridging callus and proper gait training. Full weight bearing was allowed only after sound clinical and radiological union which was generally by 8 weeks. The clinical data of each patient was collected in the following proforma.

Result

In our study the age group taken ranged from 5-15 years. 21 were males and 14 were females. Males were involved 1.5 times more than females i.e. 60% of our patients were males and 40% were females. In our study majority of the patients sustained trauma due to Road traffic accidents. 70% of the patients had RTA as the mechanism of injury 20% of the patients had fall from height.10% of the patients were to due assault and fall of heavy object.

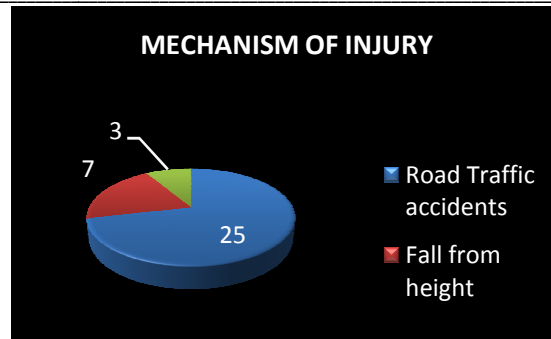


Fig 1: Mechanism of injury

In our study majority of the cases were fractures of M/3rd of diaphysis. i.e. 32 cases out of total 35 cases i.e. 90% of the cases. 3 cases were fracture of U/3rd of diaphysis ,we had to subsequently apply single hip spica post operatively in one of these cases. Out of 35 cases, 2 cases were having fracture of both bone forearm treated simultaneously with enders nailing for femur , fracture of humerus in 1 case and chest trauma in 1 case which was managed first. No major visceral or neuro vascular injuries were noted in this study. Titanium Elastic Nailing was considered only after the general and medical condition of the patient was stable. All the surgeries were planned in respect of availability of implants, operative technique and post op protocol. The injury and surgery interval ranged from 1 to 6 days. The average interval was 2days.Out of 35 cases

31 cases were done by closed technique. While for 4 cases we had to open fracture site as these cases presented late to hospital. The operative time ranged from 30 minutes to 60 minutes (1 hour) with an average time of 40 minutes. Maximum cases i.e. 28 required the operative time of 40 minutes. In 4 of our cases we had difficulty in achieving close reduction, subsequently these were treated with open reduction. In 1 of our initial cases we had difficulty in making the entry point. Majority i.e. 28 cases were hospitalized for upto 7 days. This was the period from the day of admission to the day of discharge. In our study majority of the cases had full union by 6 weeks post operatively i.e. 85% of cases. 2 of our cases had united in 4 weeks (5%) while 3 of our patients took 8 weeks to unite.

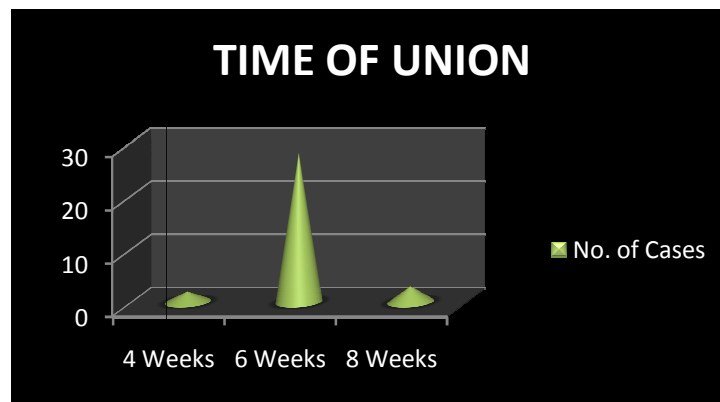


Fig 2: Time of union

Over the period of 1.5 years of follow up, we have observed entry site infection in 2 patients. We observed limb length discrepancy and malunion in none of our cases.

Discussion

In the past Skeletal traction and application of a cast was the preferred method for treatment of diaphyseal

femoral fractures in children. This method stood the test of time because it was relatively conservative and permanent complications impairing future function were rare. However conservative treatment was associated with complications like limb length discrepancy, torsional & angular deformities. Also it was associated with psychosocial problems due to separation of child from his environment & difficulties in taking care of child in spica[4-6].Hence surgical management is increasingly becoming popular. Options for operative treatment of fractures of shaft of femur >5 years include plating, external fixation, antegrade locking nail & flexible intramedullary nail. Compression plating is associated with large soft tissue dissection with increased blood loss, loss of fracture haematoma & chance of infection & another major surgery for removal [10,11,12].External fixator application was associated with complications like pin tract infection, angular deformities, knee stiffness, refracture after removal ,delayed union [13-17]. Rigid intramedullary nailing can damage the blood supply to femoral head causing avascular necrosis of femoral head [18] or growth arrest of greater trochanter causing coxa valga [19].so not advisable in children less than 15 years. The ideal device for the treatment of most femoral fractures in children would be a simple, load sharing internal splint that allows mobilization and maintenance of alignment and extremity length until bridging callus forms. The device would exploit on child's dense metaphyseal bone, rapid healing and ability to remodel, without risking damage to the physis or the blood supply to the capital femoral epiphyses. Titanium Elastic Nailing offers all these advantages. Titanium Elastic Nail fixation provides rapid fracture stabilization, early patient mobilization and potentially anatomic fracture union.Retro grade flexible nailing avoids the risk of avascular necrosis that has been caused by antegrade rigid nailing in children. In the present study the mean age was 8 years,which is in accordance with the previous studies.Erik N Kubiak *et al* [20] (2005) : Mean age 9 years. In the present study 21 were males and 14 were females (Male: female ratio 3:2).Vishwanath Iyer *et al* [21] (2005).This shows higher incidence of shaft femur fracture in males as compared to females, probably because of their more active life style especially in a country like India. 3:2, Male: Female ratio is in accordance with previous studies. Mechanism of injury in previous reported series was as follows :In the present study the predominant mode of injury is road traffic accident, 25 cases (70%) is in accordance with other series. Ligier JN *et al* [22] (1988).Most of our patients were children struck by vehicle while playing on road. Other mode of trauma was fall from height 7

cases (20%) and other like assault, fall of heavy object 3 cases (10%).In the present study 32 of our patients had fracture at middle third of diaphysis i.e. 90% of cases. Erik N Kubiak [20] (2005)3 of our patients had fracture of upper third and in one of these patients the nails used were shorter than the actual length making the fracture fixation unstable. Hence single hip spica was applied to one of our patients. In the present series the fracture of femur was transverse in 28 (80%) out of 35 cases. In the remaining 7 (20%) cases the fractures were oblique or comminuted. Vishwanath Iyer *et al* [21] (2005),In the present study 4 of our patients (10%) of cases had associated injuries in the form of fracture of both bone forearm in 2 cases (contralateral in 1 and ipsilateral in 1 case), fracture of shaft of humerus in 1 case and chest trauma in 1 case.There were no associated injuries to head, abdomen or pelvis. The associated injuries did not influence the final outcome of the femoral fractures but prolonged the hospital stay. In the present study the Avg. injury-surgery interval was 2 days. (Range 1 - 6 days). In some cases the injury surgery interval was more because of late presentation of child to hospital. Erik N Kubiak[20] (2005).In the present series closed retrograde nailing, which was done in 31 cases (90%) & in 4 cases(10%) open reduction was done.Vishwanath Iyer *et al* [21] (2005)

Intra-operative difficulties

In the present study in 4 of our cases we had difficulty in achieving closed reduction because the patients presented late after injury subsequently the injury surgery interval was more, these were treated with open reduction.Vishwanath Iyer *et al* [21] (2005).It is also observed that closed nailing definitely benefited the patients by reducing their period of hospitalization by virtue of early mobilization and minimum surgical trauma. Vishwanath Iyer *et al* [21].In the present study, early union was seen in 2 of our cases i.e. 10% which united clinically and radiologically by four weeks these children were aged 5years.. 28 of our cases i.e. 80% had united by six weeks and 2 of our patients i.e. 10% took eight weeks. Period of full weight bearing: In the present study the average time to full weight bearing was 6 weeks. Ligier JN *et al* [22] (1988). In the present study, in 1 of our patients there was irritation at the nail entry site leading to infection at the entry site. In these cases nails were removed in 3 weeks and further treated with hip spica cast application. In two of our early cases, the distal end of the nail was very long and bent excessively the tip of nail had penetrated the cortex impinging on skin leading to subsequent wound breakdown, but neither deep infection nor

osteomyelitis developed. These children were treated by nail removal and the final result was satisfactory. Mazda K *et al* [8] (1997)

Conclusion

In the present study, we recommend that elastic stable Titanium Elastic Nailing System may be a good choice for the treatment of femoral shaft fractures in skeletally immature patients in need of surgical stabilization. Titanium Elastic Nailing System is a minimally invasive technique requiring a small incision, leading to good callus formation, early mobilization, full recovery of function with minimal complications.

References

- Buck G. An improved method of treating fractures of the thigh illustrated by cases and a drawing. *Trans NY Acad Sci.* 1861;2:232-250.
- Bryant T. *The practice of surgery.* Edited, Philadelphia: HC Lea; 1873.
- Dameron TB, Thompson HA. Femoral shaft fractures in children treated by closed reduction and double spica cast immobilization. *J Bone Joint Surg (Am).* 1959; 41-A:121-122.
- Mital MA, Bonadio O. Fractures of the shaft of the femur: Progress in treatment (1961-1971). *Am J Surg.* 1979;127:434-441
- Reeves RB, Ballwered RI, Hughes JL. Internal fixation versus traction and casting of adolescent femoral shaft fractures. *J Pediatr Orthop.* 1990;10:592-595.
- Greisberg J, Bliss MJ, Ebersson CP, Solga P, D'Amanto C *et al.* Social and economic benefits of flexible intramedullary nails in treatment of pediatric femoral shaft fractures. *Orthopedics.* 2002 ;25(10):1067-70.
- Hughes BF, Sponseller PD, Thompson JD. Pediatric femur fractures effect of spica cast treatment of family and community. *J Pediatr Orthop.* 1995; 15:455-460.
- Mazda K, Kharouni A, Pennecot GF *et al.* Closed flexible intramedullary nailing of the femoral shaft fractures in children. *J Pediatr Orthop.* 1997; 6: 198-202.
- Karaoglu S, Baktir A, Tuncal M, Karakas ES, Sakir TM. Closed Ender nailing of adolescent femoral shaft fractures. *Injury.* 1994 Oct; 25(8):501-6
- Ziv I, Rang M. Treatment of femoral fracture in the child with head injury. *J Bone Joint Surg (Br).* May 1983;65(3):276-278
- Mirdad T. Operative treatment of femoral shaft fractures in children: a 9-year experience in a Saudi Arabian population. *Injury.* 2000;31:769-771
- Vavilala MS, Bown A, Lam AM. Blood pressure and outcome after severe pediatric traumatic brain injury. *Trauma.* 2003;55:1039-1044.
- Aronson J, Tursky RN. External fixation of femur fractures in children. *J Pediatr Orthop.* 1992; 12(2);157-163
- Gregory P, Pevny T, Teague D. Early complications with external fixation of pediatric femoral shaft fractures. *J Pediatr Orthop.* 1996;10:191-198
- Hull JB, Sanderson PL, Rickman M, et al. External Fixation of childrens femoral fractures. *J Pediatr Orthop (Br).* 1997;6:203-206
- Skaggs DL, Left AI, Money MD. Secondary fractures associated with external fixation in pediatric femur fractures. *J Pediatr Orthop.* 1999;19:582-586
- Miner T, Carrolll KL. Outcomes of external fixation of pediatric femoral shaft fractures. *J Pediatr Orthop.* 2000;20:405-410
- Stans AA, Morrissy RT, Renwick SE, *et al.* Femoral shaft fracture treatment in patients age 6 to 16 years. *J Pediatr Orthop.* 1999;19 :222-228.
- Raney EM, Ogden JA, Grogan DP. Premature greater trochanteric epiphysiodesis secondary to intramedullary femoral rodding. *J Pediatr Orthop.* 1993;13: 516-520
- Erik N Kubiak. Operative treatment of femoral fractures in children: are elastic stable intramedullary nails an improvement over external fixation. *J Bone Joint Surg (Am).* 2005;87;1761-1768
- VishwanathIyer, Shivshankar. Treatment of femoral fractures in children by elastic intramedullary nails. *Journal of Maharashtra Orthopaedic Association.* Sept.2005:23-26.
- Ligier JN, Metaizeau JP, Prevot J, *et al.* Elastic stable intramedullary nailing of femoral shaft fractures in children. *J Bone Joint Surg(Br).* 1988; 70 B :74-77.

Source of Support: Nil

Conflict of Interest: None