

## Melanoma with unknown primary presenting as pleomorphic malignancy– Role of Immunohistochemistry in the diagnosis

Sandip dukare<sup>1</sup>, Rajesh thakur<sup>2</sup>, Vikas narhire<sup>1</sup>, Shweta ranka<sup>2</sup>, Priya deshpane<sup>2</sup>

<sup>1</sup>Assistant professor, Department of Pathology, Swami Ramanand Teerth Rural Government Medical College and Hospital, Ambajogai, Maharashtra, India

<sup>2</sup>Residents, Department of Pathology, Swami Ramanand Teerth Rural Government Medical College and Hospital, Ambajogai, Maharashtra, India

### ABSTRACT

Melanoma with unknown primary (MUP) accounts for approximately 1% to 8% of all melanomas and was described first in 1952. We report a case of a 95 year old male with a painless, progressively increasing swelling of the inguinal region, which on investigations came out to be malignant melanoma metastatic to inguinal nodes, without clinical or radiological evidence of a known primary. Metastatic melanoma is often confused with a variety of poorly differentiated carcinomas, sarcomas, and large cell lymphomas. Immunohistochemistry along with histopathology is important in the diagnosis and sub-classification of tumors. The importance of presenting this paper is to highlight the rare presence of malignant melanoma metastatic to lymph nodes with an unknown primary, and the role of immunohistochemistry in the diagnosis.

**Keywords:** Inguinal nodal metastasis, metastatic melanoma, unknown primary, Immunohistochemistry.

### Introduction

Melanoma with unknown primary (MUP) accounts for approximately 1% to 8% of all melanomas and was described first in 1952.[1]The clinical presentation of MUP with nodal metastasis (American Joint Committee on Cancer stage III) is characterized by palpable lymphadenopathy without an apparent primary melanoma and without evidence of further metastatic disease.[2]

Metastatic melanoma is often confused with a variety of poorly differentiated carcinomas, sarcomas, and large cell lymphomas and hence always needs to be considered in differential diagnosis of these malignant tumors. Accurate diagnosis is needed for treatment as well as prognosis. Immunohistochemistry along with histopathology is important in the diagnosis and sub-classification of tumors.

In the pre-immunoperoxidase era, the only useful special stains in establishing the diagnosis were melanin stains such as the Fontana-Masson stain and the Warthin-Starry stain. These stains have been largely replaced by immunoperoxidase stains. Many IHC markers, especially in lymphomas, also have a role in predicting the prognosis.[3] The panel of tumor markers, most commonly used for evaluation of melanoma includes HMB45, S-100 protein, CEA, EMA, Melan-A & Vimentin, an intermediate filament.

The limitation of these stains is that some malignant melanomas are amelanotic, causing the stains to be negative.

### Case history

We report the case of a 96 yr old male who presented with a painless progressively increasing swelling in his left inguinal region for the past two months. There was no history of any cutaneous lesion, previous skin biopsy, urinary or bowel complaints, visual disturbances, chronic headache or seizures. On examination, there was a 4 x 3cm lump in the left inguinal region. It had bosselated surface with bluish hue and limited side to side mobility. The rest of the examination including proctoscopy,

\*Correspondence

**Dr. S. R. Dukare**

Department of Pathology, Swami Ramanand Teerth Rural Government Medical College and Hospital, Ambajogai, Maharashtra, India.

**Email:** [pdlshripadpatil@gmail.com](mailto:pdlshripadpatil@gmail.com)

**Contact No.** +91-8275232451

colposcopy, otorhinological and ophthalmologic examinations was unremarkable. FNAC from the mass revealed it to be a pleomorphic malignancy-?malignant melanoma(fig. 1). A diagnosis of pleomorphic malignancy-? malignant melanoma of the left inguinal lymph nodal region with an unknown primary was made and the patient was taken up for excision of tumour mass with complete ilioinguinal lymph node dissection.

Intraoperatively, there was a lymph nodal mass measuring 3 x 2cm in the left superficial inguinal lymph nodal basin with multiple lymph nodes along the external iliac artery. Postoperatively, the patient had an unremarkable recovery. The HPE revealed it to be malignant melanoma (Melan A & HMB 45 positive)

metastatic to inguinal lymph nodes. Grossly it was a circumscribed mass of size 3x2 cm, Cut surface- gray white. On microscopy section showed thin fibrous capsule of lymph node, underneath shows strip of normal lymphocytes and total effacement of lymph node architecture replaced by tumor tissue composed of large round and spindle cells with high N: C ratio, scanty cytoplasm, nuclear pleomorphism and prominent nucleoli. Cells arranged in sheets and nests (fig. 2). On immunohistochemistry the tumor cells show strong immunopositivity for vimentin and Melan A and focal immunoreactivity for S-100 protein and HMB 45.The tumor cells were immunonegative for pancytokeratin (fig. 3-7).

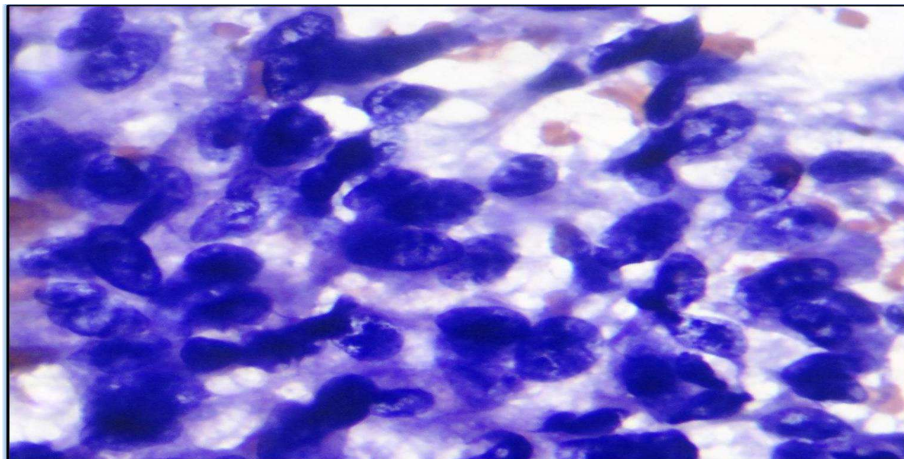


Figure 1: Shows pleomorphic malignant cells having pleomorphic nuclei with prominent nucleoli(Pap 100X)

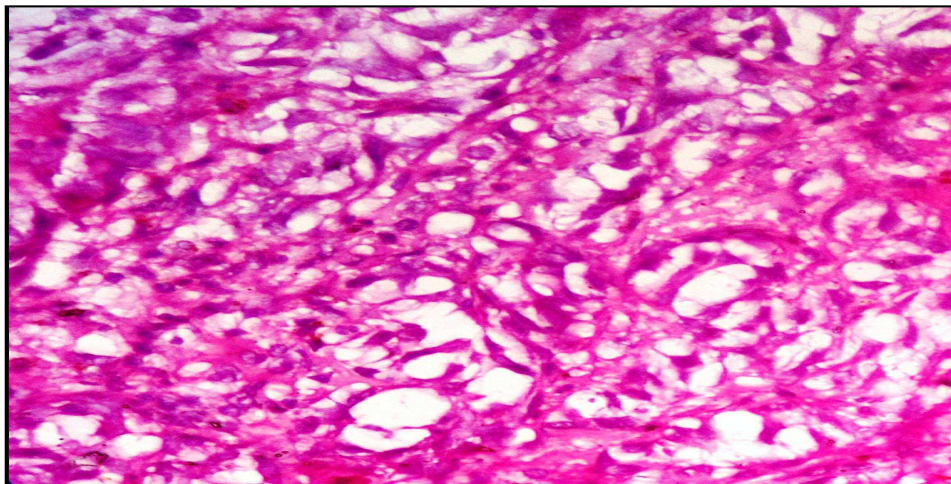
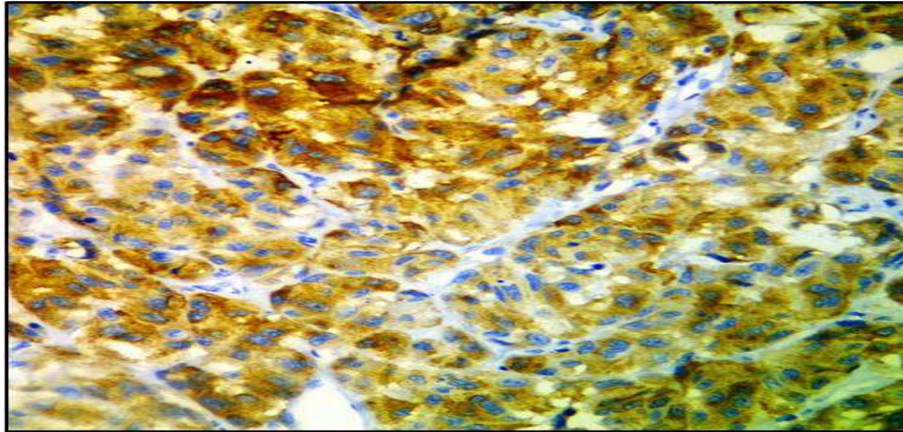
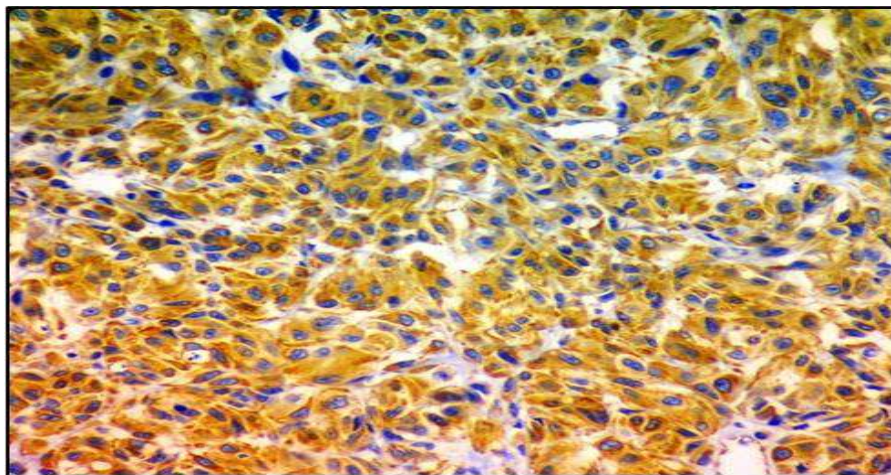


Figure 2: Shows large round and spindle cells with high N:C ratio, nuclear pleomorphism and prominent nucleoli (H&E 40X)

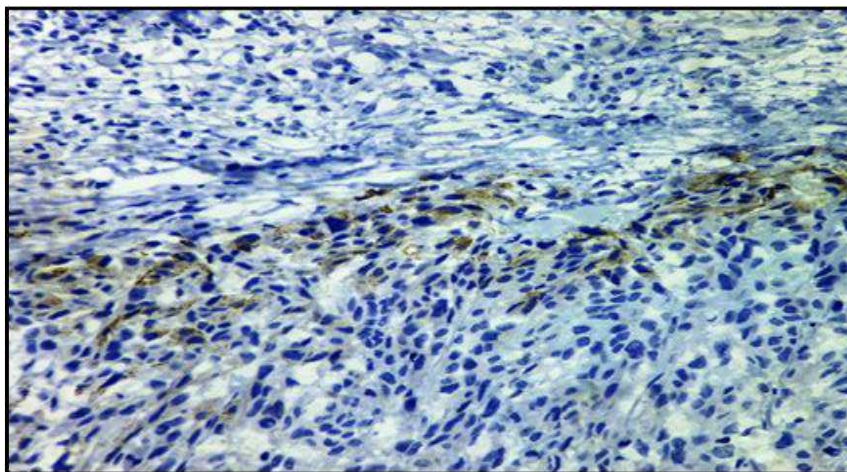




**Figure 3: Shows Melan A positive**



**Figure 4: Shows Vimentin positive**



**Figure 5: Shows HMB45 focal positive**



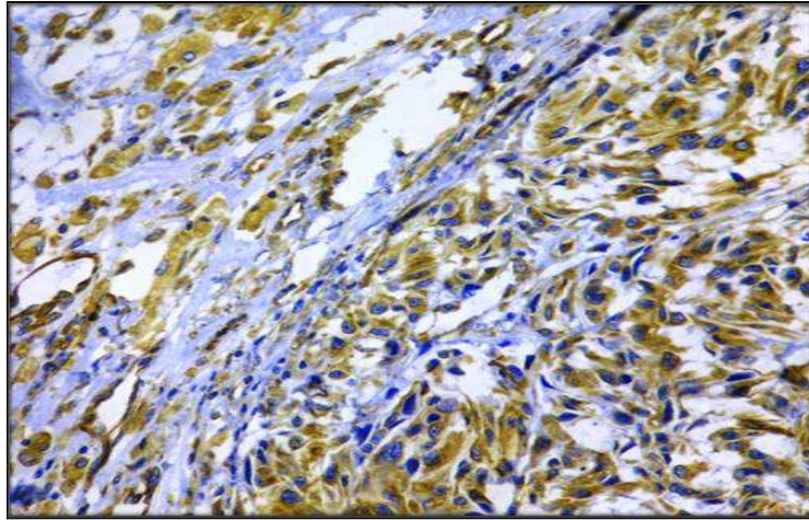


Figure 6: Shows S-100 Focal positive

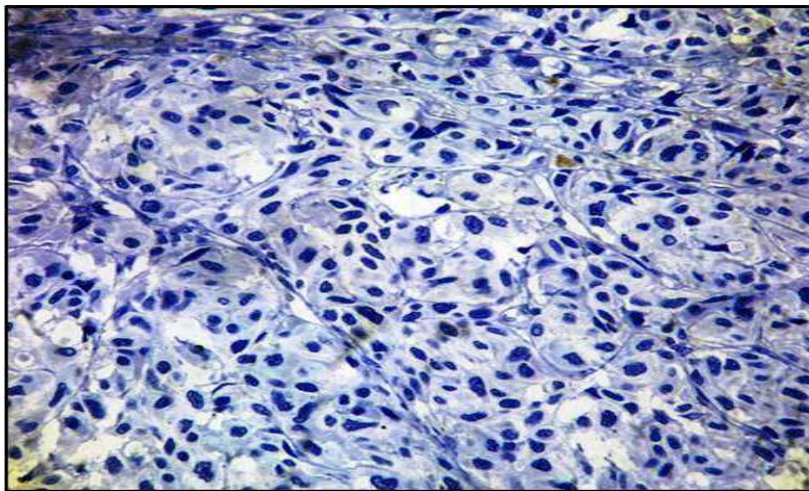


Figure 7: Shows Cytokeratin negative

### Discussion

Metastatic unknown primary occurs in less than 8% of all melanomas, with the axillary lymph nodal basin most commonly involved. Although the true etiology of an MUP is unknown, several explanations have been suggested and include 1) a concurrent, unrecognized melanoma; 2) a previously excised melanoma that was misdiagnosed either clinically or pathologically; 3) an antecedent, unrecognized, spontaneously regressed primary melanoma; and 4) the de novo malignant transformation of an aberrant melanocyte within a lymph

node.[4] One commonly accepted theory is that an unrecognized primary lesion has undergone spontaneous regression mediated by an endogenous immune response.[5]

Metastatic melanoma should be considered in the differential diagnosis of all patients who present with a malignancy of unknown origin, particularly when lymph nodes are the primary presenting site. Metastatic melanoma is often confused with a variety of poorly differentiated carcinomas, sarcomas, and large cell lymphomas. Fine-needle aspiration or core biopsy of the lymph node lesion usually is adequate for tissue

diagnosis, but immunohistochemical studies (i.e., immunoreactivity for S-100, vimentin, and HMB-45) and electron microscopy studies looking for melanosomes or premelanosomes also may be obtained in the event of equivocal findings.[6]

Immunohistochemistry along with histopathology is important in the diagnosis and sub-classification of tumors. According to Gibbs JF *et al* [7] definitive diagnosis should await permanent H&E sections and IH staining. Since the advent of reliable immunoperoxidase stains, the use of an initial screening panel of immunoperoxidase markers (eg, S-100, pancytokeratin, CD45) has become routine in poorly differentiated tumors to determine the cell lineage. This is followed by a second panel of immunoperoxidase markers to narrow the possibilities or confirm the diagnosis. The panel of tumor markers most commonly used for evaluation of melanoma includes HMB45, S-100 protein, CEA, EMA, Melan-A & Vimentin an intermediate filament. According to Lewis KD *et al* [3] the most common mistake made in undifferentiated tumors is to use only a single marker to diagnose malignant melanoma. This approach is fraught with potential errors since malignant melanomas can occasionally express unexpected markers. Poorly differentiated tumors need to express at least two melanoma immunoperoxidase markers (ie, S-100, KBA-62, HMB-45, or melanin-A) before a firm diagnosis of malignant melanoma is rendered. DJ Karimipour *et al* [8] reported the sensitivities of S-100, HMB-45, and Melan-A to 97%, 75%, and 96% respectively.

### Conclusion

Malignant melanoma with unknown primary is a rare entity that should be considered in the differential diagnosis of all patients presenting with malignant lymphadenopathy with an unknown primary. Poorly differentiated malignancies that are suspicious for malignant melanoma are best diagnosed by a screening panel of immunoperoxidase markers followed by a second panel to confirm the diagnosis.

### Acknowledgement

Department of Pathology, Swami Ramanand Teerth Rural Government Medical College and Hospital, Ambajogai, Maharashtra, India.

### References

1. Pack GT, Gerber DM, Scharnagel IM: End results in the treatment of malignant melanoma; a report of 1190 cases. *Ann Surg*; 1952; 136: 905-911.
2. Chris C. Lee, Mark B. Faries, Leslie A. Wanek, and Donald L. Morton: Improved Survival After Lymphadenectomy for Nodal Metastasis From an Unknown Primary Melanoma. *J Clin Oncol*;2008;26:535-541.
3. Lewis KD, Dollarhide S, Fitzpatrick JE, Gonzalez R, High WA, McCarter MD, Olsen C, Raben D: Metastatic Malignant Melanoma From an Unknown Primary Presenting as a Large Axillary Mass. *Oncology (Williston Park)*. 2006;20(7):763-70.
4. Anbari KK, Schuchter LM, Bucky LP, et al.: Melanoma of unknown primary site: presentation, treatment, and prognosis-A single institution study. *Cancer*; 1997; 79: 1816-1821.
5. Giuliano AE, Cochran AJ, Morton DL: Melanoma from unknown primary site and amelanotic melanoma. *Semin Oncol*;1982;9:442-447.
6. Chorost MI, Lee MC, Yeoh CB, et al.: Unknown primary. *J Surg Oncol*; 2004; 87: 191-203.
7. Gibbs JF, Huang PP, Zhang PJ, Kraybill WG, Cheney R. Accuracy of pathologic techniques for the diagnosis of metastatic melanoma in sentinel lymph nodes. *Ann Surg Oncol*. 1999;6(7):699-704.
8. Karimipour DJ, Lowe L, Su L, Hamilton T, Sondak V, Johnson TM, Fullen D. Standard immunostains for melanoma in sentinel lymph node specimens: which ones are most useful? *J Am Acad Dermatol*. 2004;50(5):759-64.

Source of Support: NIL

Conflict of Interest: None