

Morphometric Study on Cruciate Ligaments Of Knee With Gender Differences: A Cadaveric Study

Anil Kumar Reddy Yelicharla*, Ujwal Gajbe, Brijraj Singh

Department of Anatomy, Jawaharlal Nehru Medical College, Sawangi (M), Wardha, Maharashtra, India

ABSTRACT

Introduction: There are many factors which help for the stability of knee, out of all, the cruciate ligaments are considered as key factors. Lesions of cruciate ligaments can occur separately; sometimes combined lesions can also be observed. The joint stability can be achieved with surgical correction of cruciate ligaments and this is essential to prevent secondary osteoarthritis. Surgical repair of these ligaments require clear anatomical knowledge and detailed morphometry. The aim of the current study was to record the various measurements of anterior and posterior cruciate ligaments in both sexes and to evaluate the results statistically. **Materials and Methods:** Morphometric measurements of cruciate ligaments of knee was recorded in 72 unpaired knees (40 Males, 32 females), which are obtained from 10% formalin fixed cadavers of aged 48 ± 9 years. **Observations & Results:** The mean age of male and female cadavers had no significant differences in terms of gender distribution. After analysis it was observed that the mean length and width of ACL was significantly more in males compare to females ($P < 0.05$). The mean values of PCL also had shown significant differences between males and females except in length and width. The mean length of PCL has shown slight difference between males (36.9 ± 3.9 mm) and females (36.9 ± 3.4 mm), it was not significant statistically ($P > 0.05$). **Conclusion:** Orthopaedic surgeons should keep in mind, the mean Gender differences in morphometric measurements of cruciate ligaments while executing the surgical repair of cruciate ligaments individually either in males or females.

Keywords: Knee, Cruciate, Morphometric, Gender.

Introduction

Cruciate ligaments are the very strong ligaments of knee joint; there are two cruciate ligaments, one being anterior other being posterior in par with their attachments on the tibia^[1]. Knee joint is one of the complex synovial joint in the body comprising of patello-femoral joint and tibio-femoral joint. Nevertheless the joint cavity is mainly formed by the tibia and femur, which are connected by the four main ligaments, two collateral ligaments on the sides of the knee and two cruciate ligaments i.e. Anterior Cruciate Ligament (ACL) and Posterior Cruciate Ligament (PCL) inside the knee [1, 2]. Cruciate ligaments are the back bones of knee joint play an important role in stability.

ACL is a tough band of tissue runs diagonally from the anterior intercondylar area of the tibia to the posteromedial aspect of the lateral femoral condyle [3, 4].

ACL prevents the sliding of tibia from the femur, helps in rotational movements and also helps in control the back and forth movements of the lower leg [1, 3]. According to the standard anatomical textbooks, the average length and width of an adult ACL are 38 mm and 11 mm respectively and it is made up of two or possibly three functional bundles namely anteromedial, intermediate, and posterolateral [1]. But most of the research studies revealed that ACL consists of two bundles mainly Anteromedial (AM) bundle and Posterolateral (PL) bundle according to their tibial attachments. An electron microscopic study reveals that both bundles are made up of collagen fibers, which run parallel in a helical and planar wave pattern [4-6]. Congenital absence of the anterior cruciate ligament is rare. This condition is usually associated with lower limb dysplasia, and may be a cause of instability of the knee [1, 4].

*Correspondence

Anil Kumar Reddy Yelicharla
Tutor, Department of Anatomy,
Jawaharlal Nehru Medical College,
Sawangi(M), Wardha, Maharashtra, India
E Mail: kumarlucky48@gmail.com

PCL attaches to the lateral surface of the medial femoral condyle and to the posterior intercondylar area of the tibia. The average length and width of an adult posterior cruciate ligament was 38 mm and 13 mm respectively [1, 6]. It is composed of two bundles, Anterolateral (AL) and posteromedial (PM) bundles; they are named according to their femoral attachments [6, 7]. PCL is the main primary restrictor of posterior translation of the knee and the secondary restrictor of varus, valgus and external rotational movements of knee joint. The role of PCL in knee joint stability is less compared to the ACL. PCL being wider and stronger than ACL, injuries to this ligament is not as common as to ACL [3, 7].

The ACL of knee is the most commonly injured ligament, representing the 60% of all knee injuries [8]. The incidences of ACL injuries in India are increasing in last few years especially in young female athletes. ACL tear is usually associated with other injuries like medial collateral ligament tears and the menisci (shock absorbing cartilages) of the knee, which causes functional instability of knee joint [5, 9]. As we know that ACL is made up of collagen fibrils, the amount of collagen fibril population changes during maturation and it increases with the level of stress on the ligament. So it determines that the amount of fibril diameters of ACL is very important during reconstructing surgeries [9]. ACL injuries shows long term effects on knee joint such as degenerative joint disease, secondary osteoarthritis. So, reconstruction of ACL is essential in injured cases. For planning reconstruction surgery techniques it is essential to know the detailed anatomy and morphometric measurements of ACL [10]. The Morphometric analysis of PCL has great value during surgical treatment of injured PCL, in fact it is observed that graft stretching or shortening with flexion when the tunnels are misplaced while reconstructing the PCL [6]. The present study was aimed to demonstrate the various Morphometric measurements of ACL and PCL of knee joint and also for evaluating gender differences through morphometric analysis. This study contributes to the morphometric data on cruciate ligaments and it is different from other studies by evaluating the gender differences.

Materials and methods

The current research study was scrutinized and approved by the Institutional Ethical committee. The anatomical and morphometric study of cruciate ligaments of knee joint was carried out on 72 unpaired knee joints of aged 48 ± 9 years, out of 72 knees, 40 belong to males and 32 belong to females. None of those had the presence of macroscopic arthritic lesions and signs of instability, deformity or any other lesion.

All the cadavers were embalmed by routine embalming procedure with 10% formalin. Each knee joint was dissected in a typical manner; initially the skin and soft tissue surrounding the joint was removed, for freeing the muscles, fat was cleaned properly. The muscle was cut along with vessels and nerves above and below the joint in order to expose ligaments and capsule of the knee joint. The patella has pulled down along with its ligament, collateral ligaments were cleaned properly and cut has been made on one side for better view of the cruciate ligaments. The capsule was removed from the posterior aspect of knee, then the ACL and PCL was identified [1, 2, and 4]. The femoral and tibial attachment of cruciate ligaments has been cut very close to the bone with the help of a scalpel.

The maximum length and width (at middle $1/3^{\text{rd}}$) of anterior and posterior cruciate ligaments were taken in relaxed position of knee. The length and width of ACL and PCL at the femoral and tibial attachments were measured and cross sectional area at both attachments were derived. All the measurements are recorded with the help of vernier callipers.

All the data was collected and analyzed by using Statistical product and Service Solution (SPSS). The mean was calculated with the standard of deviation. Differences between Males and Females were analysed with P value (<0.05).

Results & statistical analysis

The present study was done on 72 unpaired knee joints, out of 72 knees 40 knees belong to males and remaining 32 knees belong to females. The dissection of each knee joint was done typically, measurements were taken for each knee joint and analysed by means of statistical software. The mean age of cadavers was 48 ± 9 years. The mean age of male and female cadavers had no significant differences in terms of gender distribution.

After analysis it was observed that the mean length and width of ACL was significantly more in males compared to females ($P < 0.05$). The mean length of ACL was 43.5 ± 4.1 mm in males and 41.9 ± 3.9 mm in females. The average width of ACL was 12.1 ± 2.4 mm in males and 11.0 ± 1.8 mm in females (Table 1). It was observed that the mean length at femoral attachment of ACL was 3.8 ± 0.9 mm, 3.2 ± 0.69 mm in males and females respectively. The average measurement of ACL width at femoral attachment was 8.3 ± 1.4 mm, 8.2 ± 1.1 mm in males and females respectively. The mean cross sectional area of ACL at femoral attachment has shown statistical significant values ($P < 0.05$) and it was greater in males (29.1 ± 3.2 mm) than in females (30.2 ± 3.5 mm).

mm) (Table 2). The length (12.7 ± 1.5 mm in males and 12.2 ± 1.3 in females) and width (11.8 ± 1.8 in males and 11.3 ± 1.6 in females) of ACL at tibial attachment was slightly larger in males when compare to the females, but it was not significant statistically. The mean cross sectional area of ACL at tibial attachment (Figure 4) was significantly ($P < 0.05$) higher in males (133.5 ± 8.3 mm) than in females (129 ± 8.0) (Table 3).

The mean values of PCL also had shown significant differences between males and females except in length and width. The mean length of PCL has shown slight difference between males (36.9 ± 3.9 mm) and females (36.9 ± 3.4 mm), it was not significant statistically

($P > 0.05$). The mean width of PCL was 9.2 ± 2.3 mm, 9.1 ± 2.2 mm in males and females respectively, even though there was slight difference in mean values, it was not significant ($P > 0.05$) (Table 1). The length and width of femoral and tibial attachment of PCL has shown statistically significant gender differences ($P < 0.05$). The considerable differences has been observed in mean cross sectional area of PCL at femoral attachment and it was 90.3 ± 4.9 mm in males and 84.4 ± 3.6 in females (Table 2). The mean cross sectional area of PCL at tibial attachment (Figure 4) was 109.2 ± 5.3 mm in males and 106.4 ± 4.6 mm in females (Table 3). All the measurements of PCL show considerable lower values than ACL.

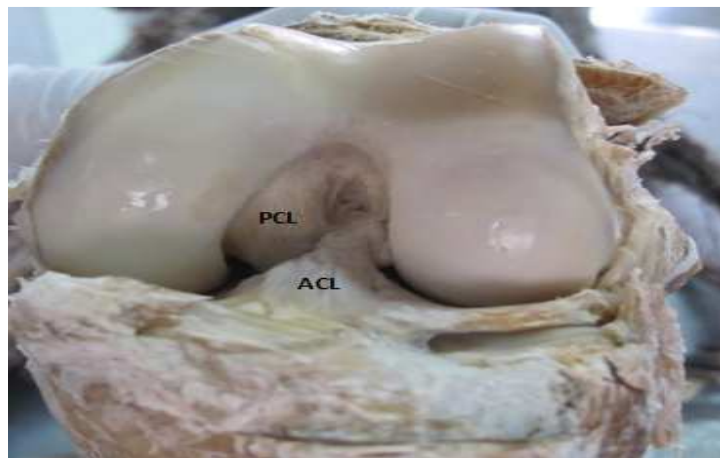


Figure 1: Photograph showing anterior view of knee in flexion presenting Anterior cruciate ligament and Posterior cruciate ligament after detaching the patella with its ligament

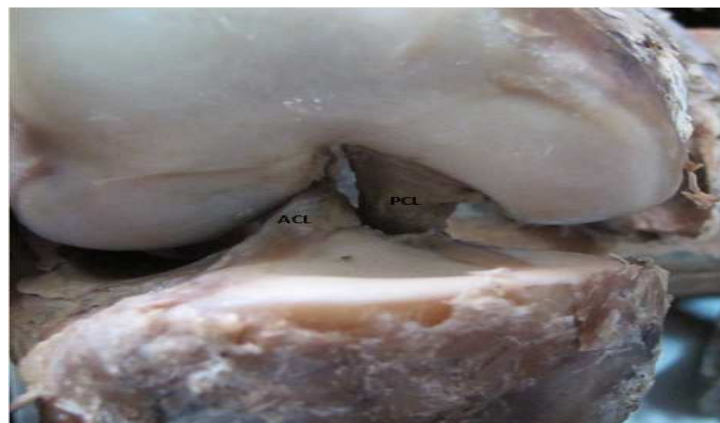


Figure 2: Photograph showing lateral view of knee with appearance of Anterior cruciate ligament and PCL Posterior cruciate ligament after removing the lateral ligaments, joint capsule and Menisci

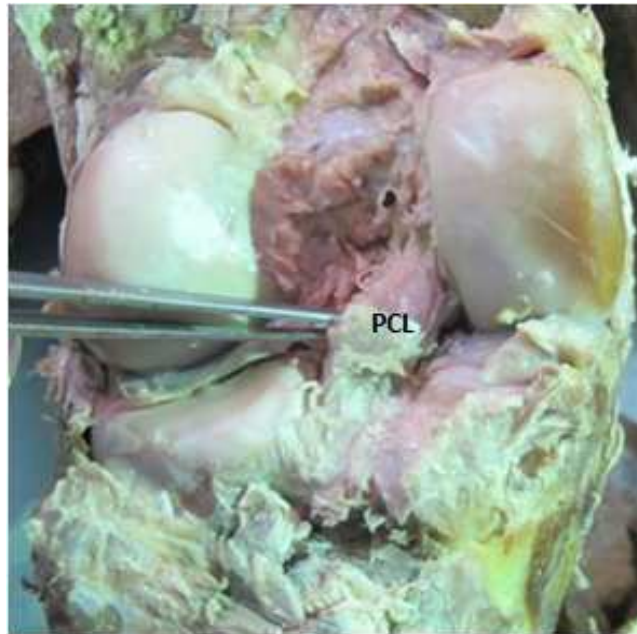


Figure 3: Back of knee in full extension showing PCL (Posterior cruciate ligament) after removing the Medial and lateral heads of Gastrocnemius muscle, plantaris muscle, popliteus muscle with its tendons and joint capsule

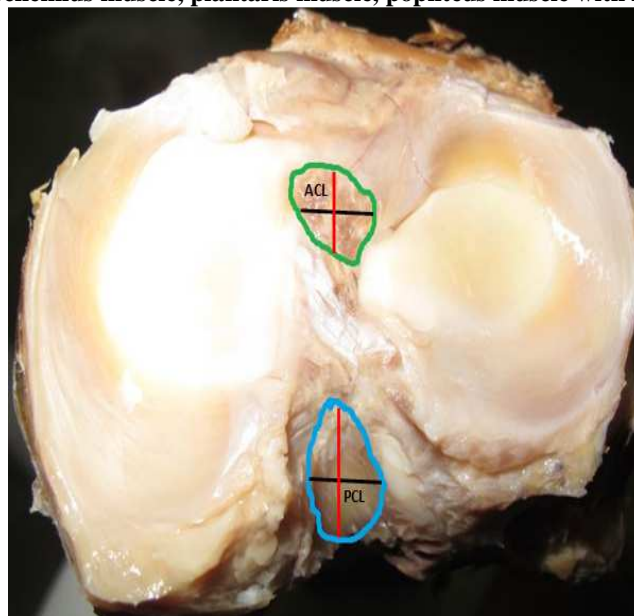


Figure 4: Intercondylar area of tibia presenting tibial attachment of Anterior cruciate ligament and Posterior cruciate ligament with reference markers

— Width
— Length

Table 1: Showing the Mean values of Length and Width

S. No	Parameters	Gender	ACL			PCL		
			Mean	SD	P value	Mean	SD	P value
1	Length	M	43.5	4.1	0.04	35.9	3.4	0.06
		F	41.9	3.9		37.1	3.9	
2	Width	M	12.1	2.4	0.04	8.2	2.0	0.07
		F	11.0	1.8		9.1	2.2	

P<0.05 considered as Significance; □ M-Male; F- Female

*ACL – Anterior Cruciate ligament

*PCL – Posterior Cruciate ligament

*SD – Standard Deviation

Table 2: Showing the Mean values of ACL and PCL at Femoral attachment

S. No	Parameters	Gender	ACL			PCL		
			Mean	SD	P value	Mean	SD	P value
1	Length at femoral attachment	M	3.8	0.9	0.04	10.1	1.2	0.03
		F	3.2	0.69		9.12	0.83	
2	Width at femoral attachment	M	8.3	1.4	0.04	10.3	1.1	0.03
		F	8.2	1.1		9.58	0.94	
3	Cross sectional area	M	29.1	3.2	0.03	90.3	4.9	0.02
		F	30.2	3.5		84.4	3.6	

P<0.05 considered as Significance; □ M-Male; F- Female

*ACL – Anterior Cruciate ligament

*PCL – Posterior Cruciate ligament

*SD – Standard Deviation

Table 3: Showing the Mean values of ACL and PCL at Tibial attachment

S.No	Parameters	Gender	ACL			PCL		
			Mean	SD	P value	Mean	SD	P value
1	Length at Tibial attachment	M	12.7	1.5	0.05	19.6	0.96	0.04
		F	12.2	1.3		17.2	0.7	
2	Width at Tibial attachment	M	11.8	1.8	0.05	5.82	1.2	0.04
		F	11.3	1.6		5.3	1.0	
3	Cross sectional area	M	133.5	8.3	0.03	109.2	5.3	0.04
		F	129	8.0		106.4	4.6	

P<0.05 considered as Significance; □ M-Male; F- Female

*ACL – Anterior Cruciate ligament

*PCL – Posterior Cruciate ligament

*SD – Standard Deviation

Discussion

The current research work was to provide a detailed anatomical and morphometric data for the ACL and PCL regarding their Length, Width, Femoral and Tibial

attachments. The Cruciate ligaments play a major role in stability of knee, these ligaments bind the femur and tibia, so that it prevents the sliding of tibia from femur,

also helps in rotational movements and it controls the back and forth movements of knee [11]. Whenever there is a tear or rupture of cruciate ligaments, the surgical reconstruction of these ligaments is necessary in order to maintain proper movements of knee, henceforth for the surgical repair of cruciate ligaments it is mandatory that orthopaedic surgeons should have detailed anatomical knowledge about cruciate ligaments [12, 13].

The mean length of ACL in present study was 43.5 mm; 41.9 mm in males and females respectively, the mean width of ACL was 12.1 mm in males and 11 mm in females. Our study reflects the gender differences in mean values; this type of study has been reported only by few authors. Some of the authors described ACL as one entity without any gender differences; several studies have done on separate bundles of ACL. In our study, the obtained values are statistically significant ($P < 0.05$). Similar findings have been reported by Odensten M^[14], Gillquist J *et al* [15] (32 mm) (1996), Harner CD *et al* (2000) [16]. Odensten [14] measured length of ACL in 33 cadaveric knees reported an average length of 31 mm. Anderson AF *et al* [13], studied width of ACL on MR images of 16 years aged basket ball players and got the significant higher values in males (8.7mm) than in females (7.6mm). The cross sectional area at femoral attachment of ACL was 29.1 mm and 30.2 mm in males and females respectively. At the tibial attachment, the mean cross sectional area was 133.5mm in males and 129 mm and females, our findings were in agreement with the studies reported by Eleni Triantafyllidi [17] (2013), Beynon BD *et al* [18] (2002). The results found at the femoral attachment are not in conformity with studies reported by Siebold R (2008) [19], Mochizuki T *et al* (2013) [20]. Most of the authors mentioned that the femoral and tibial insertions of ACL is oval in shape, unfortunately, such study has not been done in present research because it is difficult to maintain the shape of ACL in cadavers which are embalmed by classical method. The ACL was identified as frequently injured ligament of the knee; it represents half of all knee injuries [16, 17]. The length of ACL is very important in obtaining the graft for surgical reconstruction and the data on ligament thickness at the femoral and tibial attachments gives clear description for obtaining the amount of graft from donor site. In current study, the acquired mean values for length and width of PCL was not showing much difference between males and females and it is not significant statistically. Our findings were identical with results reported by Takahashi *et al* [21] (2006), Lopes *et al* [22] (2008), and Cury *et al* [23] (2011). The mean cross sectional area at femoral attachment of PCL was significantly larger in males (90.3 mm) than females (84.4 mm). Dargel *et al* [24]

(2006), studied the femoral insertion of PCL by means of radio opaque barium sulphate emulsion in 30 paired knees, they reported that the femoral insertion of the PCL was 133.8 mm in the left knee and 147.1 mm in the right knees. Cury *et al* [23] (2011), found that the total insertion area of the PCL was 153.5 mm. Takahashi *et al* [21] (2006), reported femoral insertion of the AL bundle was 58.0 ± 25.4 mm and the insertion area of the PM bundle was 64.6 ± 24.7 mm, they measured in 32 knees by means of photographs having measurement scale, with subsequent digital analysis. The findings of Lopes *et al* [22] (2008) on femoral insertion of PCL were 118.0 mm for AL bundle and 90.0 mm for PM bundle, they studied on 20 knees by using photographs, which were taken by using a three-dimensional laser equipped digital camera and the obtained images were analysed with the help of specific software.

In our findings, the mean value of PCL at tibial attachment was not significant; the results reported by various authors are in contrast with the current study. Cury *et al* [23] (2011), Amis AA *et al* [6] (2006), found that the mean values at tibial insertion were significantly larger in males compare to females. Eleni Triantafyllidi [17] (2013) reported that the mean values of cross sectional area of the PCL at tibial attachment were 110.7 mm. Several authors studied ACL and PCL as separate bundles that are AM and PL bundles in ACL, AL and PM bundles in PCL, but the present research work has evaluated whole ACL and PCL as one entity.

Present study has its limitations; we are not analysing the bundles of cruciate ligaments separately, it is not easy to evaluate the separate bundles in formalin fixed cadavers, even though some authors has studied separate bundles of ACL and PCL in cadaveric study, we are not sure about the accuracy of the results.

Conclusion

The present study contributes to the morphometric data on cruciate ligaments of knee joint by means of gender differences. The morphometric data of cruciate ligaments plays a crucial role in selecting the quantity of graft for surgical repair of damaged ligaments. During the surgical reconstruction of cruciate ligaments individually either in male or female, it is very essential to know the mean morphometric differences between males and females.

References

1. Standring S, editor. Gray's anatomy: the anatomical basis of clinical practice. 3.

- Edinburgh: Elsevier Churchill Livingstone; 2005: 1461.
2. Arnoczky SP. Anatomy of the anterior cruciate ligament. *Clin OrthopRelat Res* 1983; (172):19-25.
 3. Girgis FG, Marshall JL, Monajem A. The cruciate ligaments of the knee joint. Anatomical, functional and experimental analysis, *ClinOrthop*.1975; 106: 216-31.
 4. Iriuchishima T, Ingham SJ, Tajima G, *et al*. Evaluation of the tunnel placement in the anatomical double-bundle ACL reconstruction: A cadaver study. *Knee Surg Sports Traumatol Arthrosc* 2010; 18: 1226-1231.
 5. Beasley L, Weiland D, Vidal A, Chhabra A, Herzka A, Feng M, West R. Anterior cruciate ligament reconstruction: A literature review of the anatomy, biomechanics, surgical considerations, and clinical outcomes. *Operative Techniques in Orthopaedics*. 2005; 15(1): 5-19.
 6. Amis AA, Gupte CM, Bull AM, Edwards A. Anatomy of the posterior cruciate ligament and the meniscomfemoral ligaments. *Knee Surg Sports TraumatolArthrosc*. 2006;14(3):257-63.
 7. Saddler SC, Noyes FR, Grood ES, Knochenmuss DR, Hefzy MS. Posterior cruciate ligament anatomy and lengthtensionbehavior of PCL surface fibers. *Am J Knee Surg*. 1996;9(4):194-99.
 8. Amis AA, Jakob RP. Anterior cruciate ligament graft positioning, tensioning and twisting. *Knee Surg Sports Traumatol Arthrosc* 1998; 6 (suppl 1):S2-S12.
 9. Indelli PF, Dillingham MF, Fanton GS. Anterior cruciate ligament reconstruction using cryo preserved allografts. *ClinOrthop*. 2004; 420: 268-75.
 10. Beynonn BD, Johnson RJ, Fleming BC, *et al*. Anterior cruciate ligament replacement: Comparison of bonepatellar tendon-bone grafts with two-strand hamstring grafts. A prospective, randomized study. *J Bone Joint Surg Am* 2002; 84: 1503-1513.
 11. Barrett, GR, Boojin FK, Hartzog CW, Nash CR. Reconstruction of the anterior cruciate ligament in females: A comparison of hamstring versus patellar tendon autograft. *Arthroscopy: Journal of Arthroscopic and Related Surgery*. 2002; 18: 46-54.
 12. Siebold R, Ellert T, Metz S, Metz J. Femoral insertions of the anteromedial and posterolateral bundles of the anterior cruciate ligament: Morphometry and arthroscopic orientation models for double-bundle bone tunnel placement A cadaver study. *Arthroscopy* 2008; 24:585-592.
 13. Anderson AF, Anderson CN, Gorman TM, Cross MB, Spindler KP. Radiographic measurements of the intercondylar notch: Are they accurate. *Arthroscopy* 2007; 23(3): 261-8
 14. Odensten M, Gillquist J. Functional anatomy of the anterior cruciate ligament and a rationale for reconstruction. *J Bone Joint Surg (Am)* 1985; 67(2): 257-62.
 15. Gillquist J. Drill hole reproducibility in ACL reconstruction. *Sports Med Arthrosc* 1996; 4:342-9.
 16. Harner CD, Giffin R, Dunteman RC, Annunziata CC, Friedman MJ. Evaluation and treatment of recurrent instability after ACL reconstruction. *J Bone Joint Surg Am* 2000; 8 (2): 1652- 64
 17. EleniTriantafyllidi, Nikolaos K. Paschos, Anna Goussia, Nektaria-MarianthiBarkoula, Dimitrios A. Exarchos, B.S., Theodore E. Matikas, VassilikiMalamou-Mitsi, and Anastasios D. Georgoulis. The Shape and the Thickness of the Anterior Cruciate Ligament along Its Length in Relation to the Posterior Cruciate Ligament: A Cadaveric Study. *Arthroscopy: The Journal of Arthroscopic and Related Surgery*, 2013;29(12): 1963-1973.
 18. Beynonn BD, Johnson RJ, Fleming BC. Anterior cruciate ligament replacement: Comparison of bonepatellar tendon-bone grafts with two-strand hamstring grafts. A prospective randomized study. *J Bone Joint Surg Am* 2002; 84:1503-1513.
 19. Siebold R, Ellert T, Metz S, Metz J. Femoral insertions of the anteromedial and posterolateral bundles of the anterior cruciate ligament: Morphometry and arthroscopic orientation models for double-bundle bone tunnel placement A cadaver study. *Arthroscopy* 2008; 24:585-592.
 20. Mochizuki T, Fujishiro H, Nimura A, *et al*. Anatomic and histologic analysis of the mid-substance and fan-like extension fibres of the anterior cruciate ligament during knee motion, with special reference to the femoral attachment. *Knee Surg Sports Traumatol Arthrosc*. January 24, 2013.
 21. Takahashi M, Matsubara T, Doi M, Suzuki D, Nagano A. Anatomical study of the femoral and tibial insertions of the anterolateral and posteromedial bundles of human posterior cruciate ligament. *Knee Surg Sports Traumatol Arthrosc*. 2006; 14(11):1055-9.
 22. Lopes OV, Ferretti M, Shen W, Ekdahl M, Smolinski P. Topography of the femoral attachment of the posterior cruciate ligament. *J. Bone Joint Surg Am*. 2008; 90(2):249-55.
 23. Cury RPL, Severino NR, Camargo OPA, Aihara T, Batista Neto LV, Goarayeb DN. Estudo anatomico da insercao femoral do ligamento cruzado posterior. *Rev Bras Ortop*. 2011; 46(5):591-5.
 24. Dargel J, Pohl P, Tzikaras P, Koebeke J. Morphometric side-to side differences in human cruciate ligament insertions. *Surg Radiol Anat*. 2006; 28(4):398-402.

Source of Support: NIL

Conflict of Interest: None