

## Management of advanced stages of Osteonecrosis of the Jaws due to Bisphosphonates: Report of two cases

Amminou Loubna<sup>1\*</sup>, Chbicheb Saliha<sup>2</sup>, El Wady Wafaa<sup>3</sup>

<sup>1</sup>Resident in the department of oral surgery, Dental Center of treatment and Diagnosis (Ibn Sina Hospital), Rabat, Morocco

<sup>2</sup>Professor of oral surgery, Faculty of Dentistry of Rabat, Mohammed V University Morocco

<sup>3</sup>Professor and head of the oral surgery service, Faculty of Dentistry of Rabat, Mohammed V University, Morocco

Received: 16-06-2017 / Revised: 28-06-2017 / Accepted: 05-07-2017

### ABSTRACT

Bisphosphonates are a class of drugs used to strengthen bone. They are indicated in the treatment of osteoporosis and Paget's disease as well as malignant pathologies such as breast cancer, bone metastases. The examples of medications bisphosphonates includes Aledronate, Ibandronate, Incadronate, Olpadronate, Pamidronate, Risedronate, and Zoledronate. One of the most important complications of bisphosphonates is osteonecrosis of the jaws which alters the quality of life of the patient and is all the more difficult to manage as osteonecrosis is advanced. This paper describes two cases of advanced osteonecrosis whose management was very difficult leading to a recurrence of this complication.

**Keywords:** Bisphosphonates, Multiple myeloma, Breast cancer, Osteonecrosis, Jaws

### Introduction

Osteonecrosis of the jaws associated with bisphosphonate therapy, has been identified and defined as a pathological entity since 2003 [8]. The definitive symptom of Osteonecrosis of the jaws is the exposure of mandibular or maxillary bone through lesions in the gingiva that do not heal. Pain, inflammation of the surrounding soft tissue, secondary infection or drainage may or may not be present [10]. The development of lesions is most frequent after invasive dental procedures, such as extractions, and is also known to occur spontaneously. There may be no symptoms for weeks or months, until lesions with exposed bone appear [10]. The recommended treatment for this osteonecrosis is essentially symptomatic and conservative [6, 10]. However, in advanced cases, the treatment seems more complicated and the resolution of the problem is inconclusive.

\*Correspondence

#### Amminou Loubna

Resident in the department of oral surgery, Dental Center of treatment and Diagnosis (Ibn Sina Hospital), Rabat, Morocco

E Mail: [loubnamminou@gmail.com](mailto:loubnamminou@gmail.com)

### Clinical Observation

#### Case report n°1

Mister A.L, 62-year-old, consulted in the service (department) in September 2007 for pains and delay of gingival healing after maxillo-mandibular multiple dental extractions realized on 1 year previously. On general examination, the patient showed that it had a multiple myeloma with IgG of IIIa stage, treated since May 2000 by radiotherapy, chemotherapy (Melphlan), Dexamethasone, 5 monthly cures of Pamidronate then 13 monthly cures of Acid Zoledronic. In September 2006, 46, 47 and 48 were extracted because of a mandibular pain on posterior right side which was followed by a mandibular tumefaction, painful and infected, at the site of extractions and not yielding to the antiseptic and antibiotic treatment. Extraorally, there was a cutaneous fistula facing the osteitis focus which drained a purulent exudate associated with a hard swelling and painful in the right side with a homolateral labio-chin hypoesthesia (fig 1). Intraoral examination revealed the absence of 18, 17, 16, 15, 24, 25, 27, 28, 44, 45, 46, 47 and 48 and two mucous ulcerations with osseous exposure interesting the

jawbone and the mandible in the right posterior area (fig 2).

The radiological assessment (panoramic x-ray and CT of the facial mass) showed a loss of osseous substance with pathological mandibular fracture (fig 3), which justified the realization of surgical debridement under general anesthesia associated with reconstruction by an osteosynthesis plate.

The histopathological examination revealed an osteitis colonized by *Actinomyces* without signs of malignity. An antiseptic treatment and antibiotic by amoxicilline were prescribed during 50 days. After 4 months, the panoramic radiography showed the persistence of the mandibular osteitis.

Consequently, in May 2007, a second surgical debridement with removal of the mini-plate of osteosynthesis was made.

The microscopic examination specified that it was an osteonecrosis without histological sign of malignity.

An antiseptic treatment, an antibiotic (quinolone/métronidazole) and a hyperbaric oxygen therapy (20 sessions) were made.

Radiological control, one month after, showed a loss of osseous substance extended in the right posterior mandibular area and a good bone healing in the maxillary. The patient died in December 2007 of a severe pulmonary attack, secondary to his myeloma.

### Case report n°2

A 45-year-old female presented to the Department of Oral surgery for pains and a left swelling in her cheek.

On general examination, the patient reports that she has a breast cancer treated with intravenous bisphosphonates Zoledronate "ZOMETA" for three years. The patient added that she developed a femoral metastasis. Three months ago she performed an extrusion of a premolar which was followed by a swelling at the site of extraction, pain and lack of healing. An antibiotic by amoxicilline and metronidazole treatment was introduced without success. The situation continued for a three month period before referral to our department. Extraorally there was a facial asymmetry due to a swelling with tender left submandibular lymphadenopathy (fig 4).

Intra-orally, the presence of a non-healing extraction site 35 with inflamed gingival tissue and necrotic bone was noted (fig 5).

The radiological assessment (Panoramic x ray and CT of the facial mass) discovered an osteolysis extended in the left posterior area of the horizontal branch.

A surgical debridement consisted of a curettage of soft bone in the premolar region was performed and soft

tissue closure again attempted. A long-term antibiotic regime was prescribed (Amoxicilline during one month).

A histological report demonstrates necrotic bone. The surgery allowed to temporarily control the symptoms, a recurrence was noted after a few weeks. The choice of a conservative surgery was decided following the patient's deteriorated health. The patient died of the complications of her initial illness.

### Discussion

Bisphosphonates are structural analogues of inorganic pyrophosphates, having a big affinity for the bone by being bound strongly in the hydroxyapatite [1].

Bisphosphonates are indicated in skeletal disorders, such as bone metastases, myeloma, osteoporosis, paget disease, and bone pain.

Those that contain nitrogen (N-BPs) are the most potent ones and are represented by Aledronate, Ibandronate, Incadronate, Olpadronate, Pamidronate, Risedronate, and Zoledronate. Whereas the non-N-BPs are mainly Clodronate, Etidronate, and Tiludronate [2].

Maxillary osteonecrosis due to bisphosphonates is defined by the presence of exposed bone in the maxillofacial region which persists for at least eight weeks in patients on bisphosphonates with no history of local radiotherapy or maxillary metastases [3].

This complication is found, most commonly, in patients with Multiple myeloma, aged 61 years Average, white race. It sits with predilection in the posterior mandibular region [4, 1]

The physiopathogenesis of osteonecrosis of the jaws is not clearly understood [3]. The most accepted theory is that exposed bone is the result of a disruption of the osteoblast-osteoclast homeostatic cycle due to Bisphosphonates [1,2]. This has the effect of disturbing the osteoclastic functions, which interrupts the normal turn-up, inducing an old bone that is not eliminated with excessive mineralization of the bone weave [5].

Several risk factors such as treatments using Pamidronate or Zoledronic acide , tooth extraction, the patient's advanced age at the time of diagnosis , the dose and duration of exposure to bisphosphonates greater than 2.5 years increase the risk of developing osteonecrosis of the jaws [4,5,6,7]. Other treatments, namely chemotherapy and corticosteroids, could also play a role in the development of these osteonecrosis [7].

The clinical signs of osteonecrosis of the maxilla depend on the stage of the disease. Osteonecrosis of the

maxilla can be asymptomatic or present as an unexplained discomfort with frustrated objective signs affecting the quality of life of the patient [8].

These clinical signs can be more important ranging from the mobility of teeth, pain or neurosensory changes (paraesthesia) to infectious signs (cellulitis, extra-oral fistula) [8].

Routine radiographic evaluation for hard tissue radiolucencies may indicate the onset of early stage osteonecrosis of the jaws. Radiopaque changes associated with the lamina dura may also indicate continued osteoblastic activity without osteoclastic resorption [9]. This radiological aspect is non-specific and should be differentiated from chronic osteomyelitis, infected osteoradionecrosis, primary bone tumor pathology (myeloma), metastasis and a pathological fracture of the maxilla [3].

Histopathological examination shows bone necrosis associated with bacterial infection and granulation tissue. The diagnosis of actinomycosis must be correlated with the results of the bacterial culture. In some cases, if a tumor bone metastasis is suspected, a bone biopsy should be performed [3]. Currently, the treatment recommended for osteonecrosis is essentially symptomatic and conservative. It consists of making antiseptic oral rinses (aqueous chlorhexidine 0.1%), antibiotic therapy in case of local infection, abscess or fistulization and surgical debridement treatment of the necrotic bone with elimination of mobile osseous sequesters [2, 3, 8]. In some cases of extensive osteonecrosis, only aggressive treatment (interrupted resection of the mandible) makes it possible to obtain the resolution of the pain and the acute infection [3].

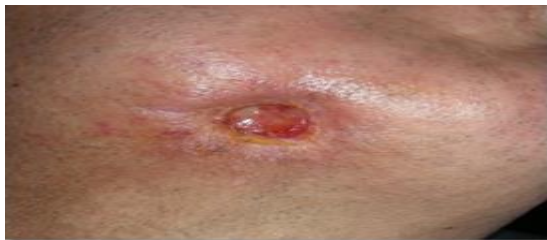According to Ruggiero and Marx [3,10] a segmental resection associated with immediate reconstruction by

an osteosynthesis plate is necessary during a pathological mandibular fracture.

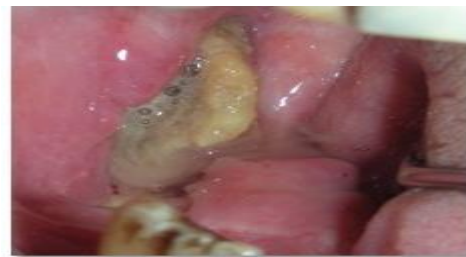On the other hand, mandibular reconstruction immediately with a bone graft vascularized or not cannot be considered because there is a risk of bone necrosis on the site because of the systemic effect of bisphosphonates [3]. Hyperbaric oxygen administration seems to be helpful in this direction, especially for major mandibular defects, but it is needed to be clarified by with sufficient data [2]. The discontinuity of bisphosphonate therapy does not seem to be justified because of their long bone half-life [3]. However, Magopoulos et al [2], suggested that the cessation of bisphosphonate therapy for more than 6 months followed by debridement/sequestration of the defect with concomitant antibiotics administration resulted in complete wound healing in several cases [2]. Elective dento-alveolar surgical procedures such as extractions, dental implants or endodontic surgery, should be avoided because they may promote the development of osteonecrosis [3].

### Conclusion

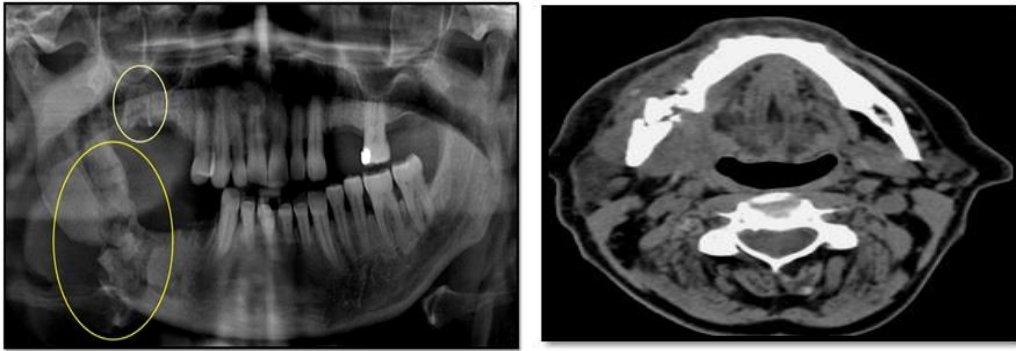
The management of these patients with bisphosphonate induced osteonecrosis of the jaws is quite challenging [2]. The major goal of treatment for patients who have osteonecrosis of the jaws is preservation of quality of life through: patient education and reassurance, control of pain, control of secondary infection and prevention of extension of lesion and development of new areas of necrosis [8]. However, in advanced cases, management of this complication is difficult and the recidivism is inevitable [8].



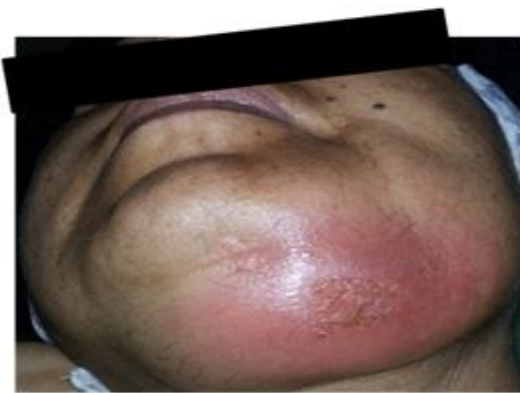**Fig 1: Cutaneous fistula in the right submandibular region**



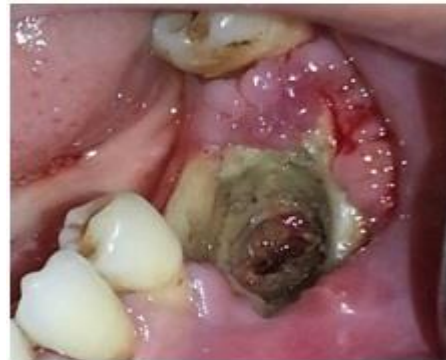**Fig 2 : Necrosis and bone infection**



**Fig 3 : Pre-operative X- Ray (3a: Dental panoramic, 3b: CT axial)**



**Fig 4 : Low cellulitis in relation with osteonecrosis**



**Fig 5 : Osteonecrosis focus in the left lower premolar region**

## References

1. Cameron Y. S. Lee, David T, Nishime M. Use of platelet-rich plasma in the management of oral bisphosphonate associated osteonecrosis of the jaws: A report of 2 cases. *Journal of Oral Implantology* 2007; 33(6) :371-382
2. Magapoulou C, Karakinaris G, Telouidis Z. Osteonecrosis of the jaws due to bisphosphonate use. A review of 60 cases and treatment proposals. *American Journal of Otolaryngology-Head and Neck Medicine and Surgery* 2007; 28: 158-163
3. Ruggiero S L, Fantasia J, Carlson E. Bisphosphonate-related osteonecrosis of the jaw: background and guidelines for diagnosis, staging and management. *Oral Surg Oral Med Oral Pathol Oral Radiol Endod* 2006 ;102 : 433-41.
4. Bamias A, Kastritis E, Bamia C. Osteonecrosis of the jaw in cancer after treatment with bisphosphonates: incidence and risk factors. *J Clin Oncol* 2005 ; 23 :8580-7.
5. Marx R E. Oral and Intravenous Biphosphoate-Induced Osteonecrosis of the Jaws. 2nd ed. Quintes Pub, 2011
6. Badros A, Weikel D, Salama A, Goloubeva O, Schneider A, Rapoport A, Fenton R, Gahres N, Sausville E, Ord R, Meiller T. Osteonecrosis of the jaw in multiple myeloma patients: clinical features and risk factors. *J Clin Oncol* 2006 ; 24 : 945-52.
7. Boonyapakorn T, Schirmer I, Reichart PA, Sturm I, Massenkei G. Bisphosphonate-induced osteonecrosis of the jaws: prospective study of 80 patients with multiple myeloma and other malignancies. *Oral Oncol* 2008 ; 44 : 857-69.
8. Ruggiero S, Dodson T, Fantasia T. Medication related osteonecrosis of the jaws- update 2014. American Association of oral and maxillofacial

- 
- surgeons: position paper on medication related osteonecrosis of the jaws- update 2014. *J Oral Maxillofac Surg.* 2014;72(10):1938-56.
9. Hinchy N, Jayaprakash V, Rossitto R, Anders P. Osteonecrosis of the jaws – prevention and treatment strategies of oral health professionals. *Oral Oncology* 2013 ; 49 : 878–886
10. Marx R, Sawatari Y, Fortin M, Brounmand V. Biphosphonate-induced exposed bone (osteonecrosis/osteopetrosis) of the jaws: risk factors, recognition, prevention, and treatment. *J Oral Maxillofac Surg* 2005; 63: 1567-75.

**Source of Support: Nil**

**Conflict of Interest: Nil**