

Variation in the formation, communication and distribution of median nerve: a cadaveric study**D.A.Patil* , A.S.Jadhav, C.V.Bhingardeve, A.S.Katti***Department of Anatomy, Government Medical College, Pandharpur Road, Miraj Dist.-Sangli, Maharashtra, India***ABSTRACT**

Introduction: The median nerve is formed by the union of lateral and medial root from the lateral and medial cords of brachial plexus respectively. Anatomical variations of the median nerve are very common. Reports on the existence of variations in the formation, branching and communication of median nerve are seen in the literature. **Materials and Methods:** The study was carried in the department of anatomy during undergraduate training on 20 formalin preserved adult cadavers which included 14 males and 6 females. In each cadaver the opposite upper limb was also dissected completely to exclude bilateral abnormality. Photographs of abnormalities were taken for proper documentation of the variations. **Observations and Results:** Unilateral anatomical variations of median nerve were observed in four cadavers. There was normal pattern of formation and course of median nerve in rest of the cadavers. **Conclusion:** Anatomical variations of median nerve are of great academic and clinical significance in orthopedics, surgery, anaesthesiology, sports medicine and physiotherapy. An attempt has been made to add the information of present study to the existing knowledge in the literature.

Key words : Brachial plexus , Lateral Root , Medial Root , Median Nerve**Introduction**

Median nerve is formed by union of two roots, lateral root and medial root coming from lateral and medial cord of brachial plexus respectively. These two roots embrace the third portion of the axillary artery joining each other anterior or lateral to it. The median nerve runs on the lateral side of brachial artery in the arm. Thereafter it crosses the brachial artery from front to reach the medial aspect and descend further in the arm. It enters cubital fossa as the medial most structure and descends down in the forearm to supply anterior compartment of forearm. It also supplies the nar muscles, first and second lumbricals, palmar aspect of hand and lateral three and a half of the digits including the distal portions of dorsum of these digits. Reports on the existence of variations in the formation, branching and communications of median nerve are seen in literature. Formation of median nerve by three [1-13],

very rarely by four [14] and five roots[15] has been reported by many authors and the communications between musculocutaneous and median nerve are also well documented[16-19]. Such variations of the median nerve regarding its formation and communication can potentially confuse the surgeon intervening in the axilla and arm region, as well as the anesthetist during axillary block anesthesia. The aim of this study was to analyze the anatomical variations in the number of roots of median nerve along with its branching pattern and communications.

Materials and methods

The study was carried in the department of anatomy during undergraduate training on 20 formalin preserved adult cadavers which included 14 males and 6 females. The upper limb was meticulously dissected to visualize variation in the formation, branching and communications of median nerve. In each cadaver the opposite upper limb was also dissected completely to exclude bilateral abnormality. Each observed variation

Correspondence*Dr. D A Patil**


Department Of Anatomy, Government Medical College, Pandharpur Road, Miraj Dist.-Sangli, Maharashtra, India

E Mail: deepak_bjmc2004@rediffmail.com

of the median nerve was identified, photographed and documented taking into account gender, level and side of the upper limb.

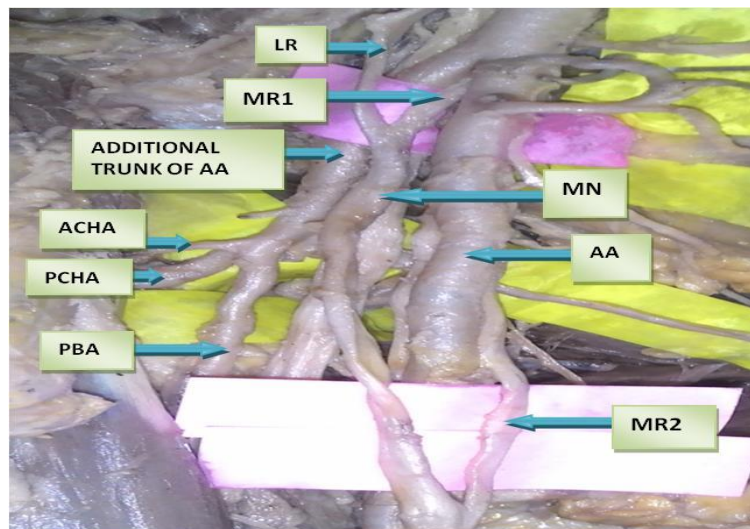
Observations and results

Unilateral variations were observed in the median nerve in four upper limbs. No variation was noted in the median nerve in the respective opposite limbs. Presence of three roots of median nerve was observed in two cadavers.



Photograph 1: Showing Additional Lateral Root And Communication Of Musculocutaneous Nerve With Median Nerve

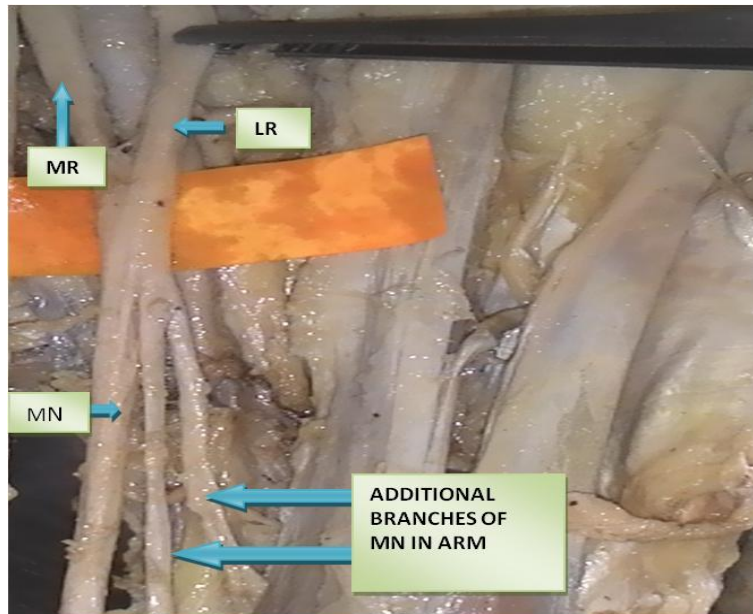
In the first case (Photograph 1), the variation was present on left side where the additional root was derived from lateral cord. This additional lateral root joined the median nerve in the axilla. In addition, we observed communication of musculocutaneous nerve with median nerve in this case.



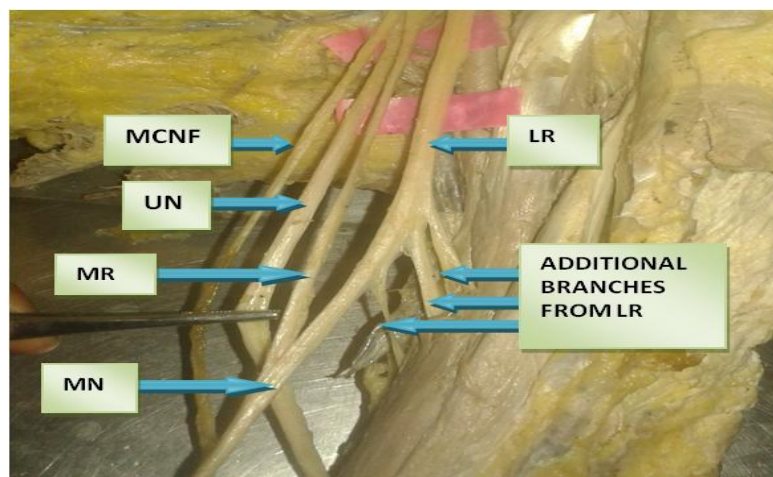
Photograph 2: Showing Additional Medial Root And Additional Trunk of Axillary Artery

In the second case (Photograph 2), the variation was present on the right side where the additional root was derived from the medial cord. This additional medial root joined the median nerve in the midarm region. In addition, we observed variation in the branching pattern of axillary artery in this case. There was an additional trunk originating from second part of

axillary artery. This additional trunk gave subscapular artery, anterior and posterior circumflex humeral artery (Branches of third part of axillary artery) and profunda brachii artery (Branch of brachial artery). Median nerve formation was present anterior to this trunk whereas the additional medial root joined the median nerve in midarm region anterior to brachial artery.



Photograph 3 : Additional Branches From Median Nerve



Photograph 4 : Additional Branches From Lateral Root Of Median Nerve.

Unusual innervation of flexor muscles of arm with absence of musculocutaneous nerve was observed on

left side in two cadavers. (Photograph 3,4) In the first case (Photograph 3), the additional branches were

given directly by the median nerve whereas in the second case (Photograph 4), they were derived from the lateral root of median nerve. Median nerve

formation in this case was present in the arm instead of axilla. Rest of the course and distribution of median nerve was normal in all these cadavers.

Legends to photographs

MN-MEDIAN NERVE
 MR- MEDIAL ROOT
 LR-LATERAL ROOT
 UN-ULNAR NERVE
 AA- AXILLARY ARTERY
 MCN-MUSCULOCUTANEOUS NERVE
 PBA-PROFUNDA BRACHII ARTERY
 MCNF-MEDIAL CUTANEOUS NERVE OF FOREARM
 ACHA- ANTERIOR CIRCUMFLEX HUMERAL ARTERY
 PCHA-POSTERIOR CIRCUMFLEX HUMERAL ARTERY

Discussion

Median nerve is one amongst the nerves that has been studied extensively and reported for different kinds of variations. Median nerve as reported in literature is associated with several variations which include additional roots taking part in formation, abnormal communications with other nerves such as musculocutaneous and ulnar nerves[16-19], splitting of the median nerve[7] and unusual innervations of flexor muscles of arm by the median nerve.[8,9]In the present study we looked for unusual formation of median nerve including additional roots taking part in formation, abnormal communications and unusual innervations of the median nerve and correlated it embryologically and clinically. Presence of three roots of median nerve which included **two lateral roots and one medial root** has been reported by many authors.[1-13]Pais, Casal, Santos et al.[9] reported median nerve formation by three roots where two roots came from lateral cord and

one from medial cord but **both the roots** coming from lateral cord **joined with medial root in the axilla**. Sontakke, Tarnekar, Waghmare et al.[10] described a case where median nerve was formed by three roots, two of them came from lateral cord and one from medial cord but the **first root** that arose from lateral cord **joined** the medial root **in the axilla** and the **second one joined** with the medial root **in the arm** to form the median nerve. The formation of median nerve from **one lateral root and two medial roots** from the medial cord of brachial plexus has been mentioned as well.[20]In the present study, we observed median nerve with three roots in **two cadavers (Photograph 1,2)**. In the first case, the additional third root came from the lateral cord and joined the median nerve in axilla whereas in the second case, it came from medial cord and joined the median nerve in the arm.

Table 1: Shows the incidence of median nerve with three roots in previous and present study

Study	Percentage
1. Eglseder and Goldman[2]	14 %
2. Valeria[5] et al	52 %
3. Dahiphale [21]et al	5%
4. Darji [11]et al	1 %
5. Present study	10 %

In the present study, we observed **communications** of median nerve with musculocutaneous nerve in one cadaver. (**Photograph 1**).

Table 2: Shows the incidence of communications between the median nerve and musculocutaneous nerve in previous and present study

Study	Percentage
1. Eglseder and Goldman[2]	36%
2. Venieratos and Anagnostopoulou[22]	21%
3. Asly Aktan[23]	11%
4. Dahiphale[21] et.al	25%
5. Darji[11]et.al	6%
6. Present Study	5%

According to Hollinshead, anomalies of nerves are accompanied by abnormalities of vessels [24]. The variations of brachial plexus were associated with variations of subclavian, axillary and brachial arteries[1]. In the present study, we observed variation in the branching pattern of axillary artery in one case (**Photograph 2**) where an additional trunk originated from second part of axillary artery. This additional trunk gave rise to subscapular artery, anterior and posterior circumflex humeral artery (branches of 3rd part of axillary artery) and profunda brachii artery (branch of brachial artery).

Embryological Basis

The upper limb muscles develop from mesenchyme of paraxial mesoderm in the fifth week of intrauterine life. The motor axons arrive at the base of limb bud; they mix to form brachial plexus in upper limb. The growth cones of axons continue in the limb bud[25]. As the guidance of the developing axons is regulated by the expression of chemo-attractants and chemo-repulsants in a highly coordinated site specific fashion any alterations in signalling between mesenchymal cells and neuronal growth cones can lead to significant variations[23].

Conclusion

The anatomical variations of median nerve have been highlighted within the context of their clinical significance. Normal functioning of the limbs may not be altered by these variations but it is important to remember these variations during performance of surgical procedures undertaken into the area of axilla and the arm. Knowledge of such variations in the formation of median nerve would be of considerable importance for anatomists, surgeons, anesthetists and clinicians, when they handle cases involving axillary artery or median nerve or both, owing to the close proximity of the additional roots of median nerve with the axillary artery. The median nerve with extra roots is more likely to be involved in entrapment syndromes.

So while performing orthopaedic and other surgical interventions it may lead to sensory, motor, vasomotor and trophic change. Furthermore, the awareness of the atypical formation and location of median nerve is critical for the anesthetist performing brachial plexus block.

References

1. Sargon MF, Uslu SS, Celik HH, Aksit D. A variation of the median nerve at the level of the brachial plexus, Bull Assoc Anat 1995; 79: 25-6.
2. Eglseder WA Jr, Goldman M. Anatomic variations of musculocutaneous nerve in the arm, Am J Orthop (Belle Mead NJ) 1997; 26: 777-780.
3. Chouhan R, Roy T.S. Communication between the median and musculocutaneous nerve - A case report, Journal of the Anatomical Society of India 2002; 51(1):72-75.
4. Saeed M, Rufai AA. Median and musculocutaneous nerves: Variant formation and distribution, Clinical Anatomy 2003; 16: 453-457.
5. Valeria Paula Sassoli Fazan, Andre de Souza Amadeu, Adilson L. Caleffi², Omar Andrade Rodrigues Filho³. Brachial plexus variations in its formation and main branches, Acta Cirurgica Brasileira 2003; 18 (Supl. 5).
6. Goyal N, Harjeet, Gupta M. Bilateral variant contributions in the formation of median nerve, Surg Radiol Anat 2005; 27: 562-565.
7. Pandey SK, Shukla VK. Anatomical variations of the cords of brachial plexus and the median nerve, Clin Anat 2007; 20: 150-156.
8. N.Satyanarayana, Reddy C.K, P.Sunitha, N.Jayasri, V.Nitin, G.Praveen, R.Guha, Datta A.K, Shaik M.M. Formation of median nerve by three roots: A case report, Journal of College of Medical Sciences-Nepal 2010; 6 (1): 47-50.
9. Pais D, Casal D, Santos A, O'Neill JG. A variation in the origin of median nerve associated

- with unusual origin of the deep brachial artery, Journal of morphological sciences 2010;27:35-38.
10. Sontakke BR, Tarnekar AM, Waghmare JE, Ingole IV. An unusual case of asymmetrical formation and distribution of median nerve, International Journal of Anatomical Variations 2011; 4:57-60.
 11. Darji Apurva, Chauhan Hitesh, Khatri Hardik, Aterkar Swati, Pensi C.A. Variations in branching pattern of brachial plexus : A cadaveric study, Int J Biomed Adv Res 2013 ; 4(3):174-178.
 12. Amrita Bharti , Vaishali Mohan Paranjpe , Makarand V Apte.Variations in the formation and relation of median nerve, Int J Anat Res 2015; 3(3):1298-01.
 13. Humberto Ferreira Arquez , Diana Katherine Arias Hurtado. An anatomical study of formation of the median nerve, Journal of Chemical and Pharmaceutical Research 2016; 8(5):22-26.
 14. Surekha Wamanrao Meshram , Kiran Janardhan Khobragade, Sudhir Vishnupant Pandit, Jyoti Suryabhan Jadhav . Four roots of median nerve and its surgical and clinical significance,International Journal of Anatomical Variations 2012; 5: 110-112.
 15. Konstantinos Natsis, George Paraskevas, Maria Tzika . Five Roots Pattern Of Median Nerve Formation, Acta Medica 2016; 59(1):26-28.
 16. Choi D,Rodriguez Niedenfuhr M, Vazquez T,Parkin I, Sanudo J.R. Patterns of connections between the musculocutaneous and median nerves in the axilla and arm,Clinical Anatomy 2002; 15: 11-17.
 17. Yang Z.X, Pho R.W, Kour A.K,Pereira B.P. The musculocutaneous nerve and its branches to the biceps and brachialis muscles, Journal of Hand Surgery 1995; 20A (4): 671-675.
 18. Chiarapattanakom P, Leechavengvongs S, Witoonchart K, Uerpairajkit C, Thuvasethakul P. Anatomy and internal topography of the musculocutaneous nerve: The nerves to the biceps and brachialis muscle, Journal of Hand Surgery 1998; 23A (2): 250-255.
 19. Abhaya A, Khanna J, Prakash R. Variation of the lateral cord of brachial plexus piercing coracobrachialis muscle, Journal of the Anatomical Society of India 2003; 52(2): 168-170.
 20. Paranjape V, Swamy PV, Mudey A. Variant median and absent musculocutaneous nerve, J Life Sci 2012; 4(2): 141-144.
 21. Dahiphale V.P, Porwal S.S, Joshi D.S. Variations in the infraclavicular part of brachial plexus - A dissection study, Anatomica Karnataka 2012; 6 (1): 62-65.
 22. Venieratos D, Anagnostopoulou S. Classification of communications between the musculocutaneous and median nerves, Clin Anat. 1998;11 (5): 327-31.
 23. Aktan Z, Oztunk L, Bilge O, Ozer M, Pinar Y. A cadaveric study of the anatomical variations of the brachial plexus nerves in the axillary region and arm, Turk J Med Sci 2001; 2:147-150.
 24. Hollinshead WH. Anatomy for surgeons. Philadelphia, Harper & Row 1982: 220-223.
 25. Moore KL, Persaud TVN. The muscular system. In: Moore KL, Persaud TVN, eds. The Development Human Clinically Oriented Embryology. 7th ed. Philadelphia: Elsevier Sciences 2003: 410-424.

Source of Support: Nil

Conflict of Interest: None