

Cytological evaluation of breast lesions: Can it still go the long way?**Wasim M. Khatib^{1*}, Vidya C. Aher², Rakesh B. Demde², Pankti M. Patel²**¹*Assistant Professor, Department of Pathology, Krishna Institute of Medical Sciences, Karad, Maharashtra, India*²*Assistant Lecturer, Department of Pathology, Krishna Institute of Medical Sciences, Karad, Maharashtra, India***ABSTRACT**

Background: Breast lesions are a common occurrence in women of all age groups. Geographically, the occurrence of non-neoplastic and neoplastic lesions varies. The accurate diagnosis of individual cases has garnered importance over the years owing to a steep rise in neoplastic occurrences. Fine needle aspiration cytology (FNAC) has been a useful component in the diagnostic panel of palpable breast lesions. **Materials & Method:** Present work was carried out in the department of pathology, of a tertiary rural care hospital, over a period of one year from January 2015 to December 2015. FNAC was performed on all the patients presenting with palpable breast lesions. Smears were prepared and studied under light microscopy under clinical and radiological guidance. All the data was then studied and analyzed. **Results:** FNAC was performed on 171 cases. Cytologically, we categorized all the lesions as infectious/ inflammatory with 19 (11.11%), benign 76(44.44%), suspicious for malignancy 04 (2.33%), malignant with 62 (36.25%) and 09 (5.26%) unsatisfactory cases. Mean age of presentation was 45.5 years with left breast being more commonly involved. Histopathological correlation was possible in 111 (64.91%) cases. High sensitivity and specificity was observed. **Conclusion:** FNAC still remains a reliable, cost-effective, patient friendly and minimally invasive method. The application of FNAC as a diagnostic modality in palpable breast lesions should be all the more encouraged in routine practice.

Key words: Breast, Malignancy, FNAC**Introduction**

Lesions in the breast are not an uncommon occurrence in women throughout the world. FNAC for quite some time has been one of component of the 'triple test' that is employed in diagnosis of all breast lesions and exclusively malignancies [1]. Although, majority of the breast lumps prove to be benign, there is a definite rise in premalignant and malignant lesions [2]. Being a simple, minimally invasive and quick investigation, FNAC has reserved a place as a reliable diagnostic modality for palpable breast lesions. Next to cervical cancer, breast malignancies are second most common malignancies amongst females in India[3]. Core needle biopsy is being increasingly used now-a-days. However, high cost, long processing period and other disadvantages such as possibility of tumor seeding,

haematoma formation and localized pain cannot be over looked[4-5]. FNAC is a minimally invasive, patient friendly procedure with turnaround time of less than a day with almost no complications [6] . Apart from frank malignancies FNAC can diagnose an array of lesions like atypical lesions, benign lesions such as fibroadenoma, phyllodes and cystic lesions such as galactocele and fibrocystic disease. A proper diagnosis of cytology can definitely avoid unnecessary surgeries and provide better health care.

Materials & method

Present work was carried out in the department of pathology, of a tertiary rural care hospital, over a period of a year from January 2015 to December 2015. This study is a descriptive, cross-sectional and analytical type of study. FNAC was performed on all the patients with palpable breast lumps using a 22-23 gauge needle, 2-3 passes were performed and material was smeared on clean glass slides. Half of the slides were air dried and stained with Leishman stain while other half of slides were wet fixed with cytofixative

Correspondence*Dr. Wasim M. Khatib**

Assistant Professor, Department of Pathology, Krishna Institute of Medical Sciences, Karad, Maharashtra, India

E Mail: khatibwasim@gmail.com

(50% Ether and Ethyl alcohol mixture) and stained with routine Haematoxylin and Eosin (H&E). After processing, slides were examined under light microscopy. The final diagnosis was given after considering the clinical history and radiological investigation. All the breast lesions were then classified as inflammatory, infectious, cystic lesions, epithelial proliferative lesion with and without atypia, suspicious and malignancy. Histopathological correlation was done in 111 cases. Sensitivity, specificity, positive and negative predictive values were calculated.

Results

We performed FNAC on 171 patients with breast lumps. As expected, majority 168 (98.64%) were females and 03 (1.57%) were males. Most common age group affected among all cases was 41-50 years with 37 (21.63%) cases and mean age of presentation being 45.4 years.[Figure 1]. Left side lesions were most frequently encountered with 99 (57.89%) cases and right breast was affected in 69 (43.05%) cases. We had 03 (1.75%) cases of bilateral breast involvement.[Figure 2] Upper outer quadrant was most commonly affected with 73 (42.69%) cases followed by upper inner quadrant with 41 (23.97%) cases. 11 (6.43%) subareolar masses were observed. Lower breast was involved in 44 (25.73%) cases. All four quadrants were involved in 04 (2.33%) cases. [Figure 3]. Patients presented with varied signs and symptoms. Patients presented with lump in breast with or without associated symptoms. Lump with pain was the most common symptom seen in 95 (55.55%) cases. 02 (1.16%) cases presented with peau-d-orange which were found to be malignant. Bloody discharge was

noted in 03 (2.33%) cases. In the present study, out of 171 cases, 139 (81.28%) cases were epithelial proliferative lesions which included those with atypia and without atypia, fibrocystic disease (FCC) and malignancies. We came across 12 (7.01%) cases of acute suppurative mastitis with mean age of presentation of 48.4 years, 02 (1.16%) cases of lymphocytic mastitis and 04 (2.33%) cases of granulomatous mastitis (GM). Two of the GM showed foreign body type reaction whereas other two were idiopathic. We had 01 (0.58%) case of galactocele in a young female. We had 02(1.16%) male patients who presented with complaints of vague mass in the breast. They were diagnosed as gynecomastia. Epithelial proliferative lesion without atypia was noted in 46 (26.90%) cases. Epithelial proliferative lesion with atypia was noted in 14 (8.18%) cases. Among the cystic lesions, 07 (4.09%) cases of fibrocystic disease were noted. 04 (2.33%) cases showed mild cellular atypia, loosely held clusters and sheets and one cell population. However criteria for malignancy could not be fulfilled, hence, these patients were categorized as suspicious for malignancy.[Table 1] Amongst all the lesions, in contrast to many studies, we came across 62 (36.25%) cases of positive for malignancy.[Table 1]. Mean age of presentation among epithelial proliferative lesion without atypia, with atypia and malignancies were 25.9 years, 42.9 years and 55.1 years respectively. Of the 171 cases, histopathological correlation was possible in 111 cases. Of the 62 cases diagnosed positive cytologically, one case came back as negative on histopathological examination. On statistical analysis, our study revealed a high sensitivity and specificity of 96.82% and 95.91%, respectively. A positive predictive value of 98.38% was noted.

Table 1: Distribution according to diagnosis

Diagnosis	No. of cases	Percentage
Acute suppurative inflammation	12	7.01
Lymphocytic inflammation	02	1.16
Granulomatous mastitis[GM]	04	2.33
Galactocele	01	0.58
Gynecomastia	02	1.16
Lipoma	07	4.09
Epithelial proliferative lesion without atypia[EPL]	46	26.90
Epithelial proliferative lesion with atypia[EPLA]	14	8.18
Fibrocystic disease[FCC]	07	4.09
Phyllodes	01	0.58
Suspicious for malignancy	04	2.33
Positive for malignancy	62	36.25

Unsatisfactory	09	5.26
Total	171	

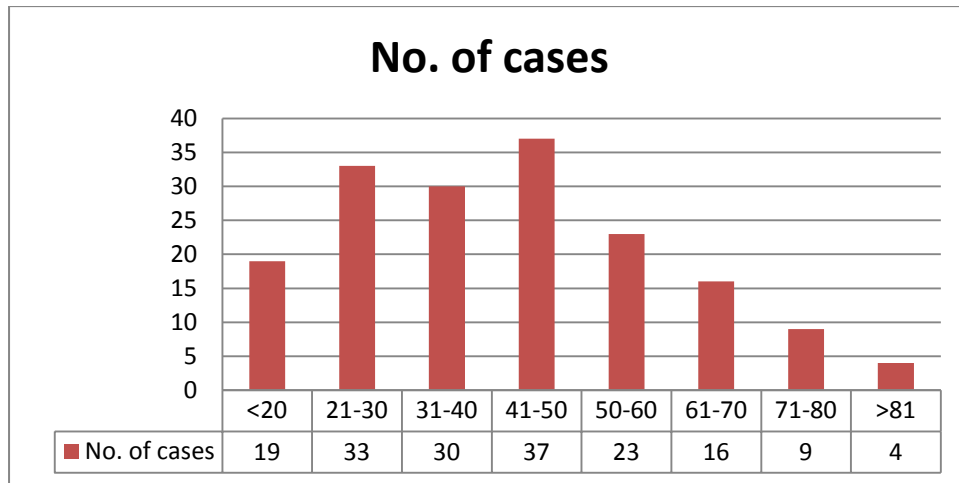


Fig 1: Distribution according to age group affected

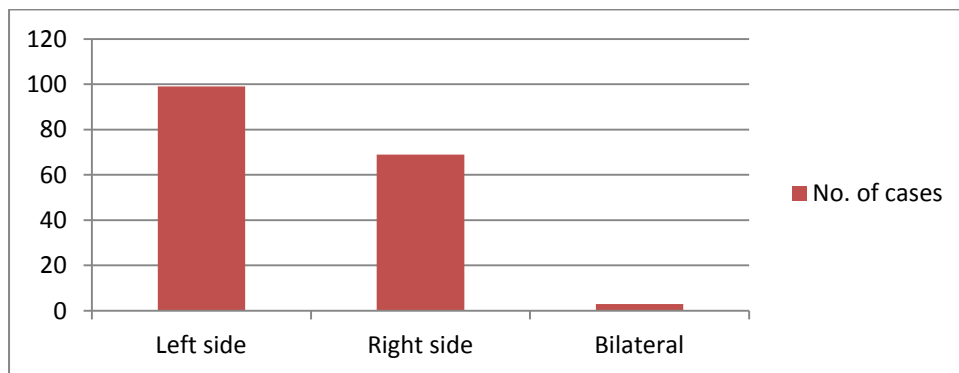


Fig 2: Distribution according to Laterality

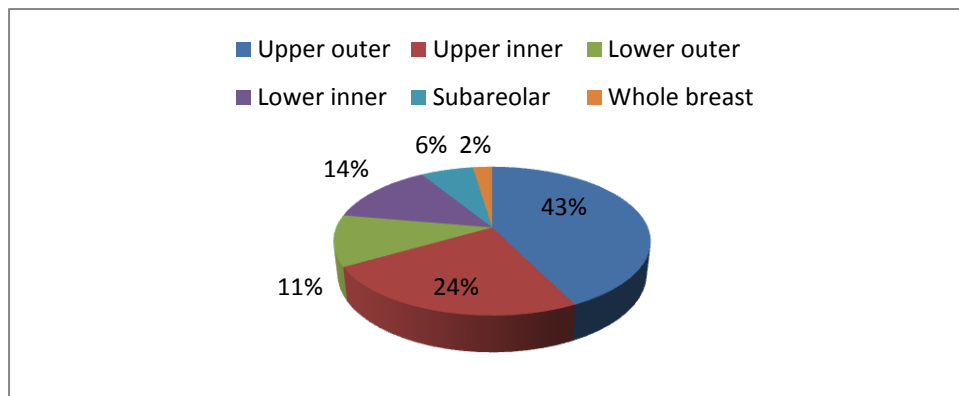


Fig 3: Quadrant wise distribution

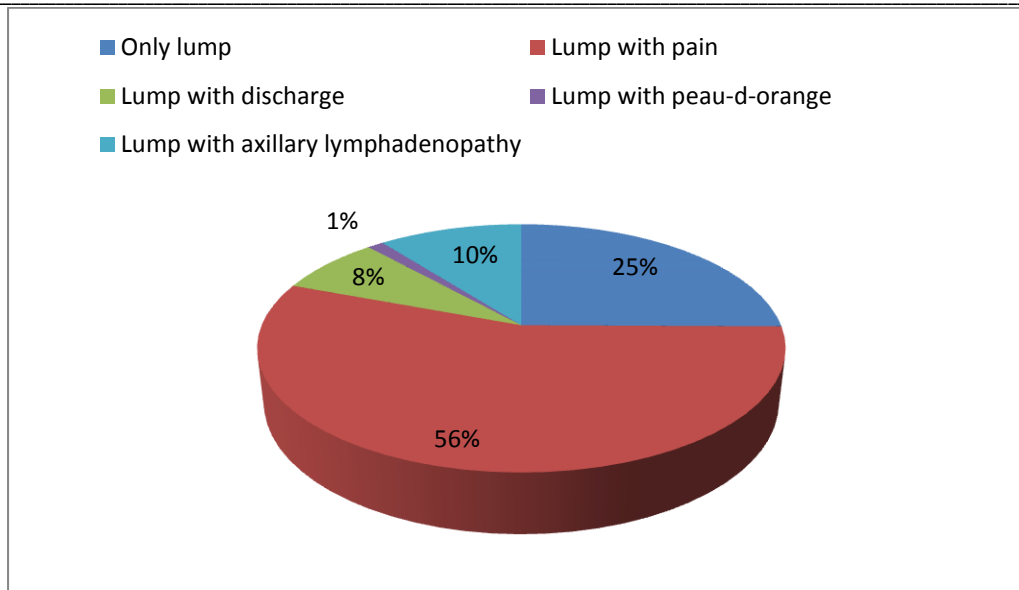


Fig 4: Distribution according to clinical presentation

Table 2: Age wise distribution in epithelial proliferative and neoplastic lesion

Age	EPL	EPLA	Phyllodes	Lipoma	Gynecomastia	FCC	Suspicious	Positive
<20	16	01	-	-	-	-	-	-
21-30	14	04	01	02	1	-	-	02
31-40	10	02	-	03	-	03	01	06
41-50	03	02	-	02	01	01	02	19
51-60	-	01	-	-	-	02	01	18
61-70	02	03	-	-	-	-	-	09
71-80	01	-	-	-	-	01	-	05
>81	-	01	-	-	-	-	-	03
Total	46	14	01	07	02	07	04	62

Table 3: Age wise distribution in inflammatory and infectious breast lesions

Age	Acute mastitis	Lymphocytic mastitis	Granulomatous mastitis	Galactocele
<20	01	-	-	-
21-30	02	01	03	01
31-40	03	01	01	-
41-50	05	-	-	-
51-60	-	-	-	-
61-70	01	-	-	-
71-80	-	-	-	-
>81	-	-	-	-
Total	12	02	04	01

Discussion

Martin and Ellis in 1930, first introduced FNAC of palpable breast lesions.[7] Ever since, it has proved to

be an important tool in the diagnosis of palpable breast masses. Given the location and morbidity associated

with them, breast lesions are a known cause for immense anxiety among females. Among the various lesions that can occur, pre-malignant and/or malignant lumps specifically are a cause of concern for the patients or treating physicians. In this era of improved technologies and increasingly applied non-invasive diagnostic modalities, FNAC though being minimally invasive, it is still preferred in the diagnostic panel of palpable breast lumps. Much has been said regarding the accuracy and efficacy of this procedure, to the extent of decommissioning it as a diagnostic test. However, we at our institute are of the opinion that FNAC still holds true as a reliable diagnostic arm in palpable breast lesions. We performed 171 FNAC procedures in our study, of which histopathological correlation was possible in 111 cases. Majority of the patients were females with 168 (91.64%) cases whereas 03 (1.75%) cases were males. The most common age group affected was 41-50 years with mean age of presentation of 45.4 years. [Table 2, 3] Our study was in concordance with one done by Khan et al, who also showed the same age group to be affected most commonly[8]. Other studies have reported the mean age of presentation as 34 years, 32 years, 59.3 years.[9, 10, 11] Benign lesions had an age range of 18-53 years. The mean age of presentation of epithelial proliferative lesion without atypia was 25.9 years. All the malignant cases had an age range from 28-83 years with most common age group affected being 51-60 years seen in 18 (10.52%) cases.[Table 2] Mean age of presentation among malignant lesions was 55.1 years. Khemka et al showed, benign lesions occurred mostly in the 30-34 years age group.[12] Ganiat et al reported most of the malignant lesions in an older age group i.e. 4th - 7th decade[13]. The left breast was most commonly affected in our study with 99 (57.89%) cases and right breast was affected in 69 (40.35%) cases. Of all the quadrants, the upper outer quadrant, with 73 (42.69%) cases, was found to be the most frequently affected. Our findings were in agreement with studies done by Hussain et al and Khemka et al[12, 14].

In our study, breast lump with pain was the most common presentation with 95 (55.55%) cases. Of the 171 aspirates, 09 (5.26%) were unsatisfactory. A study done by Nguansangiam et al, found the rate of unsatisfactory smears to be 4.20 %.[15] Improper technique is the most common cause of unsatisfactory smears, which was the case in our study.

We classified the cases as inflammatory with 16 (9.35%) cases, benign with 64 (37.42%) cases, Epithelial proliferative lesion with atypia in 14 (8.18%) cases, suspicious for malignancy 04 (2.33%) cases and malignancy 62 (36.25%) cases. Among the benign

lesions, fibroadenoma was the most common lesion to be observed with 46 (26.90%) cases. Aslam et al showed similar results[16]. We had 62 (36.25%) cases of ductal carcinoma of breast, in which 02 were in males. Singh et al reported invasive ductal carcinoma as the most common breast malignancy[17]. Among all the lesions, our study showed a greater prevalence of malignancies. This in itself is an unfortunate finding as it depicts a steady rise in breast malignancies and its pre-malignant conditions. A single case which was given positive cytologically, came back as atypical ductal hyperplasia histopathologically giving a false positive result. Our study showed a sensitivity and specificity of 96.82% and 95.91% respectively. Positive predictive value was found to be 98.38%. Panjvani et al observed a sensitivity of 97.82% and specificity of 100%[7]. Owing to the rise in pre-malignant and malignant lesions more so in rural areas as seen in our study, there is a need for quick and reliable diagnostic investigations which will help in reducing the number of the patients lost to follow-up. Though, core needle biopsy is a better investigation in terms of tissue diagnosis, FNAC has proved to give confident diagnoses along with its advantage of being economical and having a low tumor seeding incidence of 0.0045%[18].

Conclusion

FNAC is a reliable, cost-effective, patient friendly and a quick diagnostic modality especially when employed for breast lesions. As observed in our study, a wide range of lesion can be diagnosed with good accuracy if performed by an experienced hand. Tissue diagnosis is the gold standard; however, FNAC along with its limitations, over time, has still held its ground firmly. FNAC can be relied for the diagnosis of inflammatory, pre-malignant and malignant lesions which in effect, can reduce morbidity and improve patient care.

References

1. Kocjan G, Bourgain C, Fassina A, et al. The role of breast FNAC in diagnosis and clinical management: a survey of current practice. *Cytopathology*.2008; 19:271-78.
2. Cochrane RA, Singhal H, Monypenny IJ, et al. Evaluation of general practitioner referrals to a specialist breast clinic according to the UK national guidelines. *Euro J Surg Oncol*.1997; 23(3):198-201.
3. Ferlay JBF, Pisani P, Parkin DM. *GLOBOCON*.2000: Cancer incidence, Mortality

- and Prevalence Worldwide, version 1.0.2001. Geneva: WHO.
4. Ellis IO, Humphreys S, Michell M, et al. Guidelines for Non-Operative Diagnostic Procedures and Reporting in Breast Cancer Screening, NHS Cancer Screening Programme, Sheffield, UK, 2001.
 5. Garbar C, Cure H. Fine needle aspiration cytology can play a role in neoadjuvant chemotherapy in operable breast cancer, *ISRN Oncology*, 2013:5
 6. Kocjan G. Evaluation of the cost effectiveness of establishing a fine needle aspiration cytology clinic in hospital out-patient department. *Cytopathology*. 1991;2(1):13-8.
 7. Panjvani SI, Parikh BJ, Parikh SB, et al. Utility of fine needle aspiration cytology in the evaluation of breast lesions. 2013;7(12):2777-2779.
 8. Khan A, Jamali R, Jan M, Tasneem M. Correlation of aspiration cytology and histopathology diagnosis in the evaluation of breast lumps. *Int J Med Students*. 2014;2(2):37-40.
 9. Kumar R. Clinicopathologic study of breast lumps in Bhairawa, Nepal. *Asian Pac J Cancer Pre*. 2010;11:855-858
 10. Tiwari M. Role of fine needle aspiration cytology in diagnosis of breast lumps. *Kathmandu Univ Med J*. 2007;5:215-217.
 11. Dennison G, Anand R, Makar SH, Pain JA. A prospective study of the use of fine-needle aspiration cytology and core biopsy in the diagnosis of breast cancer. *Breast J*. 2003;9:491-493.
 12. Khemka A, Chakrabarti N, Shah S, Patel V. Palpable breast lumps: Fine needle aspiration cytology versus histopathology: A correlation of diagnostic accuracy. *Internet J Surg*. 2009;18:1.
 13. Ganiat O, Omoniyi- Esan G, Osasan S, et al. Clinicopathological review of breast lesions in Ile-Ife Nigeria, *The Internet J of Third World Med*. 2008;8:10-25.
 14. Hussain MT. Comparison of fine needle aspiration cytology with excision biopsy of breast lump. *J Coll Physicians Surg Pak*. 2005;15:211-4.
 15. Nguansangiam S, Jesdapatarakul S, Tangkitgamol S. Accuracy of fine needle aspiration cytology from breast masses in Thailand. *Asian Pac J Cancer Prev*. 2009;10(4):623-6.
 16. Aslam HM, Saleem S, Shaikh HA, et al. Clinicopathological profile of patients with breast diseases. *Diagn Pathol*. 2013;8:77
 17. Singh A, Haritwal A, Murli BM. Pattern of breast lumps and diagnostic accuracy of fine needle aspiration cytology: a hospital based study from Pondicherry, India. *Internet J Pathol*. 2011;11(2):11
 18. Haddad FS, Re: Risk factors for perineal seeding of prostate cancer after needle biopsy. *J Urol*. 1990;143:587-88

Source of Support: Nil

Conflict of Interest: None