

Study of comparison of obtaining transcervical chorionic villus sampling by needle and infant feeding tube

Jyoti Kiran Kohli*

Department of Anatomy, Manav Rachna Dental College, Faridabad, Sector-43, Haryana, India

ABSTRACT

The developmental abnormalities are on rise, due to increased exposure to environmental toxins and intervention in reproductive process and so the risk to any pregnant couple of having up to 5% live-born infant with a chromosomal abnormality or structural defect had been estimated to be 3-5%. Thus, the need of diagnostic means to do early maternal screening at peripheral centers is also required to identify at-risk pregnancies in more accurate and faster way. Of all different ways available amniocentesis and chorionic villus biopsy are the for congenital defects are most accurate and definitive but carry significant risk of fetal loss. Chorionic villus sampling done under ultrasound guidance decreases this risk and increases the accuracy of procedure. This study was done few years back as part of thesis in Maulana Azad Medical College along with Gynaecology and Obstetrics Department of LNJP Hospital. In this study, transcervical sampling of chorionic tissue was done under ultrasound guidance in females undergoing medical termination of pregnancy in the first trimester, and tissue was procured with chorionic villus sampling (CVS) biopsy needle and then with infant feeding tube. Both obtained tissues were proceeded in the same way and same environment. Of 20 samples done, 18 samples were successfully obtained by infant feeding tube, and of this, 16 samples were adequate to be processed. While with biopsy needle, tissues were obtained in all but adequate tissue obtained in 18 only. Thus, sampling by infant feeding tube is an cost-effective method to procure chorionic villus at peripheral centers too for screening and diagnosing genetic diseases, thus decreasing load on referral centres.

Key words: Amniocentesis, chorionic villus sampling, infant feeding tube, transcervical chorionic villus

INTRODUCTION

The developmental abnormalities are on rise, due to increased exposure to environmental toxins and intervention in the reproductive process and so the risk to any pregnant couple of having a live-born infant with a chromosomal abnormality or structural defect had been estimated to be 3-5%.^[1] The current diagnostic means such as early maternal screening and ultrasound markers (alone or in combination) identify at-risk pregnancies is more accurate and faster way.

Special pregnancy screening includes:

- RH testing
- Sonography
- Amniocentesis and chorionic villus biopsy: Test for congenital defects by direct sample of products of conception as indicated.
- Alpha fetoprotein: To detect some neural tube defects and other conditions.

Although non-invasive tests show a considerable rates of false positives and false negatives, invasive ones are more definitive but carry a significant risk of fetal loss.

Chorionic Villus Sampling

It is a prenatal medical procedure, performed between 8 and 11 weeks of pregnancy, in which a small sample of placenta is removed. This tissue can be obtained by transabdominal or transcervical approach and can be then further analyzed for genetic analysis such as karyotyping, fluorescence *in situ* hybridization (FISH), or polymerase chain reaction (PCR).

A number of methods have been devised to retrieve transcervical cell (TCC) samples from endocervical canal and endometrial cavity, including smears obtained with:

- Cotton swabs or a cytobrush,^[2]
- Aspiration of cervical mucus with a catheter^[2]
- Endometrial biopsy with a pipette
- Lavage of endocervical canal/uterine cavity.

Each method has its own benefits and drawback.

This study is done keeping in view cost-effectiveness of obtaining transcervical CVS tissue for definitive screening and then direct karyotyping at peripheral centers. Aspiration of CVS tissue is done with infant feeding tube no. 16 under ultrasound guidance. and tissue procured is compared with the one obtained with chorionic biopsy needle.

Address for correspondence:

Jyoti Kiran Kohli, E-12, 1st Floor, Lajpat Nagar-1st, New Delhi - 110 024, India. E-mail: jkk702003@yahoo.co.in

Received: 02-04-2018

Revised: 20-04-2018

Accepted: 07-05-2018

Although this study was done few years back as part of thesis done by author herself, this comparison is useful to obtain tissue for analysis at peripheral areas for screening with minimum facilities.^[3]

Review

During pregnancy, fetal cells suitable for genetic testing can be obtained from amniotic fluid by:

- a. Amniocentesis,
- b. Placental tissue by CVS sampling, or
- c. Fetal blood.

When this screening test needs to be performed, it carries an increased risk of miscarriage between 0.5% and 1%. There is also increased risk of limb problems in the offspring due to procedure.^[4]

Amniocentesis is not recommended before 15 weeks and chorionic villus sampling before 10 weeks due to increased risk of miscarriage if done before this time.

Chorionic Villus Sampling

It is a prenatal medical procedure in which a small sample of placenta is removed. It is performed between 8 and 11 weeks of pregnancy and provides information about the presence of birth defects, but it has a slightly higher risk of miscarriage than amniocentesis.

Although preimplantation genetic diagnosis (PGD) is an alternative to prenatal diagnosis (as an adjunct to assisted reproductive technology that requires *in vitro* fertilization) and involves screening for chromosomal abnormalities or single gene disorders in an embryo before implantation.^[5] However, this has its own risk and high costs. Thus, PGD is not feasible as a universal diagnostic tool for genetic abnormalities in the general population. As the new approaches for prenatal diagnosis using maternal plasma are challenging for practical application, they require sophisticated and expensive technology. Transcervically obtained trophoblastic cells had many clinical applications of it like for quantification of trophoblastic cells or genetic analysis using fluorescence in situ hybridization (FISH) or (PCR). But this procedure of obtaining chorionic tissue has a higher risk of miscarriage than amniocentesis.

Disadvantages of Different Methods for Obtaining Transcervical Chorionic Tissue

- Limitation of using cotton swabs to retrieve TCC samples is the entrapment of cells within cotton, which may reduce yield
- Use of cytobrush by inserting through external os to a maximum depth of 2 cm and rotated a full turn during removal provides fetal cells in diagnostic quantities.
- Aspiration of endocervical mucus with a single cannula also results in the detection of fetal cells in up to 70% of TCC samples from mothers, with male fetus.^[2]

Another method is intrauterine lavage (IUL) - where sufficient cell retrieval was done and correct prediction of fetal sex was done^[6] - but sample size was small ($n = 25$).

Obtaining TCC samples/specimen was rather easy, but it contains maternal squamous cells, blood elements, spermatozoa, and varying degrees of particulate contaminants. It is thought

that gestational age can influence the proportion of fetal cells obtained.^[6]

Hence to improve on this fault the cellular clumps were discarded and single cell layer of cells were obtained for immunohistochemistry or FISH ANALYSIS (7). The cellular morphology was also assessed, as spermatozoa and other contaminants can easily be identified.^[7] The cellular morphology should also be assessed, as spermatozoa and other contaminants can easily be identified.

Due to all these disadvantages, larger prospective studies are required with long-term follow-up to detect possible adverse outcomes for prenatal diagnosis by TCC sampling.

Various types of useful diagnostic information can be obtained from TCC samples, and most reported studies of fetal cells obtained from the cervical canal or by IUL are based on identification of fetal sex and chromosome analysis using FISH or QF-PCR. A few studies have reported the use immunohistochemistry to identify fetal cells based on their expression of specific trophoblast marker proteins.

Genetic approach compared to standard karyotyping, FISH, and QF-PCR can be exquisitely sensitive for the analysis of TCC and IUL samples. PCR amplification in the presence of DNA binding dyes permits quantification of a relative number of copies.

Samples can be used for immunohistochemical staining with monoclonal antibodies.

The recovery and analysis of fetal cells shed from the placenta into cervical canal could provide wider availability of prenatal genetic diagnostics to the general patient population.

A similar study was done by Fang *et al.* reported the presence of fetal cells in 60% of TCC samples retrieved by endocervical mucus aspiration using a cervical catheter made from an infant feeding tube.^[6] No mucolytics was used, and sample was fixed with their samples after analyzing the cellularity.

The ability to procure cytotrophoblast cells by TCC as early as 6 weeks' gestation could make this vital information available much earlier than current technologies (analysis of fetal DNA in maternal serum).

With improvements in the efficacy and safety of trophoblast collection by TCC sampling using infant feeding tube and in identification and isolation of those cells expressing trophoblast markers, small quantities of fetal DNA could be readily obtained for genetic testing. It is an easy, cost-effective way to obtain CVS sample in remote areas.

These advances will provide new and safer choices for pregnant women throughout the world who are in need of prenatal diagnosis.

MATERIALS AND METHODS

The present study was conducted jointly in the Department of Anatomy and Gynaecology and Obstetrics, MAMC and associated Lok Nayak, G.B Pant and GNEC Hospital, New Delhi, as part of thesis work done there in 2001.

The material for the study comprised of 20 healthy patients with 6–12 weeks gestation coming for MTP in Lok Nayak Hospital.

All patients were meticulously evaluated through detailed history sessions and clinical examinations and then subjected to routine and special investigations for establishing the diagnosis.

After obtaining written informed consent from all patients, each of subject was subjected for CVS, i.e., ultrasound-guided transcervical CVS by Brahmabati's method (sampling is done by a infant feeding tube no. 16 and CVS biopsy needle both in the same patient).

List of instruments required for CVS:

- Sim's speculum
- Anterior wall retractor Figure 1a and b
- CVS sampling cannula no. 18G (modified KOH cannula with slightly bulbous tip and stylet)
- Infant feeding tube no. 16
- 20 cc syringe with 5 ml RPMI medium and heparin (200 IU/ml)
- USG sector scanner (5 MHZ Figure 2).

Procedure

Patient was advised to have partially full bladder and was made to lie down in lithotomy position on the table.



Figure 1(a): Instruments used for transcervical sampling

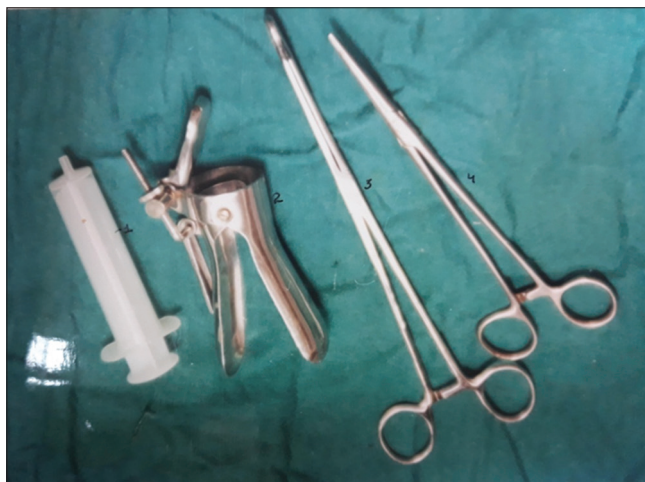

Figure 1(b): Instruments used for transcervical sampling

External genitalia was cleaned and disinfected with Savlon and betadine.

Cervix and vagina were visualized with a speculum and cleansed with broad-spectrum antiseptic solution. Vaginal examination was carried out to find the direction and correct size of the uterus [Figure 6,7].

Sonography was done to confirm:

- Duration of pregnancy
- Viability of pregnancy
- Rule out associated complication such as adnexal masses, fibroids, multiple pregnancy, subchorionic haemorrhage, and ectopic pregnancy.

Posterior vaginal wall was retracted with Sim's speculum, and the anterior lip of cervix was grasped with a tenaculum to be able to modify the between cervical canal and antiflexed uterus.

5 MHZ Sector scanner USG probe was used for locating gestational sac and for chorionic frondosum. Under USG guidance, malleable stainless steel cannula (18G) (modified KCH cannula with bulbous tip) with stylet was gently introduced through the cervix to chorion frondosum [Figures 2 and 6].

While holding the catheter in place, the stylet was removed gently. A 20 cc disposable syringe, containing 5 ml RPMI medium with heparin (200 I.U), was attached to outer catheter, and chorionic villi was obtained by suction with gentle to and fro movements, from thickest portion of chorion frondosum.

The stylet was then removed gently, and tissue was checked for the presence of adequate quantity of vascular healthy villi [Figure 8].

Contents of the syringe were then immediately transported for direct karyotyping in a simple container filled with 10 ml of nutrient medium (RPMI) after this same steps followed and infant feeding tube was introduced and sample of CVS was again collected same way by aspiration and processed for direct karyotyping [Figures 3 and 4].

OBSERVATION AND RESULT OF CVS

20 samples were obtained of chorionic tissue by aspiration through infant feeding tube first and then by chorionic biopsy needle. Sampling was done by transcervical route under ultrasound guidance, in patient going for first trimester abortions.

2 samples were found contaminated out of successful obtaining of 18 cases in which cvs tissue was obtained.

Rest two were unable to obtain tissues due to early pregnancy and not enough suction by 20 cc syringe.

CVS is estimated to be 90% accurate in blind aspirated tissue as compared to CVS biopsy needle obtained tissue in about 11% of cases and CVS cannot establish with certainty that the chromosomes in the fetus are normal. Further confirmation is required in such cases by amniocentesis/obtaining tissue by biopsy [Table 1].

Procurement rate of obtaining cvs tissue successfully by infant feeding tube is -90% while

Table 1: Duration of pregnancy versus chorionic tissue obtained

Duration of pregnancy	Number of patients	CVS biopsy obtained with IFT	CVS biopsy obtained with biopsy needle	Adequate sample obtained
6 weeks	1	No	Obtained	-
7 weeks	1	No	Obtained	Not sufficient
8 weeks	10	Yes	Yes	Adequate (in 8 cases only)
9 weeks	5	Yes	Yes	Adequate
10 weeks	2	Yes	Yes	Adequate
12 weeks	1	Obtained	Obtained	Obtained

CVS: Chorionic villus sampling, IFT-infant feeding tube



Figure 2: Ultrasound sector scan



Figure 4: Polyver microscope



Figure 3: Laminar flow

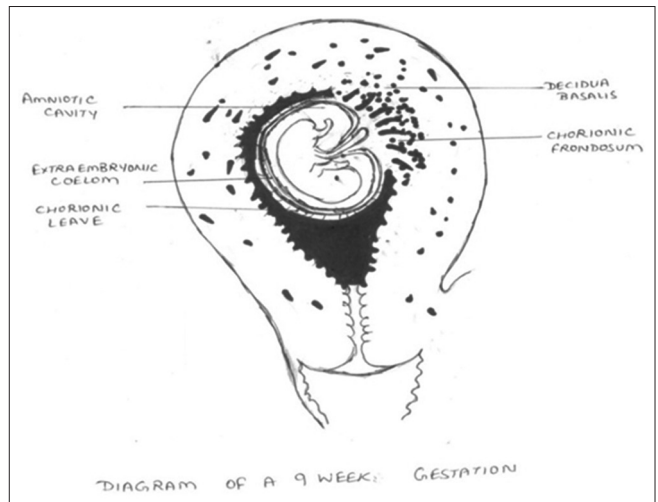


Figure 5: 9 week gestation sac showing site of chorionic tissue

Procurement rate of obtaining adequate tissue for processing is -80%.

While success rate of obtaining tissue through biopsy needle is -100% while

Procurement rate of obtaining adequate tissue for further processing is -85%.

Adequate material was obtained in 16 cases(by infant feeding tube) out of 20 -patients in 2 cases no material obtained was obtained and rest 2cases showed insufficient tissue being obtained for further analysis,(i.e tissue obtained in 6-7 weeks of pregnancy-- sample obtained was less than 10 mg).

Advantages of CVS

- Detection of chromosomal abnormalities, genetic birth defects, and other genetic defects at a remote or underprivileged center.

- Early detection of genetic defects in 24–48 h.
- Less apprehension of mother.
- Cost-effective, cheaper method if done by infant feeding tube for the screening of genetic abnormalities and thus decreases the load on referral centers.

Disadvantages of CVS

- Chance of having a miscarriage after CVS is about 1:100 (1%)
- Apprehension for procedure in mother,

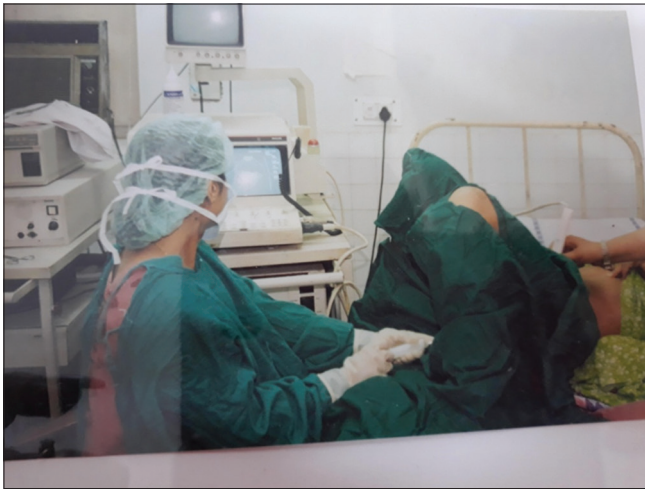

Figure 6: Ultrasound guided tissue obtained by transcervical route (infant feeding tube)

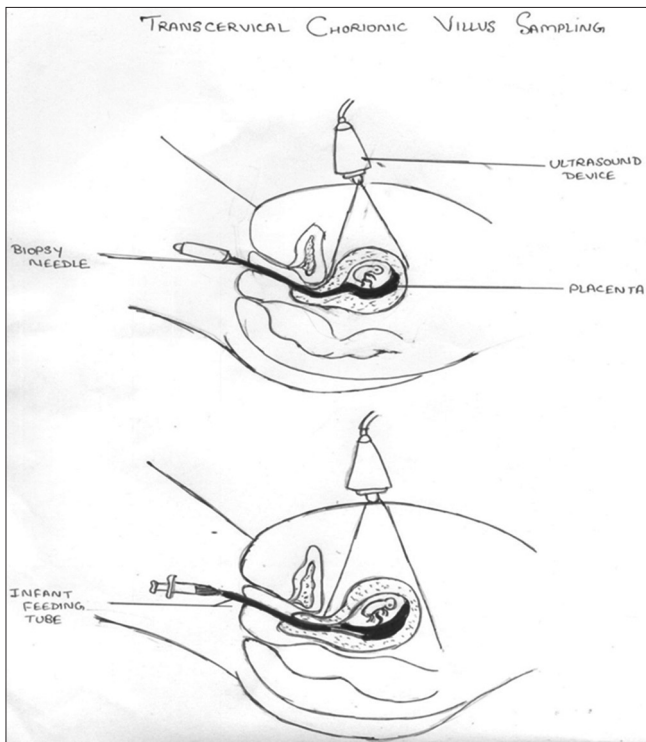


Figure 7: Transcervical chorionic villus sampling by biopsy needle (above) and by infant feeding tube (below)

- Contamination of sample if not preserved or cleaned properly
- Need expert hands to do this
- Chance of vaginal bleeding after procedure.

The new approaches for prenatal diagnosis using maternal plasma are challenging for practical application because they require sophisticated and expensive technology.

DISCUSSION

There is an obvious attraction to any technique for obtaining tissue of fetal origin for prenatal diagnosis using simple, cheap,




Figure 8: Chronic villus in a Petridish

and readily available equipment in which amniotic sac is not transgressed.

CVS in high-risk cases by ultrasound-guided technique is a well-established and acceptable technique (done by expert hands) and gives less failure rate. This technique of obtaining tissue by infant feeding tube can be used at peripheral centers to decrease the load on referral centers and can be used for early diagnosis (as sampling can be used for direct karyotyping). Similar kind of trial was done as a blind aspiration by transcervical method of obtaining chorionic villus in 1983.^[6] The study was done on 137 patients, of which tissue was obtained in 45 patients. The collection was not successful in 8–11 weeks gestation, thus only 9% was adequate collection, and trophoblast was also contaminated by maternal tissue or blood.

Alfirevic *et al.* conducted another study a systemic analysis of 45 studies and reported a fetal loss rate of 1.9% for amniocentesis and 2% for chorionic villus sampling.^[8]

The spontaneous fetal loss rate after first trimester combined test was 1.40%, whereas after CVS, it was 2.76% and 2.43% for transcervical and transabdominal approach with an additional risk of fetal loss with transcervical CVS of 1.36% (1:74), which varied according to the instrument used (0.27% for forceps and 3.12% for cannula) according to a study done by Mcweeney *et al.* in 2012.^[9,10] However, total rate of procedure-related fetal loss after transabdominal and transcervical CVS and amniocentesis appears lower than the risks on which women are currently counseled.^[4,5,8]

Although with patient counselling beforehand, newer technology and use of ultrasound guidance during procedure the disadvantages of this procedure are reduced to minimum with low chances of fetal loss even in high risk pregnancies (transcervical route) and this finding is supported by a recent study conducted in 2017, (11) by Alfirevic *et al.* which says second trimester amniocentesis may be associated with high pregnancy loss when compared with transabdominal cvs sampling. Transcervical sampling when compared showed higher risk of pregnancy loss but results were heterogeneous. (8,12). Thus to conclude transcervical sampling of chorionic villus with infant feeding tube can be selected as a cost effective method at peripheral centres for screening and diagnosing genetic diseases, thus also decreasing load on referral centres and beneficial for

apprehensive parents too. higher risk of pregnancy loss, but results were heterogeneous.^[8,12]

REFERENCES

- Royal College of Obstetricians and Gynecologists, Greentop Guidelines No.8, June 2010, Amniocentesis and Chorionic Villus; 2010.
- Imudia AN, Kumar S, Diamond MP, DeCherney AH, Armant DR. Transcervical retrieval of fetal cells in the practice of modern medicine: A review of current literature and future direction. *Ferti Steril* 2010;93:1725-30.
- Akolekar R, Beta J, Picciarelli G, Ogilvie C, D'Antonio F. Procedure-related risk of miscarriage following amniocentesis and chorionic villus sampling: A systematic review and meta-analysis. *Ultrasound Obstet Gynecol* 2015;45:16-26.
- McWeeney DT, Schwendemann WD, Nitsche JF, Rose CH, Davies NP, Watson WJ, *et al.* Transabdominal and transcervical chorionic villus sampling models to teach maternal-fetal medicine fellows. *Am J Perinatol* 2012;29:497-502.
- Bakker M, Birnie E, Robles de Medina P, Sollie KM, Pajkrt E, Bilardo CM, *et al.* Total pregnancy loss after chorionic villus sampling and amniocentesis: A cohort study. *Ultrasound Obstet Gynecol* 2017;49:599-606.
- Liu DT, Mitchell J, Johnson J, Wass DM. Trophoblast sampling by blind transcervical aspiration. *Br J Obstet Gynaecol* 1983;90:1119-23.
- Kohli JK. Prenatal diagnosis and screening of genetic abnormalities in early pregnancy. *J Evid Based Med Healthcare* 2016;3:5053-7.
- Alfirevic Z, Navaratnam K, Mujezinovic F. Amniocentesis and chorionic villus sampling for prenatal diagnosis. *Cochrane Database Syst Rev* 2017. DOI: 10.1002/14651858.
- Anthony N, Suzuki Y, Kilburn BA, Yelian FD, Diamond MP, Romero R, *et al.* Retrieval of trophoblast cells from cervical canal for production of abnormal pregnancy: A pilot study. *Human Reprod* 2009;24:2086-92.
- Richerd S, Moore CA, Khoury MJ, Erickson D, Edmonds LD, Botto LD, *et al.* Chrionic villus sampling and amniocentesis: Recommendations and amniocentesis: Recommendations for prenatal counseling. *MMWR Morb Mortal Wkly Rep* 1995;21:44:1-12.
- Beta J, Lesmes-Heredia C, Bedetti C, Akolekar R. Risk of miscarriage following amniocentesis and chorionic villus sampling: A systemic review of the literature. *Minerva Ginecol* 2017;21. DOI: 10.23736/s0026-4784.17.04178-8.
- Stergiotou I, Borobio V, Bennasar M, Goncé A, Mula R, Nuruddin M, *et al.* Transcervical chorionic villus sampling: A practical guide. *J Matern Fetal Neonatal Med* 2016;29:1244-51.

How to cite this Article: Kohli JK. Study of comparision of obtaining transcervical chorionic villus sampling by needle and infant feeding tube. *Asian Pac. J. Health Sci.*, 2018; 5(2):80-85.

Source of Support: Nil, **Conflict of Interest:** None declared.