

Pleomorphic adenoma of right lateral nasal wall- unusual presentation**N. Rastogi*, A. Gupta***Department of Pathology, Government Medical College, Kota, Rajasthan, India***ABSTRACT**

Pleomorphic adenoma is the most common benign salivary gland tumor, mainly of the major salivary glands (65%), especially in the parotid and less frequently in minor salivary glands (35%) found in the upper aerodigestive tract including the nasal cavity, pharynx, larynx, trachea, maxillary sinus, out of which 80 % are found in the nasal septum and 20 % in lateral wall or turbinate. They are benign of long duration, incomplete resection may lead to recurrence and increased chances of malignant transformation, hence early diagnosis using Fine needle aspiration, biopsy and complete excision with its pseudocapsule and surrounding margins is important.

Key words: Pleomorphic adenoma. Lateral nasal wall, fine needle aspiration, unusual site.

Introduction

Pleomorphic adenomas are benign primary neoplasms composed of both stromal and epithelial components.[3]. Salivary gland tumors constitute 3 % of all neoplasms [4]. It mainly arises in the major salivary glands (65%), mainly in the parotid and less frequently in accessory salivary glands (35 %). Rarely in the lip, hard and soft palate, lacrimal gland, external auditory canal, rarely in the respiratory tract and even less frequently in the upper aerodigestive tract including nasal cavity, pharynx, larynx, trachea, maxillary sinus [5], out of which 80 % intranasal pleomorphic adenomas are found in the septum and only 20 % in the lateral nasal wall or turbinate. Early diagnosis can be made by Fine needle aspiration followed by histopathological examination.

Case report

A 42 years old Indian female patient presented with history of partial nasal blockage. A mass measuring 1.5 x1.5 cm was seen on right lateral nasal wall. The external surface was smooth, nodular and firm in consistency.(fig 1.) Anterior rhinoscopy showed a smooth bulge in the right nasal cavity. Fine needle aspiration was done, MGG stained smears comprised

of admixture of polygonal cells with round nucleus, stromal component and fibrillary chondromyxoidstroma. Cytomorphological diagnosis of Pleomorphic adenoma was made (Fig 2, 3) which was confirmed by histopathological examination (Fig 4). The tumor was removed with its pseudocapsule. Macroscopically cut section of tumor showed solid, pale white homogenous surface. Histopathological sections showed epithelial component, stroma and chondromyxoidstroma.

Discussion

Nasal pleomorphic adenoma is seen predominantly in females usually between the third and fifth decades of life. It is a slow growing tumor and therefore clinical symptoms appear after a long silent period [5]. There are various theories supporting this observation. According to Stevenson, remnants of the vomeronasal organ, an epithelium lined duct in the cartilaginous nasal septum degenerated in early fetus could be the reason for the appearance of these tumors in this particular region [6]. According to Ersner and Saltzman, in 1944, the precursors of the septal pleomorphic adenoma are ectopic embryonic epithelialized cells on the nasal septum mucosa, found during the migration of the nasal buds.[7]. According to Evans and Cruikshank, it originates directly from the matured salivary glandular tissue [8]. Dawe proposed a viral etiology from polyoma virus. [9]. Malignant transformation of pleomorphic adenoma of the nasal cavity has been reported in 2.4 to 10 % of cases, most common variant being carcinoma ex-

*Correspondence

Dr. N Rastogi

Department of Pathology, Government Medical College, Kota, Rajasthan, India

E Mail: nupurkota123@gmail.com

pleomorphic adenoma and less commonly malignant mixed form, in which both the epithelial and stromal components transform and metastasize together mainly to bone, liver, lung and regional lymph nodes.[10]. Local excision with clear margins is the treatment of choice in these tumors. If these tumors are allowed to progress untreated, they may cause local destruction of the paranasal sinuses.

Conclusion

Pleomorphic adenoma of the lateral nasal wall is exceptional. This case is presented here to make aware of pleomorphic adenoma as a differential diagnosis in swelling of lateral nasal wall as it can be diagnosed early by Fine needle aspiration aiding in complete surgical excision of the mass with clear margin to avoid recurrence and to exclude malignancy.



Fig 1: Clinical photo of right nasal wall

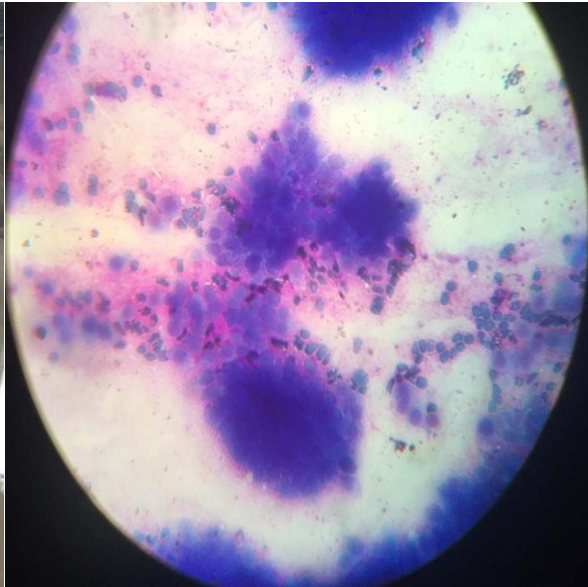


Fig 2: MGG cytology smear, 40 X

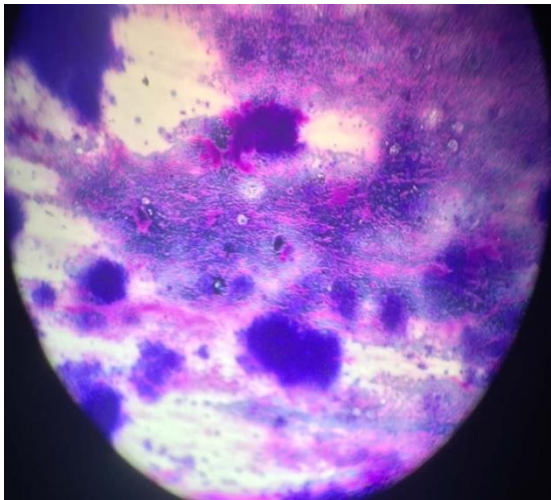


Fig 3: MGG cytology smear, 10 X

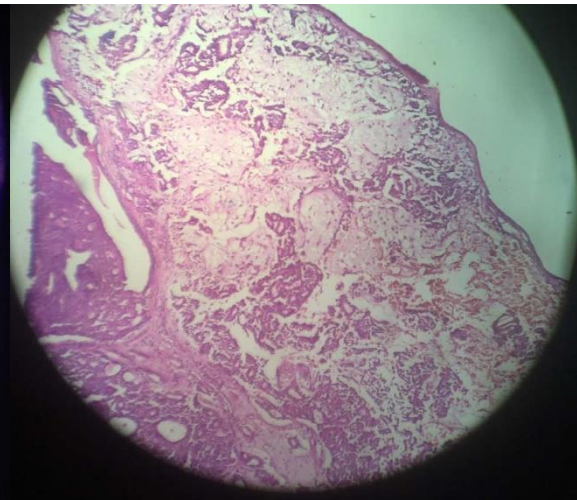


Fig 4: H & E stained histopathology slide, 10 X

Acknowledgements

Patient and her relatives

References

1. Pleomorphic adenoma of lateral wall of nose-a rare presentation, Usha K.M., Ratnakar MP. Otolaryngology online journal ,2014; 4 (1):12
2. Unusual origin of pleomorphic adenoma: lateral nasal wall, Li-Hsiang Cheng, Chih-Hung Wang, Bor-H.K., J. Med Sci 2010; 30(2): 075-077
3. Forrest A.W. Epithelial lacrimal gland tumors; pathology as a guide to prognosis, Trans Am Acad Ophthalmol Otolaryngol. 1954;58: 848-866.
4. Gana P and Masterson L. Pleomorphic adenoma of the nasal septum; a rare case report. Journal of Medical Case reports 2008; 2: 349.
5. Sciandra D et al. Pleomorphic adenoma of the lateral nasal wall: case report. Acta OtorhinolaryngologicaItalica 2008; 28: 150-153.
6. Stevenson HN. Mixed Tumor of the septum. Ann Otol Rhinol Laryngol 1932;41:563-70.
7. Ersner MJ, Saltzman M. A mixed tumor of the nasal septum. Report of a case. Laryngoscope 1944;54:287-95.
8. Evans RW, Cruikshank AH. Epithelial tumors of the salivary glands. In: Major problems in Pathology. Vol. 1, Philadelphia: WB Saunders; 1970. P. 281-95.
9. Dawe CJ. Tumors of salivary and lacrimal glands, nasal fossa and maxillary sinus. IASC Sci J 1979;23:91-113.
10. Jason LA et al. Pleomorphic adenoma of the nasal septum: a case report. Ear, Nose and Throat Journal. 2010:12

Source of Support: Nil

Conflict of Interest: None