

Mycetoma of breast

M Athar, Ajay Kumar*, Vikrant Mishra, Narendra Kumar

Department of Surgery, GSVM Medical College, Kanpur, U.P., India

Received: 09-10-2019 / Revised: 23-12-2019 / Accepted: 14-01-2020

ABSTRACT

Mycetoma is a chronic subcutaneous localized infection characterized by the triad of swelling, discharging sinuses and discharge of grains that may be caused by bacteria (actinomycetoma) or fungi (eumycetoma). Although it most commonly involves the foot, lower leg or hand, involvement of the head or back may also occur. The incidence is low in other parts of the body such as breast because of the lower risk of trauma as the initiating factor. We report an adult woman with single nodules in the breast on FNAC chronic granulomatous disease and later proved to be mycetoma after excisional biopsy.

Key words: breast, mycetoma, FNAC

©2020The Author(s). This is an open access article distributed under the terms of the Creative Commons Attribution License (<http://creativecommons.org/licenses/by/4.0/>), which permits unrestricted use, distribution, and reproduction in any medium, provided the original work is properly cited.

INTRODUCTION

Mycetoma is a chronic subcutaneous localized infection characterized by the triad of swelling, discharging sinuses and discharge of grains that may be caused by bacteria (actinomycetoma) or fungi (eumycetoma). Although it most commonly involves the foot, lower leg or hand, involvement of the head or back may also occur. The incidence is low in other parts of the body because of the lower risk of trauma as the initiating factor. We report an adult woman with single nodules in the breast on FNAC chronic granulomatous disease and later proved to be mycetoma after excisional biopsy.^[1-5]

CASE HISTORY

55-year-old woman presented with single asymptomatic subcutaneous nodules in the left breast for 2 years. She developed a solitary asymptomatic subcutaneous nodule in the left upper outer quadrant near the areola with Black colour nipple discharge. [Figure 1, 2].

Radiology

Ultrasonography shows a cystic lesion of size about 17x15x12 mm showing eccentric soft tissue component revealing mild internal vascularity at 2 to 3° clock position, associated with ductal dilatation measuring a maximum of 3mm closely abutting lesion. [Figure 3].

The patient develop a single, non-tender, coalescing soft to firm, subcutaneous nodules in the upper outer quadrant of the breast that varied from 2 to 4 cm in size. The overlying skin was intact.^[6-8]

Histopathology

FNAC s/o fibrocystic disease.

Nipple discharge cytology s/o chronic mastitis.

True cut biopsy s/o low grade *in situ* ductal carcinoma of cribriform type with intracystic papillary carcinoma

Excisional biopsy

Nodule showed a multiple foreign body giant cell granuloma formation with spore and filaments of fungal mycelium within it [Figure 4] inflammatory cell are predominantly plasma cell lymphocyte and epitheloid cell with multinucleated giant cell. Foci of dilated gland lined by ductal cell with apocrine metaplasia also seen. Fungal culture did not grow any organism even after 4 weeks. Based on the color of grains, histopathology and special stains, we diagnosed eumycetoma of the breast.

Treatment

Excision with itraconazole 200 mg twice a day. There was no significant change after 15 day. Stitched line after closer. [Figure 5]^[9-12]

CONCLUSION

Mycetoma usually involves parts of the body that come in contact with soil during daily activities. The foot is the most commonly affected site, being involved in 70% of patients while the hand, the next most commonly affected area, is involved in 12% of

Address for Correspondence

Dr. Ajay Kumar

Department of Surgery, GSVM Medical College, Kanpur, U.P., India.

E-mail: ajjumramc@gmail.com

patients. Rarely, sites such as the breast affected. For poorly understood reasons, actinomycetomas are more frequent than eumycetomas at uncommon locations such as the abdominal wall, chest, head and neck. Maiti *et al.* showed that mycetomas that occurred on covered parts of the body significantly differed from

mycetomas occurring in exposed areas and the former were almost always actinomycetomas.^[2]

This presentation of eumycetoma as coalescing, subcutaneous, breast nodules unaccompanied by any surface changes such as discharging sinuses in spite of disease lasting 4 years is distinctly unusual.

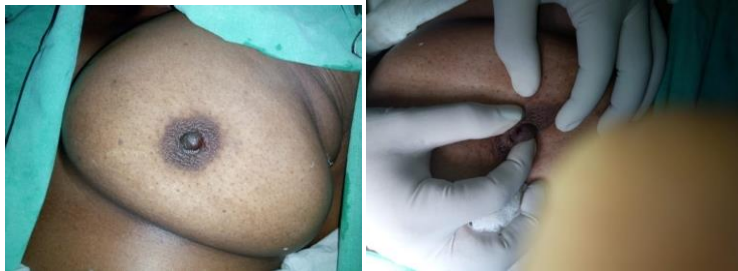

Figure 1,2: single asymptomatic subcutaneous nodules in the left breast for 2 years

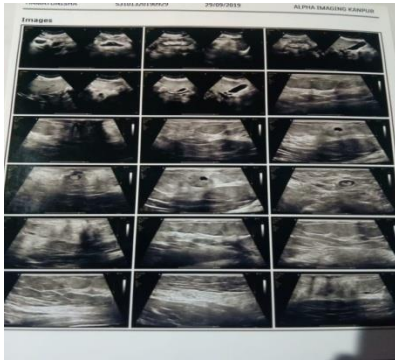

Figure 3: Ultrasonography

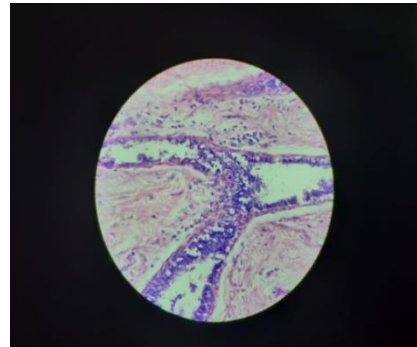


Figure 4: Histopathology

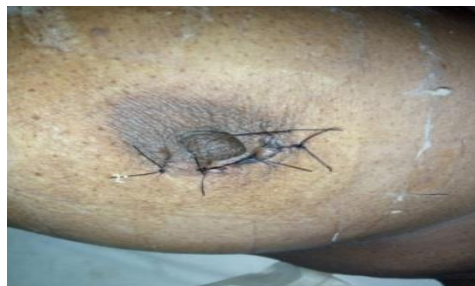

Figure 5: Stitched line after closer

REFERENCES

1. Fahal AH. Mycetoma thorn on the flesh. *Trans R Soc Trop Med Hyg* 2004;98: 3-11.
2. Maiti PK, Halder PK. Mycetomas in exposed and non-exposed parts of the body: A study of 212 cases. *Indian J Med Microbiol* 1998;16:19-22.
3. Gumaa SA, Mahgoub ES, E Sid MA. Mycetoma of the head and neck. *Am J Trop Med Hyg* 1986;35:594-600.
4. Dogra D, Ramam M, Banerjee U. Inguinal mycetoma. *Acta Dermatol Venereol* 1996; 76: 414.

5. Gupta S, Jain K, Parmar C, Shah P, Raval RC. Mycetoma: Nonvenereal perineal lesions. *Indian J Sex Transm Dis* 2010;31:39-41.
6. Shafei H, McCormick CS, Donnelly RJ. Madura foot of the chest wall; cure after radical excision. *Thorac Cardiovasc Surg* 1992;40:198-200.
7. Fahal AH, Suliman SH, Gadir AF, EL Hag IA, EL Amin FI, Gumaa SA, *et al.* Abdominal wall mycetoma: An unusual presentation. *Trans R Soc Trop Med Hyg* 1994;88:78-80.
8. Gumaa SA, Satir AA, Shehata AH, Mahgoub ES. Tumor of the mandible caused by *Madurella mycetomil*. *Am J Trop Med Hyg* 1975;24:471-4.
9. Clarke PR. Mycetoma of the testis. *Lancet* 1953;2:1341.
10. Fahal AH, Sharfy AR. Vulval mycetoma: A rare cause of bladder outlet obstruction. *Trans R Soc Trop Med Hyg* 1998;92:652-3.
11. Klossek JM, Serrano E, Péloquin L, Percodani J, Fontanel JP, Pessey JJ. Functional endoscopic sinus surgery and 109 mycetomas of the paranasal sinuses. *Laryngoscope* 1997;107:112-7.
12. Alridge J, Kirk R. Mycetoma of the eyelid. *Br J Ophthalmol* 1940;24:211-2.

How to cite this Article: Athar M, Kumar A, Mishra V, Kumar N. Mycetoma of breast. *Asian Pac. J. Health Sci.*, 2020; 7(1):40-42.
Source of Support: Nil, **Conflict of Interest:** None declared.