

COMPLETE MAXILLA IN CROSS BITE IN PRIMARY DENTITION – A RARE CASE REPORT**Deepesh Prajapati^{1*}, Rashmi Nayak², Damodar Kappadi¹, Anand Nayak¹**¹Department of Pedodontics & preventive dentistry, NIMS dental college, Jaipur, India²Department of Pedodontics & preventive dentistry, MCOADS, Manipal, India**ABSTRACT**

Cross bite in mixed and permanent dentition is very common. However similar cases in primary dentition are rare. As per common belief, treatment of cross bite should be initiated as soon as possible. This case report discusses the etiology and hurdles in treatment planning to be considered at young age group.

Keywords: cross bite, primary dentition, expansion screw, pre-schooler

INTRODUCTION

Primary dentition usually does not manifest with malocclusions like cross bite. Closed dentition is far more common anomaly in this dentition. Untreated cross-bite of the primary dentition is frequently followed by crossbite of the permanent teeth. S Hedge et al 2012 found very low prevalence of crossbite in preschoolers as 0.5% of anterior cross bite in Udaipur city of India. This study showed lower prevalence of anterior cross bite than that reported in Finnish, African-American, and Jordanian populations. Posterior crossbite was not observed in this study population compared to the findings in Finnish (13%), Saudi Arabian (4%), Nigerian (4.8%), and Jordanian (7%) children [1]. Anterior and posterior cross bites have different implications on development of dentition. Anterior cross bite no longer is able to lock the mandible, as a normal bite does, and hence allows unrestricted anterior posterior growth of the mandible worsening the situation and at the same time causing a straight if not a concave profile. Whilst posterior cross bite if not treated early, it may result in skeletal changes, demanding a more complex approach.

Additionally, an overcorrection expansion protocol is usually advised in order to improve the treatment stability. This case report mentions a rare case of anterior and posterior bilateral crossbite and its treatment at an early age of 4 years.

CASE REPORT

A female patient reported to us with complain of pain in upper left back tooth which was continuous in nature since three nights. On detailed clinical and radiographic examination 64 was diagnosed with chronic periapical abscess which was indicated for extraction due to severe pathologic root resorption. In the same appointment bilateral anterior and posterior cross bites were also noticed. On further examination patient showed a straight profile. After addressing the chief complaint by extracting the tooth, parents were made aware of the malocclusion their daughter had. After taking parental consent, impressions were made and an upper removable appliance with 2D jack screw was made. As 3D expansion was required, expansion was planned in two phases with one slit from distal of 53 to distal of 63 and another one with slit in mid sagittal plane in the second phase. In both phases appliances with posterior bite plate was given to jump the bite. No activation was done for the first week and child was given time to get adjusted with the appliance. After one week patient did not complain of any discomfort and she was comfortable wearing it for major part of the day. Activation schedule of quarter turn twice a week was followed as advised by Isaacson in his textbook [2]. Anterior cross bite was corrected in 5 weeks which was then followed by another

Correspondence*Dr. Deepesh Prajapati**

Assistant professor,

Department of Pedodontics & preventive dentistry,
NIMS dental college, Jaipur, India.**E-mail:** deepeshprajapati@gmail.com

expansion plate with slit in mid sagittal plane. Second phase was over in another 8 weeks. Figures from

number 1 to 5 shows the treatment at different phases.

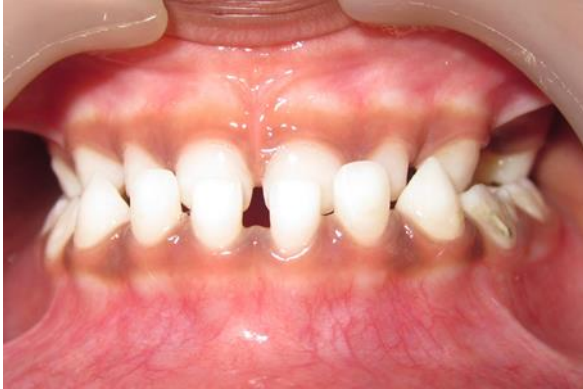

Figure 1: showing entire maxilla in cross bite

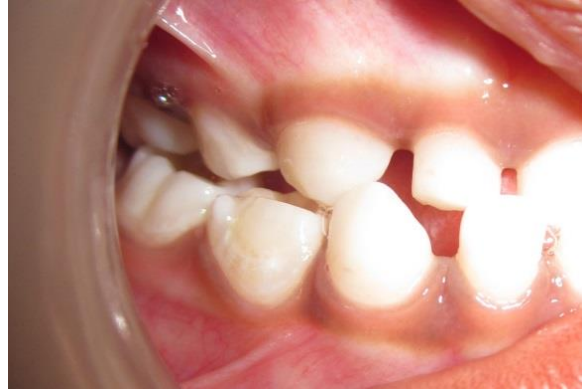

Figure no 2 (a) : right occlusal view showing posterior crossbites

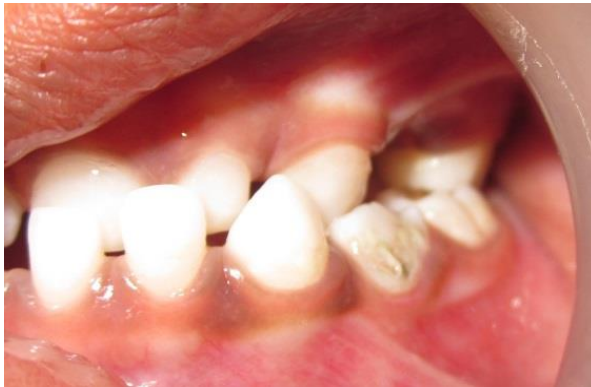

Figure 2 (b):left occlusal view showing posterior cross bite

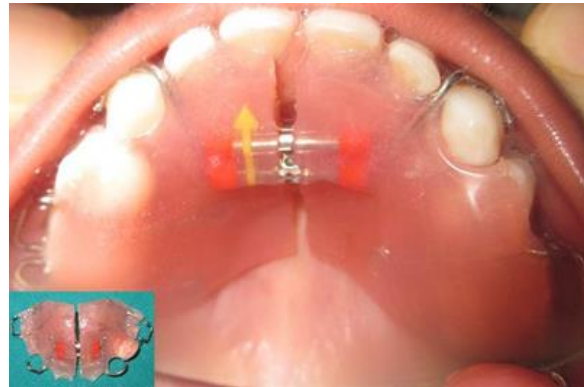


Figure 3:showing appliance in place for Cross bite

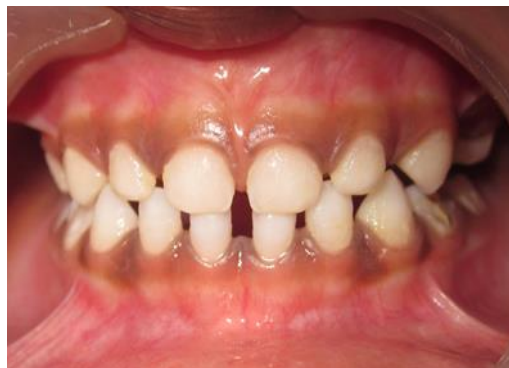

Figure 4: corrected cross bite

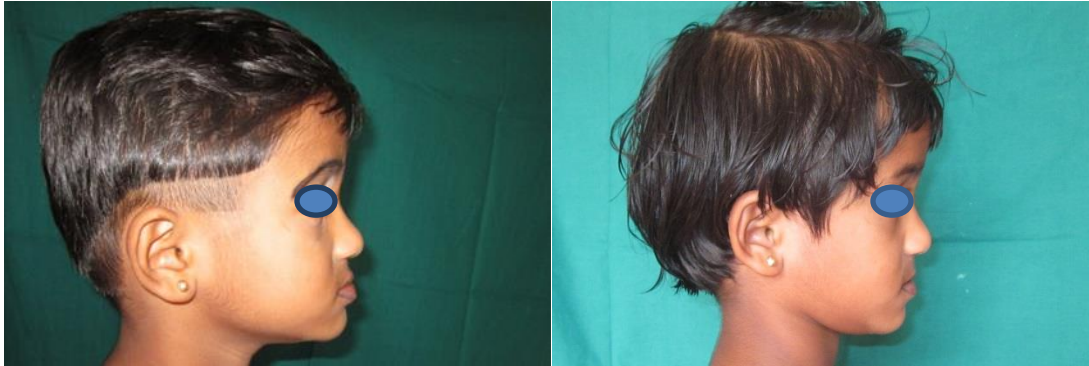

Figure 5 (a) and (b): with pre and post-operative lateral profiles showing obvious change in the profile from straight to convex

DISCUSSION

Posterior crossbite in the deciduous dentition can be classified into 3 categories: bilateral, true unilateral, and unilateral with functional deviation of the Mandible[3]. There can be many possible etiologies of crossbite which may include prolonged retention or premature loss of primary teeth, crowding, palatal cleft, genetic influence, arch deficiencies, abnormalities in tooth anatomy or eruption sequence, non-nutritive sucking habits, oral respiration during critical growth periods, and temporomandibular disorders[4]. Studies have pointed out that insufficient breastfeeding duration is related to malocclusions, particularly posterior crossbites[5]. The use of the feeding bottle could have a deleterious effect on the development of occlusion, perhaps as a predisposing factor for posterior cross bite. However detailed history taken for this case did not revealed any of such positive history.

According to Katz, Rosenblatt and Gondim (2004), the importance of genetic factors in the etiology of malocclusions seems to be less than environmental factors [6]. Larsson observed the development of interfering contacts in primary canines in cases of prolonged bottle feeding [7]. This can occur sometimes with normal eruption path of canines as well, when with eruption they might meet at cusp tip and functionally deviate the jaw from this point to reach occlusion such scenario can lead to functional cross bite. Differences between maxillary and mandibular widths (at the intercanine and intermolar levels) seem to be important for correction or noncorrection, both for untreated and treated children. The narrow crossbite side in the maxilla and the broad crossbite side in the mandible that was found by Melink *et al* in thier study are probably the most important etiologic factors for posterior crossbite development [8]. A possible reason

for the broad mandibular arch on the crossbite side might be the irregular tongue posture on the mouth floor, leading to a short frenulum linguae and irregular tongue function; these were found to be significant in the children with posterior cross bite in the deciduous dentition period [9]. Taking these factors into consideration a diagnosis for bilateral cross bite, anterior and posterior, was made.

Cross bite malocclusion does not show spontaneous correction, and should be treated with maxillary expansion as early as possible [10]. At the start of the treatment patient was only four years of age. As per thorough medical history patient was wearing a spectacles since 6 months without any discomfort and appeared co-operative during the extraction appointment. These factors helped us in formulating a treatment plan using removable appliances for her.

A 3D expansion screw was more suitable for this case. But due to financial constraints with parents, two 2D screws were used. This also helped us in making the appliance less bulky. All appliance activations were done in office. This increased the reliability of the expansion and also decreased the treatment duration.

Extracted space for 64 was included in the expansion appliance at all phases to act as a removable space maintainer. This is later planned to be replaced with a band and loop.

Views on retention for cross bite correction stands divided. For example, as per Arat ZM *et al* removable or fixed retainers are indicated for at least 3 months[11]. Studies have shown that 50% of posterior crossbite cases treated at primary dentition had to be retreated at mixed dentition[12]. Although these results

indicated a high-incidence relapse of early treatment, but other advantages have been attributed to this intervention. According to Harrison, maxillary expansion in the primary dentition decreases the risk of a posterior crossbite being perpetuated later to permanent dentition [13]. Patient was informed regarding the possibility of relapse and was advised to visit our clinic every 3 months post completion of treatment.

CONCLUSION

Cross bite treatment should be started at earliest. But patient's age and co-operation are limiting factor in case of pediatric population. This case report also substantiates effectiveness of expansion plates with jack screw in treatment of such malocclusions.

REFERENCES

1. S Hedge et al. Characteristics of occlusion in primary dentition of preschool children of Udaipur, India. *European Journal of Dentistry* 2012;6(1): 51-55.
2. Keith G. Isaacson, Ray T. Reed, John D. Muir. *Removable Orthodontic Appliances* 3rd ed. Wiley-Blackwell.
3. Malandris M, Mahoney EK. Aetiology, diagnosis and treatment of posterior crossbites in the primary dentition. *Int J Paediatr Dent* 2004;14:155-66.
4. CASTELO et al. Maximal bite force, facial morphology and sucking habits in young children with functional posterior crossbite. *J Appl Oral Sci.* 2010;18(2):143-8.
5. Kobayashi et al. Relationship between breastfeeding duration and prevalence of

- posterior crossbite in the deciduous dentition. *Am J OrthodDentofacialOrthop* 2010;137:54-8.
6. Katz CRT, Rosenblatt A, Gondim PPC. Nonnutritive sucking habits in Brazilian children: effects on deciduous dentition and relationship with facial morphology. *Am J OrthodDentofacialOrthop.* 2004;126 (1):53-7.
7. Larsson E. Sucking, chewing, and feeding habits and the development of crossbite: a longitudinal study of girls from birth to 3 years of age. *Angle Orthod.* 2001;71(2):116-9.
8. Melink et al. Posterior crossbite in the deciduous dentition period, its relation with sucking habits, irregular orofacial functions, and otolaryngological findings. *Am J OrthodDentofacialOrthop* 2010;138:32-40.
9. Ovsenik M. Incorrect orofacial functions until 5 years of age and their association with posterior crossbite. *Am J OrthodDentofacialOrthop* 2009;136:375-81.
10. Baccetti T, Franchi L, Cameron CG, McNamara JA Jr. Treatment timing for rapid maxillary expansion. *Angle Orthod.* 2001;71(5):343-50.
11. Arat ZM, Gökalp H, Atasever T, Türkkahraman H. ^{99m}Tc-methylene diphosphonate uptake in maxillary bone during and after rapid maxillary expansion. *Angle Orthod.* 2003;73(5):545-9.
12. Kuroi J, Berglund L. longitudinal study and cost benefit analysis of the effect of early treatment of posterior cross-bite in the primary dentition. *Eur J Orthod.* 1992;14(3):173-9.
13. Harrison JE, Ashby D. Orthodontic treatment for posterior crossbites. *Cochrane Database Syst Rev.* 2001;(1):CD000979

Source of Support: NIL

Conflict of Interest: None