

## Recurrent vertigo and intermittent jaw pain as primary presentation in Takayasu's arteritis

Tanveer Hassan Banday , Shahshikantha Bhat, Vikas Naik, Mathuraju N.

*Asst professor, AIMS B.G Nagar Bangalore India*

### ABSTRACT

Takayasu's arteritis (TA) is a non-specific arteritis with an unknown cause, affecting predominantly the aorta and its major branches. It is common in females in the second and third decades of life. We report a case of 32-year-old female who presented with recurrent vertigo and intermittent jaw pain.

**Key words:** Takayasu's arteritis, vertigo, subclavian artery, pulse.

### INTRODUCTION

Takayasu's arteritis (TA) is a chronic, idiopathic, inflammatory disease, seen in Asian countries with female predominance in a ratio of 5:1 [1,2]. The youngest patient was 3 years old [2]. The most common clinical manifestations of Takayasu's arteritis are nonspecific symptoms such as; fever, night pain, malaise and weight loss [3]. However, most important clinical features of TA are absent arterial pulses in the upper limbs, high blood pressure and headache. Many patients have ischemia of the upper extremities that may manifest as arm claudication or numbness at the time of disease recognition. Claudication of the lower limbs is less common as a presenting symptom. [4] Diminished Vascular bruits involving carotid, subclavian and abdominal vessels are also common (80–94%) [5]. Hypertension is associated with 33–83% patients of TA. Eighty-five percent of patients may have ESR greater than 30 mm/hr and 60% may have anemia [5].

### CASE REPORT

We report a case of 32-year-old female who presented to our outpatient department with the complaint of vertigo for past 6 weeks (only while standing and walking) previously one month back she was labelled as a case of enteric fever based on high titres of Widal test.

Fever subsided after few days but her vertigo persisted. She also gave history of jaw pain after eating food occasionally for last six months. On examination radial pulses were not palpable in right arm and it was feeble in left arm. Brachial pulses were very feeble in bilateral upper limbs with no audible bruit over carotids. Detailed examination revealed palpable popliteal and dorsalis pedis arteries bilaterally in lower limbs. Her BP was recorded 94/70 mm Hg (left upper limb), and 192/106 mm Hg (left lower limb). Examination of other systems was within normal limits except fundus examination which was suggestive of hypertensive changes. Neurological examination was normal. There was no focal deficit or any cranial nerve palsy. ENT examination and pure tone audiometry were normal.

**Investigation:** Baseline investigations including liver function test, renal function test and counts were within normal limits. Lipid profile, 2D echo, was normal. Serum cortisol levels were negative and IgM for *Styphii* and para *typhii* were negative. Anti-nuclear antibody, anti-cardiolipin antibody, anti-phospholipid antibody, c ANCA / p-ANCA, and lupus anti-coagulant were negative. VDRL for syphilis was negative. Non-contrast CT head showed no abnormality. Haemoglobin was reduced 9 gm%. ESR was raised (52 mm/hour). Arterial Doppler upper limb showed decreased flow velocity in right brachial ulnar and radial artery and monophasic wave pattern suggesting possible stenosis in brachiocephalic trunk. CT angiography showed diffuse wall thickening involving arch of aorta and great arteries, resulting in diffuse reduction in calibre of right subclavian, 60-70% stenosis in left SC, 60-70% stenosis in right common carotid and 70-80% stenosis in left

*\*Correspondence*

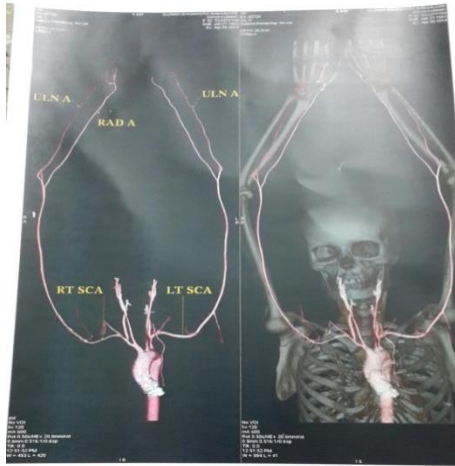
**Dr. Tanveer Hassan Banday**

Assistant Professor,

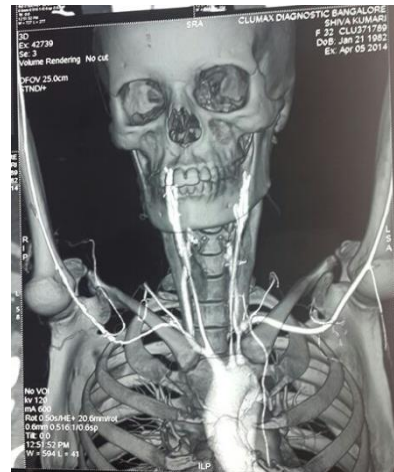AIMS B.G. Nagar Bangalore India.

**Email:** [drtanveerbanday90@gmail.com](mailto:drtanveerbanday90@gmail.com)

common carotid suggestive of post-arteritis sequelae (Fig 1,2).



**Fig1:Stenosis in right common carotid**



**Fig 2:Stenosis in left Common Carotid**

She was put on prednisolone with a starting dose of 40mg/day which tapered slowly to 10mg /day and simultaneously methotrexate was started at dose 7.5mg weekly. Patient is still in our follow up and has shown some improvement in her symptoms especially vertigo but is still complaining of intermittent pain in right arm occasionally. This paper emphasize the need to consider TA as differential in young female with recurrent vertigo and fever, especially if other clinical signs point towards diagnosis.

## DISCUSSION

In 1908 Mikito Takayasu , first time reported a pulseless in a young woman [6]. Takayasu disease affects large vessel primarily aorta, and its main branches. The incidence rate of the disease is about 2 per 10lakh with its onset at a mean of 35 years of age [7]. Though the pathogenesis of the disease remains unclear but there is an indirect evidence of an autoimmune process. Takayasu's arteritis has a variable presentation, because of its diffuse nature of vasculitis can involve multiple organ systems to varying degrees [1]. Clinical manifestations of TA have two phases: systemic phase and occlusive phase [8]. In systemic phase, patients have non-specific aches and sometimes arthritis. During the occlusive phase, affected arteries may be narrowed with absent normal arterial pulsations (pulseless). About 15–50% of the patients have nonspecific symptoms, where as one-third may present with anemia and other 10–30% have various cardiac symptoms. Around 50% patients may have neurologic symptoms, with

visual symptoms being most common . Strokes occur in 10% of the patients [9]. Vertigo is a common complaint but it is less reported with Takayasu's arteritis and rarely reported as the sole presentation of this disease [9]. Diagnosis is often difficult and is based on clinical features and angiographic findings [10]. The American College of Rheumatology criteria has commonly been accepted for diagnosis of Takayasu's Arteritis. Corticosteroids remain the therapy of choice for management of TA with a starting Dosage of 40-60 mg of prednisone daily which can be tapered as clinically indicated, to a maintenance dose of 10mg/day . Low-dose aspirin should complement corticosteroid therapy. Methotrexate, given in weekly doses of up to 25 mg, has shown some promise in sparing steroids. Overall, cytotoxic agents do not have impressive therapeutic benefit in this inflammatory vasculopathy. Bypass grafts and angioplastic management has gained importance in the management of irreversible TA. Mycophenolate or cyclophosphamide are recommended in case patient is refractory to glucocorticoids[12]. Prognosis is fairly good, with a ten-year survival rate of around 90%. Severe hypertension and cardiac failure are bad prognostic factors

## CONCLUSION

TA has varied presentation, females with unequal pulses between two arms with unexplained vertigo, Takayasu's arteritis should be kept as differential. Vertigo in our case could have been caused due to Takayasu's arteritis related narrowing of the vessels supplying to brain.

---

**REFERENCES**

1. Saab F, Giugliano RP, Giugliano GR. Takayasu arteritis in a young woman. *Texas Heart Institute Journal*. 2009;36(5):470–474.
2. Jain S, Sharma N, Singh S, et al. Takayasu arteritis in children and young Indians. *Int J Cardiol*. 2000;75 (Suppl 1):S153-7..
3. Park MC, Lee SW, Park YB, et al: Clinical characteristics and outcomes of Takayasu's arteritis: Analysis of 108 patients using standardized criteria for diagnosis, activity assessment, and angiographic classification. *Scand J Rheumatol* 2005;34:284-292.33(1):57-69
4. Kerr GS, Hallahan CW, Giordano J, et al: Takayasu Arteritis. *Ann Intern Med* ,1994, 120:919–929..
5. Kumar V, Abbas K, Fausto N: Robbins and Cotran Pathologic Basis of Disease. 7th edition. Elsevier Saunders; 2004
6. Takayasu M. Case with unusual changes of the central vessels in the retina. *Acta Soc Ophthal Jpn* 1908;12:554-5.
7. el-Reshaid K, Varro J, al-Duwairi Q, Anim JT. Takayasu's arteritis in Kuwait. *J TropMed Hyg* 1995;98(5):299-305.
8. Strachan RW. The natural history of Takayasu's arteriopathy. *QJ Med*. 1964; 33(1):57-69
9. Wenger M, Gasser R, Donnemiller E, Erler H, et al. Images in cardiovascular medicine. Generalized large vessel arteritis visualized by 18fluorodeoxyglucose-positron emission tomography. *Circulation* 2003;107(6):923.
10. Sharma BK, Jam s, Sun S, et at. Diagnostic criteria for Takayasu Arteritis. *Int. J. cardiol.*, 1996; 54: S141-47
11. Langford CA, Sneller MC, Hoffman GS. Methotrexate use in systemic vasculitis. *Rheum Dis Clin North Am* 1997; 23:841-853
12. .Liang P, Hoffman GS: Advances in the medical and surgical treatment of Takayasu arteritis. *Curr Opin Rheumatol* 2005, 17(1):16-24

**Source of Support: NIL**

**Conflict of Interest: None**