

A rare case report of Oral Ranula: an insight into its diagnosis, differential diagnosis & treatment modalities**Mohammed Abidullah^{1*}, G.Kiran,² Kavitha Gaddikeri³**¹ Assistant Professor, Department of Oral & Maxillofacial Pathology, S.B Patil Dental College and Hospital, Bidar, Karnataka, India² Reader, Department of Oral & Maxillofacial Pathology, Government Dental College and Hospital, Hyderabad, Telangana State, India³ Reader, Department of Oral & Maxillofacial Pathology, S.B Patil Dental College and Hospital, Bidar, Karnataka, India**ABSTRACT**

Lesions in the floor of the mouth pose a challenging situation both clinically & surgically because this area exhibits tightly netted vital structures. Any infection/lesion could lead to its spread to mediastinum making the surgeons treatments modalities difficult. The lesion in this region ranges from most benign ranula to sinister carcinomas. Ranula is type of mucocele occurring in the lateral side of the floor of the mouth which is closely related to vital structures like the sublingual gland & lingual nerve. The terminology ranula represents the swelling which resembles a frog's translucent underbelly. Ranulas are characteristically large, appears as translucent bluish fluctuant dome shaped swelling. While diagnosing, careful differential diagnosis should be carried out to rule out the other lesions occurring in the floor of the mouth like the lipoma, dermoid cyst, abscess, salivary gland lesions and vascular lesions. This paper highlights the clinical parameters, radiographic methods helping in differential diagnosis of ranula & treatment options available. Here we present a case of ranula occurring in lateral of floor of the mouth & its successful treatment by excision of the lesion.

Key words: Floor of the mouth, Mucous extravasation, Marsupialization, Ranula, Sublingual gland**INTRODUCTION**

The group of salivary gland lesions encompasses variety of lesions ranging from non- neoplastic entity to neoplastic lesions. The non neoplastic category mainly consists of congenital/ developmental lesions, inflammatory lesions, obstructive lesions, cyst of salivary glands where as the neoplastic category consist of benign & malignant tumors. The cyst of salivary glands mainly embraces Mucocoele, Ranula & Salivary duct cyst. "Ranula" was first reported by Hippocrates & Celsius^[1,2] & the terminology mainly gets its origin from the Latin term "Rana" which means frogs belly as the swelling resembles the frogs translucent underbelly.^[2,3,4]

There are various etiological factors that has been attributed to pathogenesis of ranula but the most accepted one is that it is mainly due to the trauma - direct trauma or from surgery to the floor of mouth.^[1,4,5] In this there is rupture of the excretory duct resulting in extravasation of mucous in surrounding tissue leading to formation of pseudo cyst.^[1-5] As ranula is mainly located in the floor of the mouth, poses a challenging situation both clinically & surgically because this area exhibits vital structures. Any lesion in this vicinity could lead to its spread to mediastinum creating a medical emergency & also makes the surgeons treatments modalities more challenging. Hence here we present a case report of ranula in left lateral floor of the mouth, its differential diagnosis with special emphasis on the treatment modalities in a nut shell.

Case history-A 19 year old male patient reported to the department of oral medicine & radiology with a chief complaint of swelling in the left side of the floor of the mouth since 2 month. Patient give history of swelling of

Correspondence*Dr.Mohammed Abidullah**Assistant Professor,
Department of Oral & Maxillofacial Pathology,
S.B Patil Dental College and Hospital, Bidar, Karnataka
Email: mdabid2512@gmail.com

the floor of the mouth which was initially small in size & gradually increased in size & attained the present size. Patient gives history of trauma to the mouth 4 months back. The lesion is not associated with pain or tenderness but the patient had difficulty in speech, mastication & swallowing. Patient consulted a doctor for the above complain & was prescribed medicine but the swelling

did not subside. On examination, a single dome shaped well circumscribed asymptomatic, swelling measuring approx 3x3cm, bluish in color was present in the left side of the floor of the mouth extending from the 34- 37 anterior- posteriorly & from lingual frenum to the lingual vestibule (Fig 1).

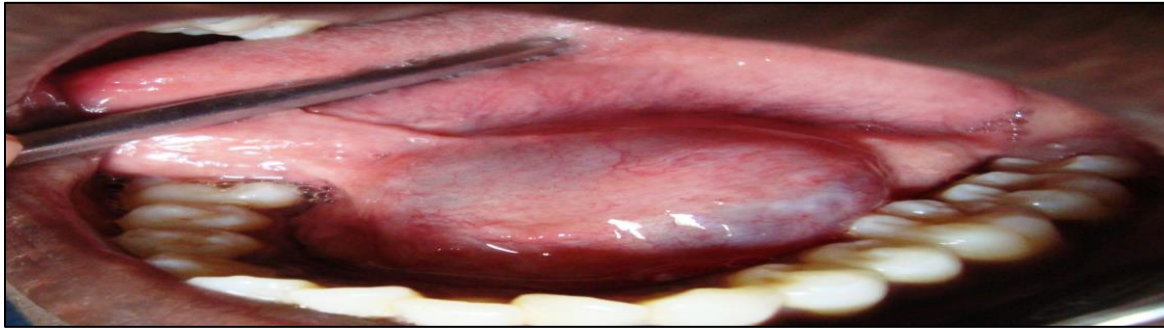


Fig 1: Intraoral examination reveals a dome shaped bluish swelling extending from the 34- 37 anterior- posteriorly & from lingual frenum to the lingual vestibule

On palpation, the swelling was non tender, fluctuant, non compressible. There was no evidence of blanching & the swelling did not emptied on compression. Correlating the clinical finding, the case was

provisionally diagnosed as “Ranula”. The patient was advised radiographic examination, which revealed no evidence of obstruction (Fig 2).

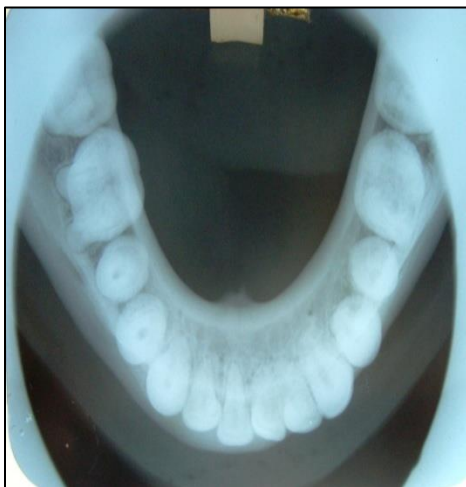

Fig 2:Occusal radiograph

To rule out the possibility of the cervical ranula a radiopaque contrasting medium was injected in the sublingual space, this did not yield any result ruling out any possibility of cervical ranula. Aspiration yielded a thick viscous fluid. After preoperative investigations, excision of ranula was carried out under local anesthesia

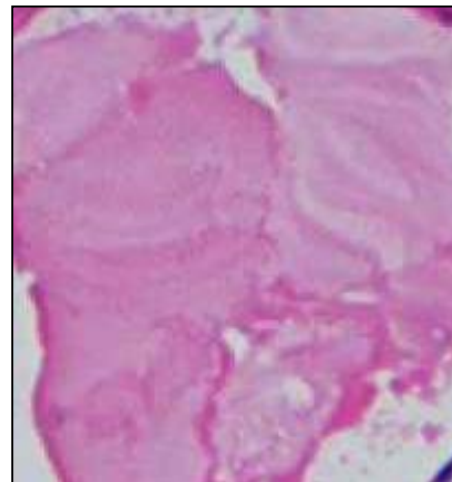


Fig 3:Depiction of spilled mucin

& was subjected to histopathological examination. Histopathological examination exhibited spilled mucin (Fig 3) with granulation tissue response (Fig 4, 5). The patient was followed up every week & recovery was uneventful.

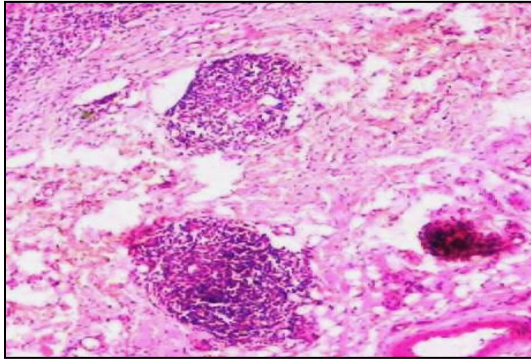


Fig 4: Photomicrograph showing granulation tissue formation

DISCUSSION

Hippocrates & Celsus were the authors who first reported about ranula. [2] Basically ranula is a mucous extravasation pseudo cyst with its location in the floor of the mouth where as the other type of extravasation phenomena that is mucocele occurs mainly on the lower lip. [1-6] Literature review reveals that clinically there are two types of ranula- oral & cervical/ plunging.

The etiopathogenesis of ranula is mainly attributed to trauma & partial obstruction of sublingual duct (<10%). [2,5,7] Our case report is in accordance with observations of Dr. Suman Jaishankar *et al*, [1] B Godhi *et al* [2] Bardhan A *et al*, [5] Adam Cheng [7] where the authors attributed the formation of ranula to direct trauma leading to rupture of the duct resulting in accumulation of mucous in surrounding tissue & forming a pseudo cyst. Contrasting observation was noted by B Godhi *et al* who attributed another etiological factor, that is if a salivary duct is partially block there is development of secretory back pressure that causes ruptures of the salivary duct causing the mucous to leak & accumulate in the adjacent tissues. [2] Pertaining to age in our case the patient was a young adult, similar observation was noted in studies of Garofalo S *et al*, [8] Onderoglu L *et al*, [9] Yuca K *et al*, [10] Gul A *et al* [11], Zhao YF [12] where the patients were mainly children & young adult. Similar to our observation, Dr. Suman Jaishankar *et al*, [1] B Godhi, [2] Shafer WG, [3] Neville, [4] Bardhan A [5] observed the most common site for ranulas as the lateral side of floor of the mouth. Pertaining to the clinical features, our case is in accordance with Dr. Suman Jaishankar *et al*, [1] B Godhi, [2] Shafer WG, [3] Neville, [4] Bardhan A [5], Baurmash HD [13] where they noted that clinically ranulas appear as blue, dome shaped, fluctuant asymptomatic swelling, the size varying from few centimeters to large size sometimes filling the floor of the mouth & elevating the tongue. To complete the discussion, a note on cervical/plunging ranula becomes mandatory as it has clinical significance. Cervical ranulas mainly occurs due

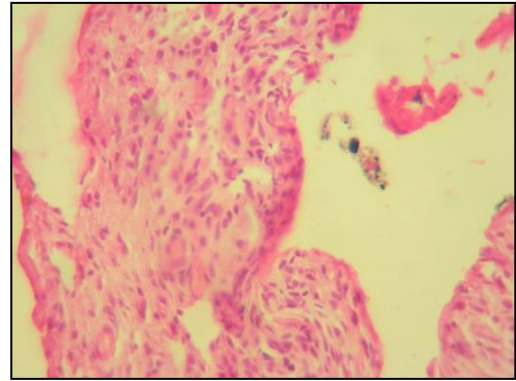


Fig 5: Photomicrograph showing granulation tissue response

to the sublingual gland projecting through the mylohyoid muscle or the ectopic salivary gland exist on the cervical side, dehiscence or hiatus of mylohyoid muscle & iatrogenically after surgery to remove the oral ranula/ sialoliths. [5] The cervical ranula appears as asymptomatic, enlarging, non tender, fluctuant mass lateral to the midline. The mass is not associated with thyroid gland. They have reported to extend up to retro pharynx, upper mediastinum. [14,15] The differential diagnosis of oral ranula occurring in floor of mouth encompasses a host of lesions like lipoma, hemangioma, dermoid cyst, salivary gland lesions, lymphangioma. The diagnosis is often a clinical one based on typical history & appearance of mass. Lipomas are rare intraorally usually occurring in the buccal mucosa, floor of mouth, tongue & clinically appears as yellow mass with encapsulation. This can be confirmed by putting the tissue in the water & if the lesion exhibits buoyancy it is confirm that the lesion is lipoma. [3, 4, 6] Hemangiomas are developmental lesions with deep red color exhibiting compressibility & blanching on palpation. On compression it can be emptied & refilling is seen. [3, 4] Mucocele are commonly seen in lower lip with a history of lip biting & size is smaller when compared to ranulas. Salivary gland lesions mainly the muco epidermoid, adenoid cystic carcinoma & polymorphous low grade adenoid cystic carcinoma occur in the floor of the mouth & these lesions typically exhibits pain & bleeding. [3,4,6] which are not seen in ranulas. Radiological methods like high resolution ultrasound or sonography is beneficial in detecting the salivary stones, abscess & cyst & help to evaluate 90% of benign versus malignant tumors. Vascular lesions can be more effectively demonstrated with assistance from color Doppler imaging. In detail imaging can be a guiding force for exact planning of surgery. Ultimately a biopsy may be required for accurate diagnosis. [2]

There are various modalities of treatment that be applied to treat the ranula. The treatment modalities include the

excision of the lesion with or without excision of ipsilateral sublingual gland, marsupialization, cryosurgery, CO₂ laser excision. A sublingual gland excision involves the potential risk for injury to the Wharton's duct, obstruction of sublingual gland, lingual nerve injury, recurrences & development of cervical ranula. In marsupialization there is unroofing of cyst, attaching the edges to neighboring tissue & then the cavity is ed with gauze. This treatment is associated with high recurrence rate. CO₂ laser is done with patient with good access to lesion & radiation who cannot tolerate the surgery. The treatment of choice is surgical excision [13, 16, 17]

CONCLUSION

Lesions in the floor of the mouth should be handled cautiously as there are variety of lesions both benign & malignant can raise an alarming situation. Ranula is one among the lesions occurring in the lateral part of floor of the mouth apart from lipoma, dermoid cyst vascular lesions & salivary gland lesions occurring due to rupture of the salivary duct. The prognosis of lesions depends upon the method of treatment approach adapted. Treatment modalities mainly the surgical removal along with the excision of the sublingual salivary gland is the preferred treatment option compared to marsupialization & other approaches as it has little recurrence rate & outcome is also better.

REFERENCES

1. Dr.Suman Jaishankar, Dr.Manimaran, Dr.Kannan, Dr.Christeffi Magel. Ranula- A case report. *JIADS*. 2010; 1(3):52
2. B Godhi, N Agarwal, P Verma, S Kumar Oral Ranula: An insight into pediatric dentistry. *Internet scientific publication*.2013; 1(11): 1-5
3. Shafer WG, Hine MK, Levy BM. A text book of oral pathology. Philadelphia: WB Saunders; 2009;6:543
4. Neville, Damm, Allen, Bouquot. Oral & Maxillo-facial Pathology. 2nd edition.2009.
5. Bardhan A, Dev PK, Banerjee S, Islam S. Plunging Ranula (Right Side): A case report. *Medicine Today*.2013;25(1):52-53.
6. MS Tan, B Singh. Difficulties in diagnosing lesions in the floor of the mouth- report of two rare cases. *Annals Academy of medicine* 2004; 33 (suppl):72s-76s.

7. Mark I Bous, Adam Cheng. Oral ranulas differential diagnosis. *Paediatric child health*. 2006 ;11(2):107-108.
8. Garofalo S, Briganti V, Cavallaro S, Pepe E, Prete M, Suteu L, et al.. Nickel Gluconate-Mercurius Heel-Potentised Swine Organ Preparations: a new therapeutical approach for the primary treatment of pediatric ranula and intraoral mucocele. *Int J Pediatr Otorhinolaryngol*; 2007; 71:247-55.
9. Onderoglu L, Saygan-Karamürsel B, Deren O, Bozdog G, Tekşam O, Tekinalp G. Prenatal diagnosis of ranula at 21 weeks of gestation: Ultrasound *Obstet Gynecol*. 2003;22:399-401.
10. Yuca K, Bayram I, Cankaya H, Caksen H, Kiroğlu AF, Kiriş M. Pediatric intraoral ranulas:-an analysis of nine cases. *Tohoku J Exp Med*; 2005;205:151-55.
11. Gul A, Gungorduk K, Yildirim G, Gedikbasi A, Ceylan Y. Prenatal diagnosis and management of a ranula. *J Obstet Gynaecol Res*; 2008; 34:262-65.
12. Zhao YF, Jia Y, Chen XM, Zhang WF. Clinical review of 580 ranulas. *Oral Surg Oral Med Oral Pathol Oral Radiol Endod*; 2004; 98:281-87.
13. Baurmash HD . A case against sublingual gland removal as primary treatment of ranulas. *J Oral Maxillofac Surg*; 2007; 65:117-21
14. Shellley MJ, Yeung KH, Bowley, Sneddon. A rare case of an extensive plunging ranula:disucsn of imaging, diagnosis & management. *oral surgery, oral medicine, oral pathology, oral radiology & endodontic*.2002,93:743-746
15. Ali MK, Chiancone G, Knox GW. Squamous cell carcinoma arising in plunging ranula. *Journal of oral & maxillofacial surgery*.1990;48;305-308.
16. McGurk M, Eyeson J, Thomas B, Harrison JD. Conservative treatment of oral ranula by excision with minimal excision of the sublingual gland-histological support for a traumatic etiology.*J Oral Maxillofac Surg*; 2008; 66:2050-57
17. McGurk M: Management of the ranula. *J Oral Maxillofac Surg*; 2007;65:115-16.

Source of Support: NIL

Conflict of Interest: None