

Document heading doi: 10.21276/apjhs.2016.3.1.25

Various discrepancies during development of tongue**Krishan Kumar Tyagi^{1*}, Manoj Kumar Upadhyay², Dilpreet Singh Grewal³, Khushboo Singh⁴
Debiprasad Ghatak⁵, Vikas Sharma⁶**¹ Department of Oral Pathology and Microbiology, M.B. Kedia Dental College, Birgunj, Nepal² Department of Conservative Dentistry, M.B. Kedia Dental College, Birgunj, Nepal³ Department of Prosthodontics, Genesis Institute of Dental Sciences And Research, Ferozpur⁴ Department of Community Dentistry, M.B. Kedia Dental College, Birgunj, Nepal⁵ Department of Oral Surgery, D.J College Of Dental Sciences & Research, Modinagar, India⁶ Department of Oral Pathology and Microbiology, D.J College of Dental Sciences & Research, Modinagar, India**ABSTRACT**

The tongue has a rich nerve supply and can detect not only the usual sensation of touch, pressure, heat and cold but also the special sensation of taste. This well developed sensory capability may be considered as a protective feature as it permits the tongue to 'review' substances before they pass into gastro intestinal tract. The tongue is important muscular organ which can also help in diagnosing various systemic diseases as many primary as well as secondary manifestation of various diseases can be seen on tongue. Changes of the tongue are sometimes diagnostically significant. In scarlet fever the atrophy of the lingual mucosa causes the peculiar redness of the strawberry tongue. Systemic disease such as pernicious anemia and vitamin deficiencies, especially vitamin B-complex deficiency, lead to characteristic changes such as magenta tongue and beefy red tongue. As dentists, we are the first to diagnose many systemic diseases by examining tongue. Thus, it is important to be aware of normal features as well as alteration in features for tongue.

Keywords: Macroglossia, Ankyloglossia, Geographic Tongue, Median Rhomboid Glossitis, Baby Tongue**Introduction**

Tongue is a mobile mass of striated muscle covered with mucous membrane situated in the oral cavity. It has multiple pin head sized papillae on its outer surface which aid in taste. The tongue is often cited as the "**strongest muscle in the body**," The word "tongue" is derived from the latin word "lingua" and greek word "glossa". It is partly oral (anterior 2/3rd of the tongue) and partly pharyngeal (1/3rd of the tongue). The tongue is the large bundle of skeletal muscles on the floor of the mouth that manipulates food for chewing and swallowing (deglutition) [1].

Correspondence*Dr. Krishan Kumar Tyagi**

Department of Oral Pathology and Microbiology, M.B. Kedia Dental College, Birgunj, Nepal

Email: krish.krish621@gmail.com**Tongue in health**

A normal tongue is an easily accessible organ for the assessment of health of an individual and shows the state of hydration of the body [2]. It is said that tongue is the mirror of the gastrointestinal system and any abnormal functioning of the stomach and intestines will be reflected on the tongue. Some characteristic changes occur in the tongue in some particular diseases. Thus, examination of the tongue is very essential part of initial oral examination [3]. As dentists, we are the first to diagnose many systemic diseases by examining tongue. Thus, it is important to be aware of normal features as well as alteration in features for tongue.

Disease tongue**Developmental**

- Microglossia
- Macroglossia
- Ankyloglossia
- Fissured Tongue

- Geographic Tongue
- Hairy Tongue
- Median rhomboid glossitis[4]

MICROGLOSSIA (HYPOGLOSSIA)

Microglossia is an uncommon developmental condition of unknown cause that is characterized by an abnormally small tongue [5]

- There is a large space round the edge of the tongue between it and the alveolar margin at the bottom of which the salivary glands can be seen through the mucous membrane of the floor of the mouth. The tongue cannot be protruded; muscular movements are present but very limited. The mucous membrane appears normal[6]

Treatment and Prognosis

Treatment of the patient with microglossia (baby tongue) depends on the nature and severity of the condition. Surgery and orthodontics may improve oral function. Surprisingly, speech development often is quite good but depends on tongue size [4,5]

MACROGLOSSIA

Macroglossia is an uncommon condition characterized by enlargement of the tongue. The enlargement may be caused by a wide variety of conditions including both congenital malformations and acquired diseases. The most frequent causes are vascular malformations and Muscular hypertrophy[7]

Clinical Features

Macroglossia most commonly occurs in children & can range from mild to severe in degree. In infants macroglossia may be manifested first by noisy breathing, drooling and difficulty in eating. The tongue enlargement may result in a lisping speech. The pressure of the tongue against the mandible and teeth can produce a crenated lateral border to the tongue, open bite, and mandibular prognathism[4,7] Individuals with Beckwith-Wiedemann syndrome have an increased risk for several childhood visceral tumors, including Wilms tumor, adrenal carcinoma and hepatoblastoma. Facial features may include nevus flammeus of the forehead and eyelids linear indentations of the earlobes and maxillary hypoplasia[7]

Histopathologic Features

The microscopic appearance of macroglossia depends on the specific cause. Histological studies of tissue taken from the tongue revealed the presence of an interstitial edema containing protein, but without evidence for mucopolysaccharides, glycogen or amyloid. A network of dilated blood and lymphatic vessels with partial stenoses caused by organized

thrombosis and proliferation of endothelial cells could be observed [5]

Treatment and Prognosis

The treatment and prognosis of macroglossia depend on the cause and severity of the condition. In mild cases, surgical treatment may not be necessary. Although speech therapy may be helpful if speech is affected. In symptomatic patients reduction glossectomy may be needed [5,7]

ANKYLOGLOSSIA (TONGUE-TIE)

Ankyloglossia, commonly known as tongue-tie is a congenital oral anomaly characterized by an abnormally short lingual frenulum[8]

Clinical Features

Ankyloglossia can range in severity from mild cases with little clinical significance to rare examples of complete ankyloglossia in which the tongue is actually fused to the floor of the mouth[5] Ankyloglossia in breastfeeding infants can cause ineffective latch, inadequate milk transfer, and maternal nipple pain, resulting in untimely weaning.[9] So, Ankyloglossia is a relatively common finding in the newborn population & represents a significant proportion of breastfeeding problems[8,9]

Treatment and Prognosis

Because most cases of ankyloglossia result in few or no clinical problems. Treatment is often unnecessary. If there are functional or periodontal difficulties, a frenectomy may allow greater freedom of tongue movement.[5,8,9]

FISSURED TONGUE (SCROTAL TONGUE)

It also termed lingua fissurata, lingua plicata, scrotal tongue and grooved tongue is recognized clinically by an groove oriented anteroposteriorly, often with multiple branch fissures extending laterally. The frequency is increases with age and has been associated with psoriasis, acromegaly, and Sjogren's, Down's and Melkersen-Rosenthal syndromes[10]

Clinical Features

Patients with fissured tongue exhibit multiple grooves, or furrows, on the surface of the tongue. ranging from 2 to 6 mm in depth. severe cases, numerous fissures cover the entire dorsal surface and divide the tongue papillae into multiple separate "islands." Most studies have shown that the prevalence of fissured tongue ranges from 2% to 5% of the overall population. The condition may be seen in children or adults, but the prevalence and severity appear to increase with age.[4,10]

Histopathologic Features

Microscopic examination of fissured tongue reveals hyperplasia of the rete ridges and loss of the keratin "hairs" on the surface of the filiform papillae. Polymorphonuclear leukocytes can be seen migrating into the epithelium, often forming microabscesses in the upper epithelial layers. A mixed inflammatory cell infiltrate is present in the lamina propria [5].

Treatment and Prognosis

Fissured tongue is a benign condition, and no specific treatment is indicated. The patient should be encouraged to brush the tongue, because food or debris entrapped [5].

GEOGRAPHIC TONGUE

Geographic tongue (lingua geographica), also known as benign migratory glossitis or annulus migrans, is an inflammatory disorder of unknown etiology caused by local loss of filiform [11].

Clinical Feature

The condition usually presents as asymptomatic erythematous patches with serpiginous borders [10]. The patches are irregular and sharply demarcated, resembling a map; dorsal surface of the tongue is the site that is usually affected. Geographic tongue begins with a depression on the lateral border or tip of the tongue smoother and redder than the rest of the tongue surface [11].

Treatment

The condition is benign and localized generally requiring no treatment except reassurance. Some patients may have sensitivity to hot or spicy foods. Topical steroid gels and antihistamine mouth rinses can reduce tongue sensitivity [12].

HAIRY TONGUE (BLACK HAIRY TONGUE)

Hairy tongue is characterized by marked accumulation of excess keratin on the filiform papillae of the dorsal tongue leads to the formation of elongated strands that resemble hair. The color of the tongue can range from white or tan to black. Darker coloration results from the trapping of debris and bacteria in the elongated strands. This occurs most commonly in smokers and in persons with poor oral hygiene [12].

Clinical Features

Hairy tongue most commonly affects the midline just anterior to the circumvallate papillae, sparing the lateral and anterior borders. The elongated papillae are

usually brown, yellow or black as a result of growth of pigment-producing bacteria or staining from tobacco and food [4,5]

Histopathologic Features

On histopathologic examination, hairy tongue is characterized by marked elongation and hyperparakeratosis of the filiform papillae. Usually numerous bacteria can be seen growing on the epithelial surface [5].

Treatment and Prognosis

Hairy tongue is a benign condition with no serious sequelae. The major concern is often the aesthetic appearance of the tongue along with possible associated bad breath. Keratolytic agents such as podophyllin also have been tried with success, but for safety reasons their use probably should not be encouraged [5].

MEDIAN RHOMBOID GLOSSITIS

It is a diamond shaped, elevated inflammatory lesion of the tongue covered by smooth red mucosa. It is situated anterior to the circumvallate papillae, at about the junction of the anterior two-third and posterior one-third of the tongue [13].

Clinical feature

Median rhomboid glossitis presents in the posterior midline of the dorsum of the tongue, just anterior to the V-shaped grouping of the circumvallate papillae. It occurs as a well-demarcated, symmetric, depapillated area arising anterior to the circumvallate papillae. However, it sometimes appears in the paramedial location. While most of the cases are asymptomatic, some patients complain of persistent pain, irritation, or pruritus. When MRG is concomitant with a palatal inflammation, which is called the *kissing* lesion [14].

Histologic features

It shows a smooth and nodular surface covered by atrophic stratified squamous epithelium overlying a moderately fibrosed stroma with somewhat dilated capillaries. A mild to moderate intense chronic inflammatory cell infiltrate may be seen with in subepithelial and deeper fibrovascular tissue. The most important diagnostic clue is the presence of candidal hyphae in the superficial epithelium. Providing a photograph of the clinical appearance of the lesion is another tool to assist the pathologist in an accurate diagnosis [14,15]

Treatment and Prognosis

No treatment is necessary for median rhomboid glossitis. But nodular cases are often removed for microscopic evaluation. Antifungal therapy will reduce clinical erythema and inflammation due to candida infection [5].

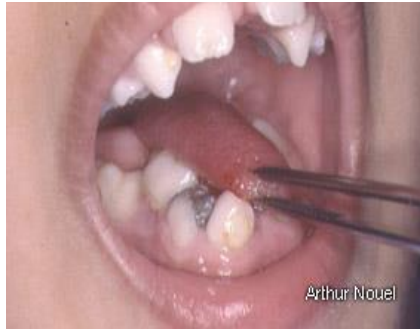

Fig 1:Microglossia

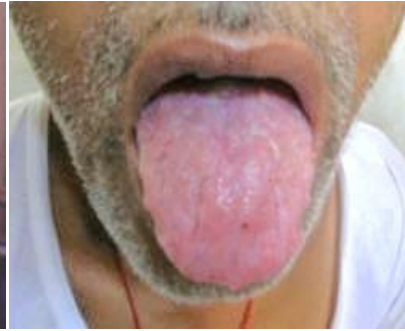

Fig 2:MacroGLOSSIA

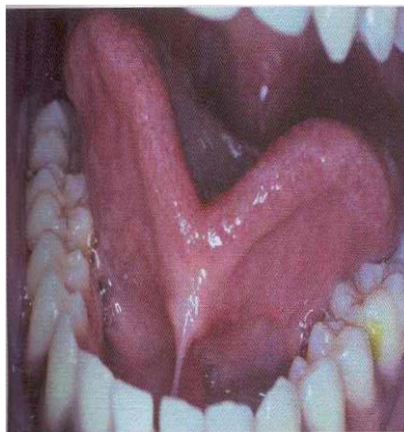


Fig 3: Ankyloglossia

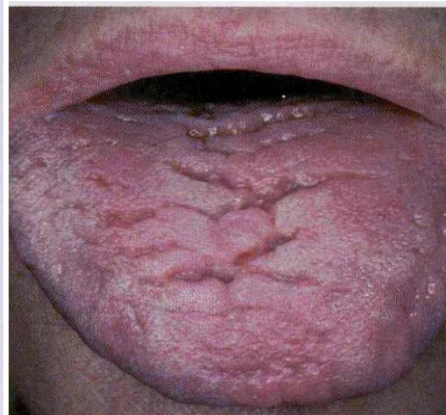

Fig 4:Fissured tongue

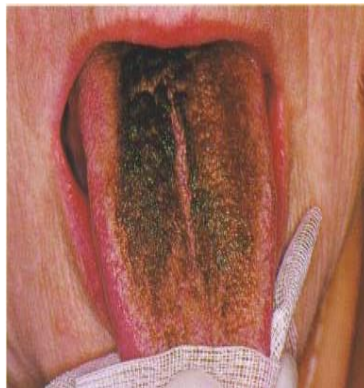

Fig 5:Hairy tongue

Conclusion

The tongue is very active and extremely sensitive organ, performing on a complex muscle background. Basic functions of the stomatognathic system such as

mastication, deglutition and speech, require the active involvement of it in order to be carried out. The characteristics which detect the functional performance

of the tongue size, strength state of health, movement patterns and resting position. These characteristics, primarily the resting position, are also important during growth of the oral structures

Reference

1. Susan Standing.. Gray's Anatomy. The Anatomical Basis of Clinical Practice. Oral Cavity. Elsevier's Publication. Spain; ed 39th 2005:581-601
2. pain-help.blogspot.com/2010/01/tongue-diseases.html.whyhealthylifestyle.blogspot.com/2015_11_01_archive.html
3. Ghom G A. Textbook of Oral Medicine. Jaypee Brothers Medical Publishers (P) Ltd, New Delhi. ed 3rd.2016.
4. Neville W B, Damm D Douglas, Allen M C, Bouquot J E. Oral & Maxillofacial Pathology . Developmental Defects of the Oral and Maxillofacial Region. Reed Elseviers India Private Limited. Gurgaon. India ; ed 4th 2016:8-9
5. [http://www. Pocket dentistry.com/1-developmental-defects-of-the-oral-and-maxillofacial- region](http://www.Pocketdentistry.com/1-developmental-defects-of-the-oral-and-maxillofacial-region).
6. <http://www.gutenberg.us/article/whebn0001965394/macroglossia>.
7. Anna H. Messner, M. Lauren Lalakea, Janelle Aby. Ankyloglossia Incidence and Associated Feeding Difficulties. Arch Otolaryngol Head Neck Surg. 2000;126(1):36-39.
8. Jeanne L. Ballard,Christine E. Auer, RN, IBCLC and Jane C. Khoury . Ankyloglossia: Assessment, Incidence, and Effect of Frenuloplasty on the Breastfeeding Dyad . Pediatrics 2002;110:e63.
9. Crispian Scully , Martin Dunitz . Hand Book of Oral Disease, Diagnosis And Management. Taylor & Francis, United Kingdom.2001: 51
10. Zargari O . The prevalence and significance of fissured tongue and geographical tongue in psoriatic patients . Clinical and Experimental Dermatology, 31(2): 192-195.
11. Tuba Çelebî Kayhan , Cemal Bılaç , Dilek Bayraktar Bılaç . Annular Plaques on the Tongue: What Is Your Diagnosis? . Ann Dermatol. 2011; 23(4): 548-550
12. Brian V. R. Common Tongue Conditions in Primary Care. Am Fam Physician. 2010; 81(5):627-634.
13. Deshpande RB, Bharucha MA. Median rhomboid glossitis: secondary to colonisation of the tongue by Actinomyces (a case report). J Postgrad Med 1991;37:238
14. Mustafa Goregen, Ozkan Miloglu , Fatma Caglayan.Median rhomboid glossitis :A Clinical and Microbiological Study . Eur J Dent. 2011; 5 (4): 367-372.

Source of Support: Nil

Conflict of Interest: None