

---

**Tooth extraction, immediate implant placement: a case report**

Nezar Watted, Mohamad Watad, Abdulgani Azzaldeen, Abu-Hussein Muhamad\*

*Center for Dentistry research and Aesthetics, Jatt/Israel*

---

**ABSTRACT**

The Esthetics and functional integrity of the periodontal tissues may be compromised by dental loss. Implant has become a wide option to maintain periodontal architecture. Diagnosis and treatment planning is the key factors in achieving the successful outcomes after placing and restoring implants placed immediately after tooth extraction. This case report describes the procedure of placement of implant in the anterior teeth region after immediate extraction.

**Keywords:** Extraction, Immediate implant, osseointegration

---

**Introduction**

During the 70 years when the osseointegration was introduced, the oral implants were used predominantly on the edentulous patient rehabilitation and the aim was the stomatognathic system function devolution thus contributing positively to restore the patient's psychosocial. During those years the predictable and long term results evidences make extensive this practice to the partial edentulous patients [1].

The implant restoration with an acceptable outcome depends on the correct tri dimensional implant placement as well all the tissue architecture that surrounds the implant. In order to succeed in a peri-implant aesthetic with single unit implants is a challenge as well the maintenance.[2]

Since a good foundation is necessary several reports tried to classify the bone defect to make easy the decision for a better treatment option.

In 2007, Elian *et al.* [3] proposed a classification system for extraction sockets where they evaluated the soft tissue and buccal bone pos-extraction;

**Type I Socket:** Easiest and predictable. The soft tissue and the buccal bone are at the normal level and remain after the extraction.

**Type II Socket:** Are often difficult to diagnose and sometimes are treated as a type I by the inexperienced clinician. Facial soft tissue is present but the buccal plate part is missed after the extraction.

**Type III Socket:** Very difficult to treat and requires bone augmentation and CT grafts. The soft tissue and the buccal plate are both markedly reduced after tooth extraction [4].

Funato *et al.* [4] described in their article the importance of the timing or the "forth dimension" relative to extraction and implant placement. The timming of tooth extraction and implant placement was classified as follow;

**Class I:** Immediate – extraction, immediate implant placement flapless or with a flap and osseous augmentation with GBR and ct graft.

**Class II:** Early implant placement (6-8 weeks) – GBR can be performed at the moment of the extraction or when the implant will be placed

**Class III:** Delayed Implant placement- 4 to 6 months after the extraction with the preservation of the alveolar ridge with GBR as well soft tissue augmentation [4].

According with Jovanovic [5], there are 5 keys that lead us to a quality implant survivor:

- 1) Bone preservation / regeneration
- 2) Implant surface / design /position
- 3) Soft tissue thickness support
- 4) Prosthetic tissue support

---

\*Correspondence

**Abu-Hussein Muhamad**

Department of Pediatric Dentistry,

Athens, Greece

**E-mail:** [abuhusseinmuhamad@gmail.com](mailto:abuhusseinmuhamad@gmail.com)

### 5) Restorative emergence and material

During the 2000 years, more than 20 years of implant therapy, several studies showed us the importance of a biological driven therapy. As these studies demonstrated that there are specific indications to do an immediate implant placement otherwise the outcome will be compromised. To achieve the optimal aesthetic and functional results, the clinicians must analyze what is lost in the implant site and be prepared to rebuild it[6,7]. Dental implants can be placed in fresh sockets immediately after tooth extraction. These are called "immediate" implants. "Immediate-delayed" implants are those implants inserted after one or more weeks, up to a month or more, to allow for soft tissue healing. "Delayed" implants are those placed thereafter in partially or completely healed bone. The advantage of immediate placed implants is the shortened treatment time. Bone height will be maintained thus improving implant bone support and aesthetic results[7]. The extraction socket can have an implant placed immediately after a CHRONICALLY infected tooth is removed, but needs to have the replacing implant anchored into bone and the site grafted at the same time with a PTFE membrane that excludes soft tissue, allowing the bone grafted socket site to heal normally with the newly placed implant.[7,8]

### Indications of immediate implantation

Primary implantation is fundamentally indicated for replacing teeth with pathologies not amenable to treatment, such as caries or fractures. Immediate implants are also indicated simultaneous to the removal of impacted canines and temporal teeth.[1,4,7,8]

Immediate implantation can be carried out on extracting teeth with chronic apical lesions which are not likely to improve with endodontic treatment and apical surgery. *et al.*, in a study in dogs, inserted immediate implants in locations with Novae's chronic periapical infection.

These authors reported good results and pointed out that despite evident signs of periapical disease, implant placement is not contraindicated if pre- and postoperative antibiotic coverage is provided and adequate cleaning of the alveolar bed is ensured prior to implantation.[3,4,7,8]

While immediate implantation can be indicated in parallel to the extraction of teeth with serious periodontal problems, Ibbott *et al.*, reported a case involving an acute periodontal abscess associated with immediate implant placement, in a patient in the maintenance phase.[1,4,7,8]

### Contraindications

The existence of an acute periapical inflammatory process constitutes an absolute contraindication to immediate implantation.[4,7,8,]

In the case of socket implant diameter, discrepancies in excess of 5 mm, which would leave most of the implant without bone contact, prior bone regeneration and delayed implantation may be considered[7,8].

### Advantages

One of the advantages of immediate implantation is that post extraction alveolar process resorption is reduced, thus affording improved functional and esthetic results.

Another advantage is represented by a shortening in treatment time, since with immediate placement it is not necessary to wait 6-9 months for healing and bone neoformation of the socket bed to take place.[4,7,8,7,8] Patient acceptance of this advantage is good, and psychological stress is avoided by suppressing the need for repeat surgery for implantation[4,7,8].

Preservation of the vestibular cortical component allows precise implant placement, improves the prosthetic emergence profile, and moreover preserves the morphology of the peri-implant soft tissues; thereby affording improved esthetic-prosthetic performance. [7-8].

### Case report

45 years with a compliant of mobility in the upper & lower front teeth region. On medical examination she is hypertensive and under medication for the past. On dental examination he had grade 2 mobility in relation to 12,12,21, This patient had implants placed by me in 14 area and 46 area a couple of years ago. At that time I discussed his issues with the anterior teeth but finances did not allow comprehensive treatment. He began having symptoms with the anteriors and with the success of the posterior implants he was "primed" for the esthetic zone. It was diagnosed as generalized chronic periodontitis.

### Treatment planning

On Investigation routine blood examination was done. Random blood sugar was 102.0mg/dl. On radiographic evaluation, CBCT revealed generalized horizontal bone loss and digital radiovisiography was taken in the region to observe the remaining bone height and bone width.(Figure1)

### Clinical and laboratory procedures

- Diagnostic impression was taken using alginate hydrocolloid impression material.
- Study cast model was prepared.

Preparing a template: To determine the planned implant position in the jaw, a planning template is fabricated for the patient and subsequently used to become a radiographic and drill template. Initial phase I therapy was performed. Subgingival scaling and root planning was done in all the quadrants and patient was reviewed after

4 weeks, Re-evaluation of phase I therapy was done which include evaluation of gingival condition and periodontal status.[7,8]

### Surgical procedure

Phase II therapy was planned, extraction of teeth 12,11and 22 was done under local anaesthesia. Flap surgery has been done after the extraction of the mobile anterior teeth region(Figure2,3 ).

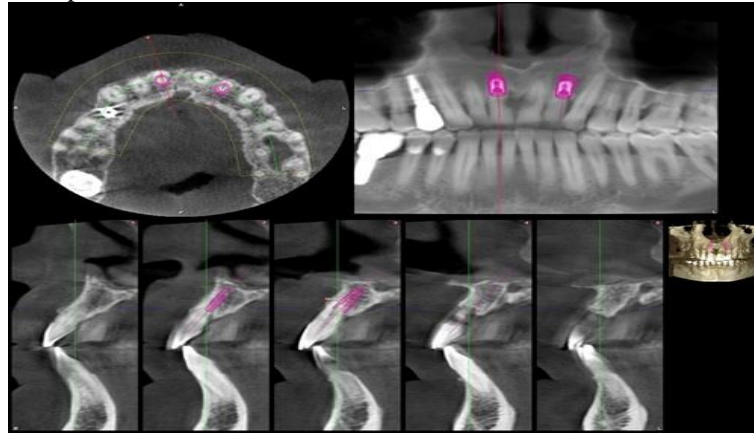

Figure1: Initial CBCT , the implants in 14 and 46

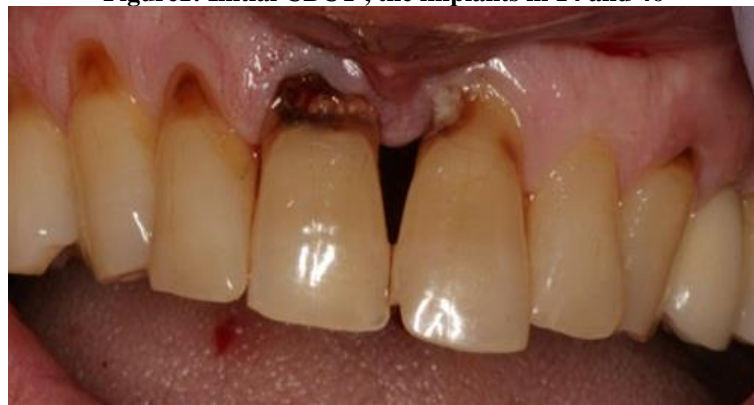

Figure2:Pre-op condition. Exposed metal margin and hopeless tooth

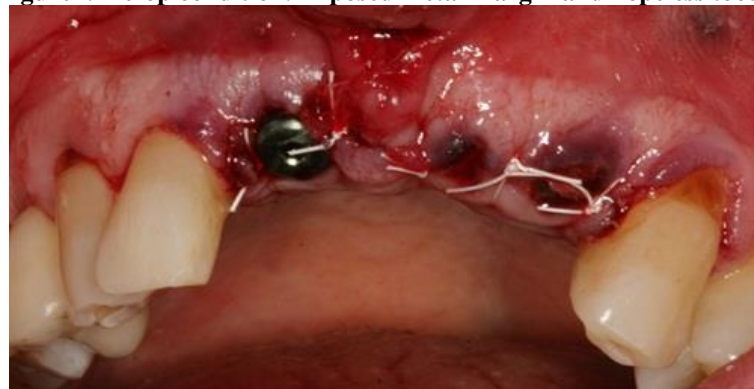

Figure3: Extraction and placement

### Steps involved in surgical procedure

Patient was prepared and draped. Infiltration was given with local anaesthesia in the region of 12,11,21 region. The area infiltrated with local anaesthesia is checked. Paracrestal incision was made in the region. Full thickness mucoperiosteal flap is reflected on the buccal and lingual region 12,11&21. Osteotomy site was marked. Initial drilling was done with round bur, ideal angulation is perpendicular to the plane of occlusion and corresponds to the cingulum of the teeth.

A Small 1.5 mm diameter and cutting drill is used to continue with the bone preparation. Parallel pin is placed in the drill hole to check the angulation in the labiolingual direction and in mesiodistal direction. Drilling was done in sequential manner with 2.0mm, 2.5mm, and 3 mm respectively in both the region i.e 12,21,. Implant site is flushed with normal saline to remove any debris and suctioned. 3.75 Diameter & 13mm length implant was placed on both the prepared osteotomy site. In the maxillary anterior teeth it is

important to avoid placing implant directly in to the extraction socket, otherwise, the implant will invariably perforate the buccal plate and jeopardize the implant survival. The axis of the implant is placed correspond to the incisal edge of the adjacent teeth or be slight palatal to this land mark. In the esthetic zone, Implant head should be minimum of 3mm apical to the imaginary line connected to the cemento-enamel junctions of the adjacent teeth and

apical to interproximal and crestal bone. Torque should be also considered for the implant stability. Torque resistance of 40 Newton centimeters is a indicative of initial implant stability (Figure 4,5,6).

The patient was recalled after four months for the prosthetic procedures and was given porcelain fused to metal crown over the implant. He was recalled for prophylaxis and follow up every three months. The clinical and radiographic appearances at six months and after one year show good aesthetic result and acceptable osseointegration of the implant (Figure 7,8,9).

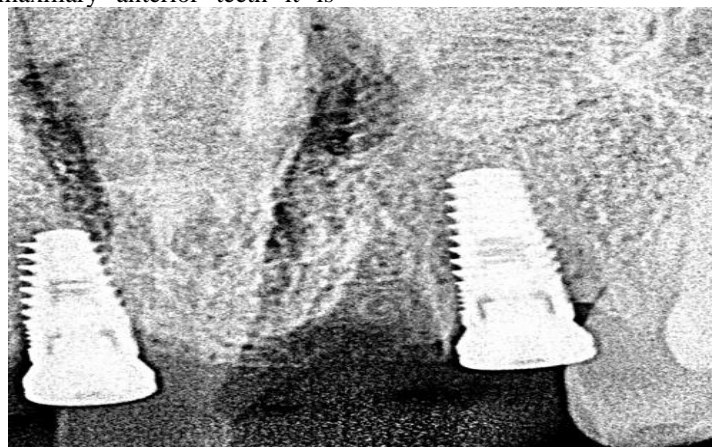


Figure4: X-ray taken

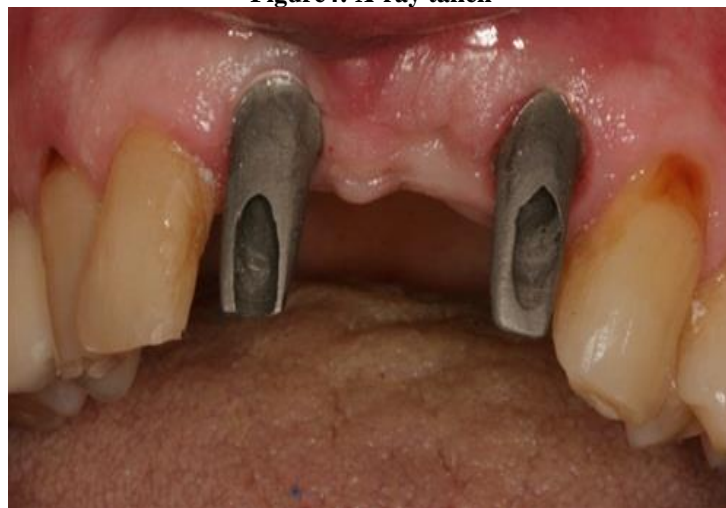
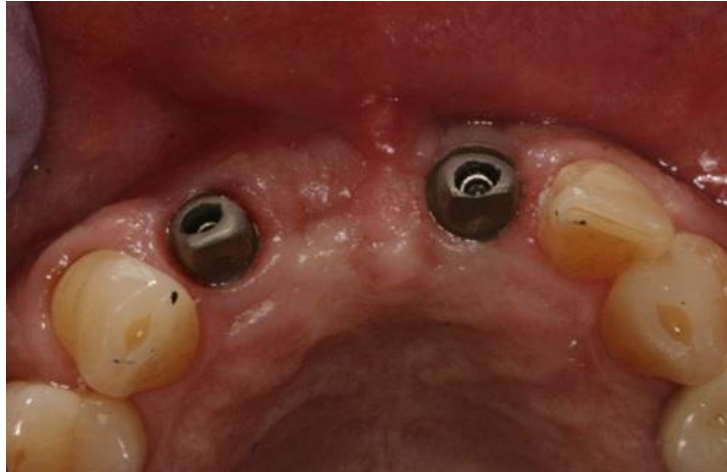
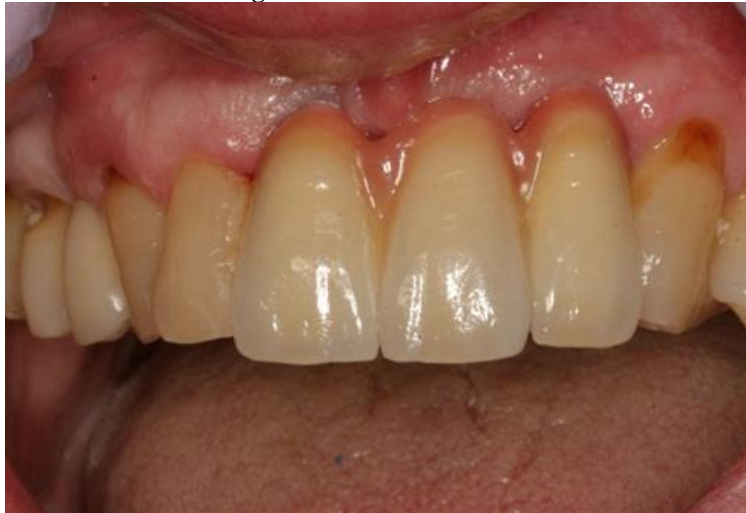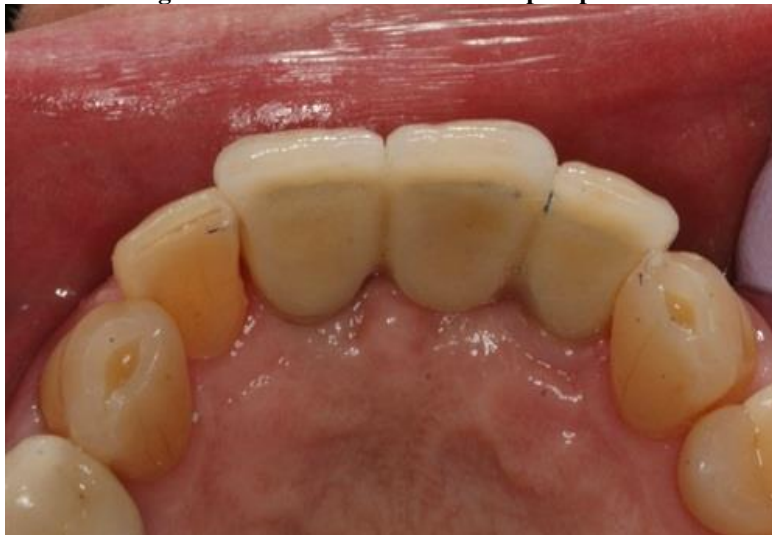Figure5: Placement would not allow screw retained bridge UCLA cast on gold



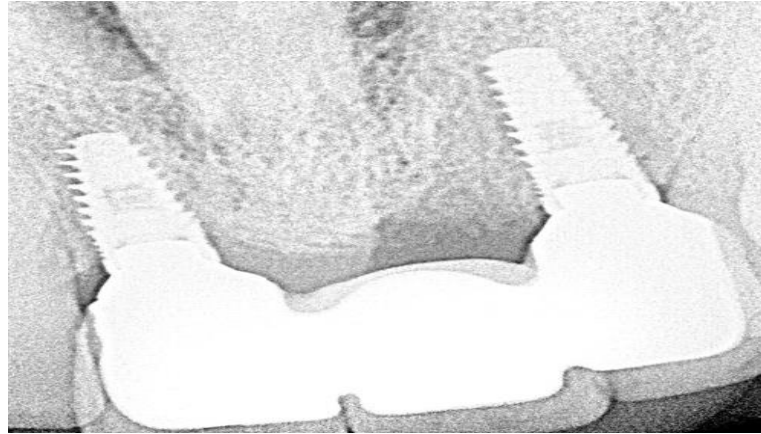
**Figure6: Abutment in Situ**



**Figure7: Cement retained -----zinc phosphate.**



**Figure8: Occlusal**



**Figure 9:X-RAY after one year**

## Discussion

Implant placement subsequent to tooth extraction in conjunction with the use of provisionals in the anterior maxillary region is certainly challenging for the dental practitioner[9]. However, this treatment modality offers several advantages, including reduced clinical time, a single local anesthetic injection, a flapless procedure and immediate placement of the implants. From the patient's point of view, the immediate incorporation of a fixed implant supported provisional restoration is very acceptable and even requested. With the clinical procedure described here, both dentist and patient can evaluate the aesthetics of the restoration. Soft-tissue support is enhanced and achievement of the desired result is facilitated. With initial implant stability, proper tissue management and correct use of the available implant components, a predictable aesthetic result can be produced. On the other hand, occlusal control, oral hygiene and a regular recall programme should be considered prerequisites for maintaining a long-lasting restoration[10,11].

Single-tooth implants have shown high success rates in both the anterior and the posterior regions of the maxilla and the mandible.[1-4] Immediate post extraction implant placement has been done since the early years of the clinical application of implants with very good clinical outcomes. Decisive factors for immediate implant placement are lack of infection in the periodontal tissues and an intact tooth socket. Immediate incorporation of a temporary restoration has been presented in the literature with most encouraging results[7,8,12]. Although clinical experiences have advocated this clinical technique for many years, more extended long term clinical studies are necessary to prove the efficacy of the method and establish a stable clinical protocol[8,13,14].

## Conclusion

The implant therapy must fulfill both functional and esthetic requirements to be considered a primary treatment modality. Aiming to reduce the process of alveolar bone resorption and treatment time, the immediate placement of endosseous implants into extraction sockets achieved high success rate of between 94-100%, compared to the delayed placement.

## Acknowledgment

The authors would like to thank: Setergiou Bros Dental Laboratory, Athens, Greece; for the fabrication of the ceramic restorations.

## References

1. Van Steenberghe D, Lekholm U, Bolender C, Folmer T, Henry P, *et al.* Applicability of osseointegrated oral implants in the rehabilitation of partial edentulism: a prospective multicenter study on 558 fixtures. *Int J Oral Maxillofac Implants* 1999, 5(3): 272-281
2. Kan JYK, Rungcharassaeng K ;Site development for anterior implant esthetics: the edentulous site. *Compend Contin Educ Dent* 2001;22(3): 221-232.
3. Elian N, Cho SC, Froum S, Smith RB, Tarnow DP. A simplified socket classification and repair technique. *Pract Proced Aesthet Dent* 2007,19(2): 99-104.
4. Funatoa A, Salama MA, Ishikawa T, Garber DA, Salama H ;Timing, positioning, and sequential staging in esthetic implant therapy: a four-dimensional perspective. *Int J Periodontics Restorative Dent* 2007,27(4): 313-323.

5. Jovanovic SA. Esthetic therapy with standard and scalloped implant designs: the five biologic elements for success. *J Calif Dent Assoc* 2005, 33(11): 873-880.
6. Jovanovic SA. Bone rehabilitation to achieve optimal aesthetics. *Pract Proced Aesthet Dent* 2007,19(9): 569-576.
7. Abu-Hussein M., Abdulghani A., Sarafianou A., Kontoes N.; Implants into fresh extraction site: A literature review, case immediate placement report, *Journal of Dental Implants*. 2013;3(2):160-164
8. Bajali M., Abdulgani Azz., Abu-Hussein M, Extraction and immediate implant placement, and provisionalization with two years follow-up: a case report, *Int J Dent Health Sci* 2014; 1(2): 229-236.
9. Calvo JL, Muñoz EJ. Implantes inmediatos oseointegrados como reemplazo a caninos superiores retenidos. Evaluación a 3 años. *Rev Europea Odontostomatol* 1999; 6:313-20.
10. Novaes-Junior AB, Novaes AB. Soft tissue management for primary closure in guided bone regeneration: surgical technique and case report. *Int J Oral Maxillofac Implants* 1997;12:84-7
11. Novaes-Junior AB, Novaes AB. Immediate implants placed into infected sites: a clinical report. *Int J Oral Maxillofac Implants* 1995;10:609-13.
12. Coppel A, Prados JC, Coppel J. Implantes post-extracción: Situación actual. *Gaceta Dental* 2001;Sept.120:80-6
13. Strub JR, Kohal RJ, Klaus G, Ferraresso F. The reimplant system for immediate implant placement. *J Esthet Dent* 1997; 9:187-96
14. Gelb DA. Immediate implant surgery: ten-year clinical overview. *Compendium of Cont Educ Dent* 1999;20:1185- 92

**Source of Support: NIL**

**Conflict of Interest: None**