

Riedel's thyroiditis presenting as large retropharyngeal goiter - A rare case

Bushra Khan*, Ravi Ganji, Bhima Linga Prasad

Department of General Surgery, Deccan College of Medical Sciences, Hyderabad, Telangana, India

ABSTRACT

The thyroid gland lies in the anterior triangle of the neck in close approximation to the larynx and the trachea. The extension of an enlarged thyroid gland outside the normal confines of the thyroid bed is well known. A 35-year-old woman presented with a 12-year history of swelling in the midline of the neck which progressively increased in size and was currently associated with symptoms of dysphagia, difficulty in breathing, and hoarseness of voice. Physical examination revealed an ill-defined neck swelling moving on deglutition, with a bosselated surface with no overlying skin changes. Contrast-enhanced computed tomography scan of the neck revealed para- and retro-pharyngeal goiter with extension up to base of the tongue. Retropharyngeal extension of goiter is thought to be a rare entity in itself as shown in literature, but a large retropharyngeal goiter in Riedel's thyroiditis has not been described before and seems to depend mainly on the body habitus of the patient.

Key words: Fibrozing variant of Hashimoto's thyroiditis, imaging, retropharyngeal goiter, Riedel's thyroiditis

INTRODUCTION

Goiters (from the Latin word guttur, throat), defined as an enlargement of the thyroid, have been recognized since 2700 B.C. even though the thyroid gland was not documented as such until the renaissance period.^[1] The thyroid gland lies in the anterior triangle of the neck in close approximation to the larynx and trachea. It is invested within pre-tracheal fascia and is attached to the trachea by the ligament of Berry. Posteriorly, the gland reaches the esophagus and carotid sheath. The pre-tracheal fascia is continuous inferiorly with the mediastinum, but superior extension of the thyroid gland is limited by the superior attachment of pre-tracheal fascia, Berry's ligament, and the attachment of the strap muscles explaining its common retrosternal extension rather than supralaryngeal growth.^[2]

The anatomical arrangement of the strap muscles, Berry's ligament, and the neck spaces largely influences the direction of enlargement of the thyroid gland.

The extension of an enlarged thyroid gland outside the normal confines of the thyroid bed is well documented.^[3] The levels of the normal thyroid bed were defined as being situated between the cranial level of mid-thyroid cartilage and the caudal level of the fourth tracheal cartilage. Each lobe is 5 cm long, its greatest transverse and anteroposterior extents being 3 cm and 2 cm, respectively.^[4]

CASE HISTORY

A 35-year-old woman presented with a 12-year history of swelling in the midline of the neck which progressively increased in size and was currently associated with symptoms of dysphagia, difficulty in breathing, and hoarseness of voice. She had a H/o decrease in appetite but no H/o weight gain. H/o menorrhagia, lethargy, and excessive sleep were present. Physical Examination revealed a diffuse goitre with ill-defined lower margin and kyphoscoliotic spine. Kocher's test was positive. Pemberton's sign was negative.

No lymph nodes were palpable in the neck region.

Cardiovascular, respiratory, and abdominal examination was normal.

Contrast-enhanced computed tomography scan of the neck gave the impression of diffuse thyromegaly involving both the lobes and isthmus of the gland with homogenous enhancement and extensive retropharyngeal extension [Figure 1]. No focal lesions and no calcifications were noted, likely to be thyroiditis (both lobes are extending superiorly up to the submandibular regions and inferiorly up to the level just above the medial ends of clavicles). Mild compression of the hypopharynx by the enlarged lobes of the thyroid gland was noted. Blood investigations revealed overt hypothyroidism. Hence, the patient started on 150 Ugm of thyroxine and asked to be reviewed after 3 weeks.

Address for correspondence:

Bushra Khan, Room no. 205, PG Girls Hostel, Owaisi Hospital and Research Centre, KanchanBagh, Hyderabad – 500 058, Telangana, India. Phone: +91-9892540555. E-mail: bkkhanbushi@gmail.com

Received: 20-01-2018

Revised: 10-02-2018

Accepted: 12-03-2018

Indirect laryngoscopy showed normal cord movements on either side.

Fine-needle aspiration cytology (FNAC) was suspicious of findings of Hashimoto's thyroiditis.

The patient was admitted for surgery after thyroid profile values returned to normal.

The patient was given general anaesthesia and put in the supine position with the neck slightly extended, as extension was restricted due to ankylosing spondylitis.

After raising the subplatysmal flaps, deep fascia was divided in the midline, and strap muscles (both sternohyoid and sternothyroid) were divided at the junction of upper- and middle-third of the gland. Superior thyroid vessels were found splayed over enlarged superomedial portion of the lobes which were ligated close to the gland. Upper lobe with its retropharyngeal extension was dissected and teased out with blunt gauze dissection from larynx, pharynx, and esophagus. Middle thyroid vein and inferior thyroid artery branches were ligated close to the gland after identifying and preserving both recurrent laryngeal nerves which were enclosed in fibrous strands.

Gland was found densely adherent to the trachea probably due to inflammation (thyroiditis) which was released by careful electrocautery dissection. One parathyroid gland could be identified and preserved. Hemostasis was secured and wound closed in two layers. Intraoperative procedure was uneventful [Figure 2].

Intraoperative findings included hard goiter involving both the lobes and completely encircling the trachea and larynx extending superiorly up to the base of the tongue and inferiorly the manubrium sterni. The right lobe had a deeper and more posterior extent compared to the left lobe [Figure 3].

Postoperatively, the patient developed symptoms of hypocalcemia on day 1 and was treated with calcium gluconate injections and Vitamin D. MgSO4 infusion was added for persistent hypocalcemia and symptoms were relieved by POD5.

The histopathology report of the post-thyroidectomy specimen was S/o Riedel's thyroiditis.

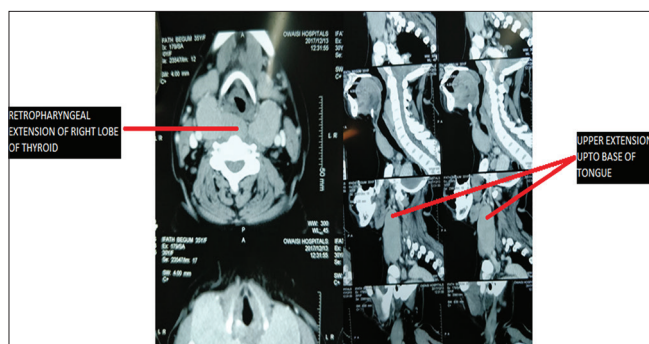


Figure 1: Contrast-enhanced computed tomography neck showing diffuse thymegaly with mild compression of the hypopharynx

DISCUSSION

The development of multinodular goiter is believed to be caused by long-lasting stimulation of thyroid-stimulating hormone during a period of suboptimal production of thyroid hormones. This stimulation leads to epithelial hyperplasia, which is often followed by involution. Both these changes result in diffuse goiter.

Nodular goiter is usually regarded as an end stage of diffuse goiter, resulting from cyclic changes of hyperplasia and involution.^[5]

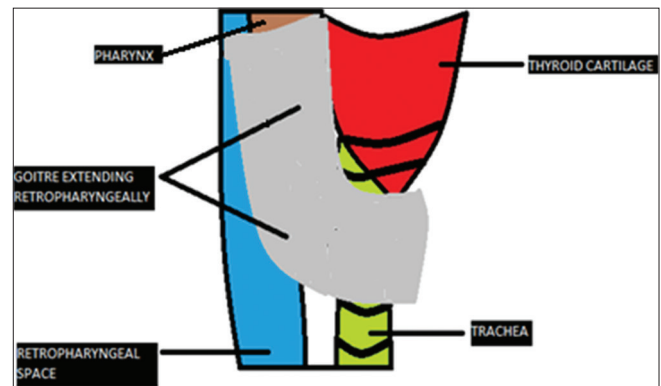


Figure 2: The enlarged thyroid gland with a retropharyngeal extension as visualized intraoperatively

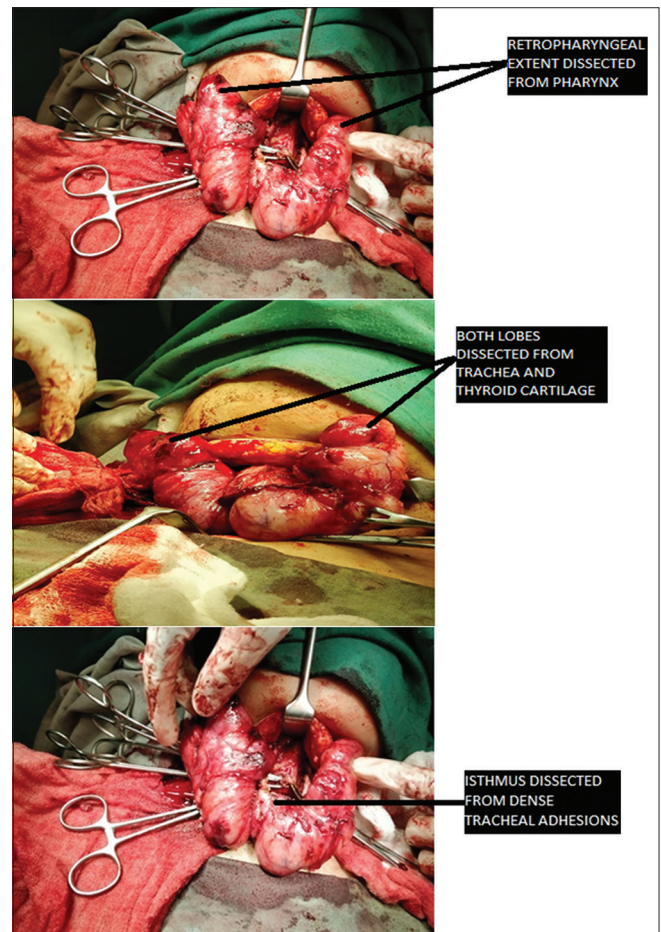


Figure 3: Diagrammatic representation of retropharyngeal goiter

Hashimoto's disease contributes the most common cause of goitrous hypothyroidism in adults. The disease arises most commonly in patients between 30 and 50 years of age with a female-to-male ratio of 8–10:1.

The enlargement is usually symmetrical but in some it may have a nodular quality with one lobe being substantially larger than the others. It is firm, rubbery but never stony hard as in Riedel's disease.

Histologically, the dominant feature is a massive lymphoplasmacytic infiltration of the thyroid parenchyma. The follicular epithelium shows a widespread oncocyctic change. This combination of numerous lymphocytes and oncocytes is important for the cytological diagnosis of this disorder on FNAC.^[6]

Riedel's thyroiditis is a rare disorder described by Riedel in 1896 and is characterized by extensive fibrosis replacing the thyroid tissue. The lesion, which is extremely firm, binds the soft tissues of the neck in an iron collar and involves only localized areas of the thyroid gland.

Microscopically, fibrous tissue that is frequently extensively hyalinized completely replaces the area of the gland involved.^[7]

Histologically, the other main disorder in the differential diagnosis is the fibrous variant of Hashimoto's thyroiditis which is limited to the thyroid, distinctly lobulated, and accompanied by extensive oxyphilic changes of the follicular epithelium. Riedel's and Hashimoto's thyroiditis do not appear to be related despite the occasional coexistence of the two.^[6,7]

Almost all the cases of retropharyngeal goiter reported previously in literature are multinodular goiters^[2,8,9] with one large study failing to mention the pathology of the goiter.^[3]

In our case, even though the thyroid gland was very hard and adherent to the trachea intraoperatively, no fibrous adhesions or infiltration into the adjacent strap muscles was noted as is described for Riedel's thyroiditis.^[7]

Both the lobes of the gland were almost uniformly enlarged and completely encircling the thyroid cartilage and pharynx as is usually described for a fibrous form of Hashimoto's thyroiditis.

Hence, our case may be one of the rare instances where fibrous form of Hashimoto's and Riedel's thyroiditis coexist in the same patient.^[6,7]

Another point that needs to be stressed in our article is the importance of imaging investigations specifically CT scan in diagnosing the retropharyngeal extension (as ultrasonography neck failed to reveal the same) which was necessary to plan the surgery and assess the need for post-operative airway management;^[10] in the present case, with superior thyroid vessels entering the gland at the junction of lobe and isthmus anteriorly, almost in the lower one-third of the lobe rather than at apex as

is commonly noted in small goiters, the need for proper pre-operative evaluation cannot be overemphasized.^[9,11-13]

CONCLUSION

Retropharyngeal extension of goiter is thought to be a rare entity in itself as shown in literature, but a large retropharyngeal goiter in Riedel's thyroiditis has rarely been described before. Reason for retropharyngeal extension in large goiters still remains an enigma with anatomical arrangement of deep fascia,^[12] favoring a retrosternal extension. Further research is required to determine if body habitus like short neck or kyphotic spine has any role to play in the retropharyngeal extension of goitre as we had found similar extension but of smaller degree in two other short and stocky women previously but could not document it in this case report.

REFERENCES

1. Brunnicardi F, Andersen DK, Billiar TR, Dunn DL, Hunter JG, Matthews JB, *et al.* Schwartz Principles of Surgery. Thyroid, Parathyroid and Adrenal. 10th ed. New York: McGraw-Hill; 2010. p. 1521-90.
2. Govindaraj S, Rezaee R, Pearl A, Som PM, Urken ML. Radiology quiz case. Thyroid goiter presenting as a retropharyngeal mass. Arch Otolaryngol Head Neck Surg 2003;129:1013-4.
3. Chin SC, Rice H, Som PM. Spread of goiters outside the thyroid bed: A review of 190 cases and an analysis of the incidence of the various extensions. Arch Otolaryngol Head Neck Surg 2003;129:1198-202.
4. Standring S. Gray's Anatomy. 39th ed. London: Elsevier Churchill Livingstone; 2006. p. 561.
5. Kissane JM. Anderson's Pathology. 8th ed., Vol. 2. St Louis, Mosby: Thyroid Gland; 1985. p. 1400-3.
6. Damjanov I, Lindus J. Anderson's Pathology. 10th ed., Vol. 2. St. Louis: Mosby; 1996. p. 1948-51.
7. Rosai I. Rosai and Ackerman's Surgical Pathology. 9th ed., Vol. 1. Philadelphia, PA: Elsevier; 2004. p. 523-4.
8. Lakhani R, Nijjar R, Fishman JM, Jefferis AF. A retropharyngeal multinodular goitre. Annals 2010;92:E35-7.
9. Shamim M. Retropharyngeal Goitre. J R Coll Surg Edinb 1978;23:367-8.
10. Baik FM, Zhu V, Patel A, Urken ML. Airway management for symptomatic benign thyroids with retropharyngeal involvement: Need for a surgical airway with report of 2 cases. Otolaryngol Case Reports 2017;10:003.
11. Boyd W. Surgical Pathology. The Thyroid. 6th ed. St. Louis: Mosby; 1976. p. 1080-2.
12. Hahn M, Jones A. Last's Anatomy. Head and Neck. 8th ed. London: Churchill; 2000. p. 430.
13. Som PM, Curtin H. Fascia and Spaces. 3rd ed., Vol. 2. St Louis, Mo: Mosby-Year Book; 1996.

How to cite this Article: Khan B, Ganji R, Prasad BL. Riedel's thyroiditis presenting as large retropharyngeal goiter - A rare case. J. Health Sci., 2018; 5(1):150-152.

Source of Support: Nil, **Conflict of Interest:** None declared.