

Giant cell fibroma of the buccal mucosa- a case report

Imran Mohtesham^{1*}, Moidin Shakil,¹ Maji Jose¹, Javed²

¹Department of Oral Pathology and Microbiology, Yenepoya Dental College, Yenepoya University, Mangalore, Karnataka, India

²Department of Oral Medicine and Radiology, Yenepoya Dental College, Yenepoya University, Mangalore, Karnataka, India

ABSTRACT

Giant cell fibroma is a non neoplastic reactive lesion occurring in the oral cavity. The lesion is so named because of the presence of typically large stellate shaped multinucleated giant cell. Although the lesion is benign in nature, continuous trauma and irritation can make it grow large. In such circumstances biopsy may become mandatory.

Keywords: giant cell fibroma, hyperplastic lesion, reactive lesion.

Introduction

Oral mucosa manifests a spectrum of diseases because of its constant exposure to various external and internal stimuli. Reactive hyperplastic lesions are one of the most frequently encountered lesions in the oral cavity which has a unique masticatory apparatus programmed by the stomatognathic system. Kfir *et al* (1980) have exclusively classified reactive hyperplastic lesions into pyogenic granuloma (PG), peripheral giant cell granuloma (PGCG), peripheral ossifying fibroma (POF) and fibrous hyperplasia (FH).[1] These lesions represent a reaction to some kind of irritation or low grade injury like trapped food, chewing, fractured teeth, calculus and iatrogenic factors including overextended flanges of dentures and overhanging dental restorations.[2]

Giant cell fibroma is a non neoplastic, reactive lesion of the oral cavity first reported by Weathers and Callihan in 1974[3]. The lesion is so termed owing to the presence of characteristically large stellate shaped multinucleated fibroblasts that tend to occur in close proximity to the overlying epithelium.

Case report

A thirty eight year old male patient reported to the outpatient department of our dental College with a growth in the buccal mucosa along the line of

occlusion measuring 1.5x2cm with a history of six months duration. A clinical diagnosis of fibroma was made followed by an excision. On gross examination of the specimen the lesion was firm in consistency and the surface showed irregular depression resembling impression of the posterior teeth. The biopsy tissue was processed by routine paraffin embedding technique and sections stained with H & E were studied under the microscope. On histological examination the lesion was made up of bundles of collagen interspersed with fibroblasts and fibrocytes along with many stellate shaped giant fibroblasts. Many blood vessels with extravasation of RBCs and mild inflammatory infiltrate were also seen. The overlying epithelium showed parakeratosis. Based on above findings a diagnosis a giant cell fibroma was given.

Discussion

Giant cell fibroma (GCF) is a clinically and histologically distinct entity from other reactive lesions of the oral cavity. Weathers and Callihan (1974) described a benign fibrous lesion which was earlier diagnosed as fibroma³ on the basis of unusual and distinctive clinical and histological features to warrant separation and reclassification as a separate entity. GCF constitutes 1% of all oral biopsies and 5% of all oral mucosal lesions.⁴ It is known to be more common among females and usually occurs in the age group of 20 to 30 years (60%). Most commonly involved site is gingiva followed by tongue, palate and buccal mucosa. Mandibular gingiva is more commonly involved than its counterpart.⁵ It can be seen in other sites,

*Correspondence

Dr. Imran Mohtesham

Department of Oral Pathology and Microbiology, Yenepoya Dental College, Yenepoya University, Mangalore, Karnataka, India. E Mail: himohtesham@yahoo.com

especially the nose, and differs from irritational fibroma in two ways: it contains cells (fibroblasts) with large, angular nuclei, especially near the surface of the fibrous mass, beneath the overlying epithelium; and it has a greater tendency to recur[6]. The histological architecture of GCF is the consistent diagnostic feature of the lesion. Microscopic examination shows multiple large stellate shaped and sometimes multinucleated fibroblasts (giant cells) in a loosely arranged vascular fibrous connective tissue. The lesion is characterized by a diffuse, somewhat immature, rather avascular collagenic stroma with small bipolar and slightly stellate fibroblasts scattered throughout in moderate numbers. Occasional fibroblasts will be quite large and angular, and may have more than one nucleus. These pathognomonic cells are never hyperchromatic, as they would be if they were truly dysplastic fibroblasts, and they often have a smudged appearance[5]. Differential diagnosis encompasses a wide array of lesions, it differs significantly from routine fibromas in that its stroma contains scattered fibroblasts with very large, usually angular (stellate), but not hyperchromatic nuclei. The clinical diagnosis of ossifying fibroma is a logical inclusion in the differential diagnosis of this lesion, as it can look much like the GCF. Clinically ossifying fibromas to have typically normal mucosal color like GCFs, but they have islands of osteogenic cells dispersed throughout the lesion[6]. Unlike GC, peripheral ossifying fibroma is found only in the gingiva, occurs more in females, and is thought to arise from the periodontal ligament[7, 8]. The diagnosis of giant cell fibroma is done on clinical and histological basis. The treatment for the lesion is the surgical excision.

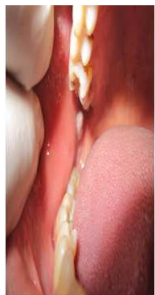

Fig 1: clinical picture showing giant cell fibroma



Fig 2: GCF histological picture under lower magnification

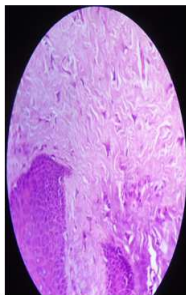


Fig 3 histological picture of GCF showing giant stellate fibroblast

Conclusion

Giant cell fibroma is a non neoplastic lesion of the oral cavity with unique histopathological characteristics. Although the lesion is innocuous and benign in nature, but any change in size due to the presence of continuous source of irritation can be suspicious, hence it is incumbent to for biopsy in such circumstances.

References

1. Kfir Y, Buchner A, Hansen LS. Reactive lesions of the gingiva. A clinico-pathological study of 741 cases. *J Periodontol.* 1980; 51:655-61.
2. Zarei MR, Chamani G, Amanpoor S. Reactive hyperplasia of the oral cavity in Kerman Province, Iran: a review of 172 cases. *Br J Maxillofac Surg.* 2007; 45(4):288-92
3. Weathers DR, Callihan MD: Giant cell fibroma. *Oral Surg Oral Med Oral Pathol* 1974; 37: 374-384
4. Antony V and Khan R. Giant Cell Fibroma – a case report. *Journal Of Dental and Medical Sciences.* 2013; 6(6): 117-119.
5. Neville BW, Damm DD, Allen CM, Bouquot JE. *Oral and maxillofacial pathology*, 3rd edition, Saunders Elsevier, St. Louis, 2009, p 439-40.
6. Sekar B, Augustine D, and Murali S. Giant Cell Fibroma- A case report with review of literature. *Indian Journal of dental Sciences.* 2011; 5(3): 48-50.
7. Neville BW, Damm DD, White DK. *Color atlas of clinical oral pathology* 2nd Ed. Baltimore (MD): Lippincott Williams & Wilkins; 1999. 276-7.
8. Regezi JA, Sciubba JJ, Jordan RCK. *Oral pathology: clinical pathologic correlations.* 4th ed. St. Louis (MO): W.B. Saunders; 2003. 158-9

Source of Support: Nil

Conflict of Interest: None