

Complete hydatidiform mole coexisting with a viable fetus in a twin pregnancy – a case report

Sandeep J, Divyashree, Pallovie Singh*, Rajesh Saket.

Government medical college, Haldwani, Uttarakhand, India

ABSTRACT

Cases of twin pregnancy where a normal viable fetus coexists with a hydatidiform mole have been reported rarely. The incidence ranges from 1 in 20,000 to 1 in 1, 00000 pregnancies. This condition is a consequence of dizygotic twinning. The fetus, in such cases, is chromosomally normal as opposed to the mole. We report one such case where a twin pregnancy consisted of a viable 12 week old fetus and its normally formed placenta coexisting with a complete hydatidiform mole in the other twin sac. There is a greater risk of persistent trophoblastic disease (50–60%) in cases where a complete mole coexists with a fetus as opposed to single molar pregnancies (14%). By reporting this case, we strive to highlight the need for more vigilant obstetric surveillance in such patients by serial beta-HCG estimation, and sonographic evaluation in conjunction with doppler and MRI when available.

Keywords: Inflammatory internal resorption, Diagnosis, Management

Case Report

A 25 year-old primigravida with 12 weeks gestation reported to the emergency room with complaints of pain abdomen, recurrent vaginal bleeding, headache and palpitations. She gave a history of episodes of slight vaginal bleeding in the past. A general physical exam was unremarkable. Abdominal palpation revealed a fundal height corresponding to 18 weeks (large for gestational age). A separate mass was palpable on the left side of the uterus. Upon auscultation normal foetal heartbeats could be heard on the right side. A sonographic evaluation of the abdomen revealed a viable and structurally normal 12 week old fetus and placenta in the right side of the uterine cavity. The placenta was normally formed, posteriorly located and showed grade I maturity. A concurrent mass could be seen in the left side of the uterine cavity, with characteristic snow storm appearance and multiple small cystic spaces within the mass. This sonographic morphology was consistent with a complete hydatidiform molar pregnancy (Figure 1). A subchorionic hematoma, separate from the placenta, was also observed in the region of the mole. Both the ovaries were normal, with no evidence of theca lutein cysts. Serum titre of beta-hCG at 12 weeks was 130000 mIU/ml.

*Correspondence

Pallovie Singh

Government medical college haldwani Uttarakhand

E Mail: pallovie.singh@gmail.com

X-ray chest and liver function tests were normal. The serum levels of thyroid hormones were mildly raised. The prognosis and possible obstetric outcome were explained. The patient was advised admission to the inpatient department and kept under observation. An MRI scan confirmed the sonographic findings, with no obvious invasion of the myometrium and the zone of transition between mole and the myometrium showing clearer delineation (Figure 2). The subsequent clinical course of the patient consisted of gradually worsening symptoms with increased bouts of dirty vaginal discharge and characteristic grape like vesicles. The patient underwent spontaneous abortion at 13 weeks of gestation with expulsion of the hydatidiform mole. The patient delivered a foetus two days after the expulsion of the mole. Suction and curettage was later performed to remove any retained products of conception. The histopathology of the abnormal posterior placenta revealed grapelike, vacuolar degeneration of chorionic villi and abnormal, excessive proliferation of placental trophoblasts. Karyotyping of the baby's white cells and mole revealed normal 46-XX chromosomal patterns. Mother's chest radiograph, abdominopelvic sonography and serum beta HCG marker study done postpartum did not reveal any abnormality. No chemotherapy was given. However, she was kept under observation and asked to report after 3 months. The need for obstetric surveillance was explained to the patient.

Discussion

Twin pregnancies with a molar pregnancy and a co-existing viable fetus have been described. The cases with gestational trophoblastic disease concurrent with normal intrauterine pregnancy have been reported as rarely as one in 20,000-1, 00,000 pregnancies [1, 2]. Gestational trophoblastic disease (GTD) includes a spectrum of disorders characterized by abnormal proliferation of trophoblasts with progressive malignant potential. GTD includes molar pregnancy, invasive mole, choriocarcinoma and placental site trophoblastic neoplasia with varying degrees of malignant potential. Hydatidiform mole constitutes 80% of cases of GTD and includes complete hydatidiform mole (also called classic hydatidiform mole) and partial hydatidiform mole. A „complete mole“ represents total replacement of the normal placenta by grossly dilated, hydropic villi. It is usually not associated with foetus or foetal parts, except with a coexisting twin pregnancy. When an *empty* ovum is fertilized by single sperm with duplication of the paternal haploid set of chromosomes a 46-XX karyotype is produced (46-YY is lethal). A „partial mole“ contains molar tissue along with abnormal fetal parts. When a *normal* haploid ovum is fertilised by two haploid sperms a „partial mole“ is formed. This contains a triploid karyotype (69 chromosomes) [3]. In case of a partial mole foetal parts are almost always present but are abnormal. The pregnancy does not usually last beyond the first trimester. The majority of cases of pregnancies of hydatidiform mole with a coexistent live fetus diagnosed antenatally by ultrasound examination can be categorized either as a “twin gestation”, in which it is postulated that one gestation develops normally with a normal karyotype while the second undergoes complete molar degeneration or as a “partial mole”, described as conceptus with an abnormal fetus and a single placenta manifesting diffuse hydatidiform changes. Both partial and complete moles are noninvasive aberrations that demonstrate both proliferation and hydropic swelling of the villi. Histologic analysis shows the villi to have a prominent, central a cellular space, which accounts for the macroscopic appearance of fluid-filled vesicles. Microscopic evaluation shows trophoblastic hyperplasia which accounts for the characteristic marked elevation of beta-hCG levels, which may lead to hyperemesis or development of the calutein cysts. Serum beta-HCG levels in molar pregnancy are abnormally elevated, commonly over 1,00,000 mIU/ml. Patients with molar pregnancy most commonly present with vaginal bleeding, rapid uterine enlargement, large for date uterus, hyperemesis

gravidarum or preeclampsia before 24 weeks. If a foetus is identified in this syndrome it is rarely alive at the time of diagnosis, and generally manifests a constellation of congenital anomalies associated with triploidy. In the twin gestational syndrome the fetus will have normal diploid chromosomal karyotype as the condition is usually the result of dizygotic twinning. When the diagnosis has been made antenatally, most patients have opted for termination of the pregnancy to avoid the risks of malignant change and complications such as pre-eclampsia and antepartum hemorrhage [1]. Sonography is the initial modality of choice in the diagnosis [4, 5]. The sonographic appearance of hydatidiform mole has been characteristically described as “snow storm appearance”. Numerous discrete, small, anechoic (cystic) spaces within a central area of heterogeneous echotexture may be identified within the uterus. The small cystic areas correspond to the hydropic villi characteristically seen at gross pathologic examination. A complete hydatidiform mole (CHM) may have variable appearances in the first trimester [6]. A large, central fluid collection that mimics an embryonic gestation or missed/incomplete abortion may be seen. Occasionally, there is merely a central mass of variable echogenicity, presumably because the villi are too small to be detected by sonography at this time. Molar tissue has been seen to have a characteristic appearance on MRI. The molar tissue appears hyperintense on the T2 W images [7]. The myometrium is clearly shown as a separate structure and this allows accurate assessment of invasion. MRI findings may include: a) heterogeneous endometrial enlargement with several hyperintense foci that represent hydropic villi on T2-weighted imaging; b) focal tumoral masses in the endometrium and/or myometrium; c) loss of uterine zonal anatomy (indistinctness of the endometrial-myometrial border); and d) pathologic myometrial, endometrial, and parametrial vasculature characterized by dilated and tortuous vessels [8, 9, 10]. Importantly, 15% of women with complete hydatidiform mole and less than 1% of patients with partial hydatidiform mole will develop recurrent disease in the form of invasive mole or choriocarcinoma. Recent reviews indicate that there is a greater risk of developing persistent trophoblastic disease (50–60%) in cases of CHM and a co-existing fetus compared with a single molar pregnancy (14%) and that when present, it more commonly progresses to metastatic disease [1]. To date no significant mortality has been reported as most of these cases have been terminated estrogenically or aborted spontaneously [11]. All patients need to be followed up with successive serum beta-HCG measurements to allow early detection of persistent

gestational trophoblastic neoplasia (i.e., invasive mole or choriocarcinoma). Serial monitoring of beta-HCG levels during the first year after treatment of complete hydatidiform mole is thus, very important. Pregnancy should therefore be avoided during this time as it causes raised beta-hCG levels [6]. Patients with invasive mole present with bleeding per vaginum and persistent elevations in the serum beta-hCG level. Imaging may show a central uterine process similar to that described for complete hydatidiform mole, occasionally with demonstrable myometrial invasion. For obstetric surveillance ultrasound proves to be an important diagnostic tool, and several predictors for suspicion of invasive changes have been put forward [11]. The important ones are the presence of

endometrial thickening (>10 mm) with hyper vascularisation upon TV-US (trans-vaginal ultrasonography), or myometrial nodules (hyperechogenic areas of increased vascularization within the myometrium). Doppler US may be useful in the evaluation of GTD. These vascular tumors tend to show very high blood flow (more specifically, high diastolic flow). Presumably the result of decreased vessel tone in the proliferating neoplasm has been identified in patients with persistent gestational trophoblastic neoplasia. A decrease in uterine artery pulsatility maybe of some use in the diagnosis of cases that may mimic other conditions (e.g., threatened abortion or uterine atony). The persistently elevated beta-HCG level will usually indicate the diagnosis.

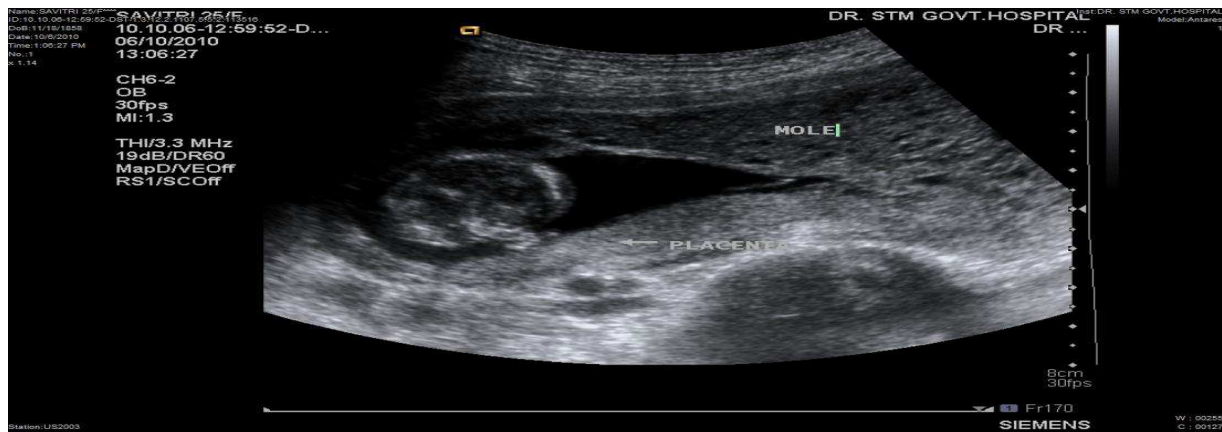


Figure 1: Evidence of complete hydatidiform mole along the left side of the uterus with a coexistent twin live gestation and its separate normal placenta along the right side of the hydatidiform mole

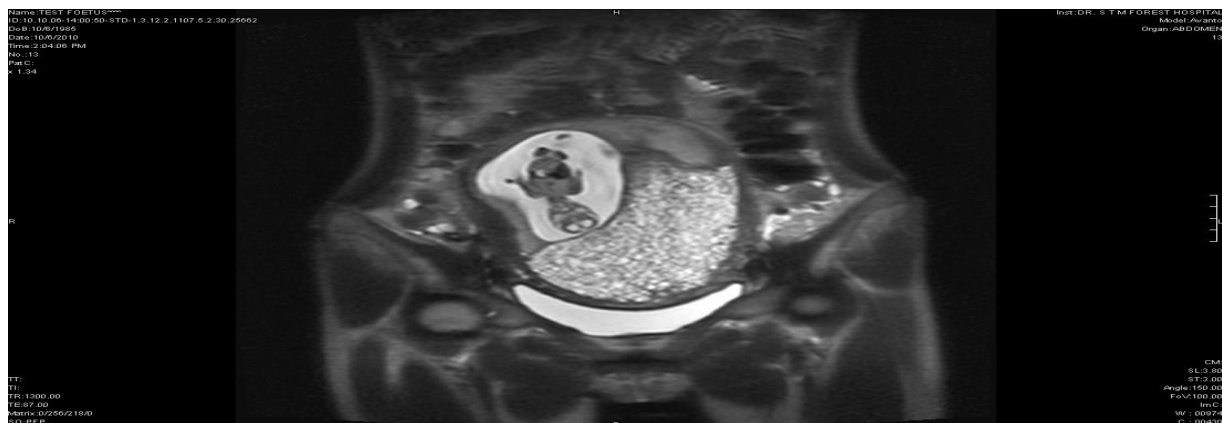


Figure 2: T2W coronal MRI shows similar changes as sonography with the molar tissue appearing hyperintense on the left (double white arrows) and a coexistent twin gestation with normally formed posterior

placenta along the right. A focal area of subchorionic bleeds (single white arrow) complicating the hydatidiform mole is appreciated well on this MRI.

Conclusion

The coexistence of a twin pregnancy with a viable fetus in one sac and mole affecting the other twin is a very rare incidence. The obstetric outcome usually culminates in spontaneous abortion/iatrogenic termination due to the inherent complications of the mole. Also there is a greater risk of recurrent/persistent gestational neoplasia in a coexistent twin pregnancy with an associated mole. Strict guidelines, therefore, need to be laid in such cases for obstetric vigilance.

References

1. Steller MA, Genest DR, Bernstein MR, Lage JM, Goldstein DP and Berkowitz RS. Natural history of twin pregnancy with complete hydatidiform mole and coexisting fetus. *ObstetGynaecol* 1994; 83:35-42.
2. Jinno M, Ubukata Y, Hanyu I. Hydatidiform mole with a surviving coexistent fetus following in-vitro fertilization. *Hum Reprod* 1994;9:1170-2.
3. Feinberg RF, Lockwood CJ, Salafia C, Hobbins JC. Sonographic diagnosis of a pregnancy with a diffuse hydatidiform mole and coexistent 46, XX fetus: A case report. *ObstetGynecol* 1988; 72:485-8.
4. Allen SD, Lim AK, Seckl MJ. Radiology of gestational trophoblastic neoplasia. *ClinRadiol* 2006;61(4):301-13.
5. DeBaz BP, Lewis TJ. Imaging of gestational trophoblastic disease. *SeminOncol* 1995; 22(2):130-41.
6. Carter J, Fowler J, Carlson J. Transvaginal color flow Doppler sonography in the assessment of gestational trophoblastic disease. *J Ultrasound Med* 1993;12(10):595-9
7. Barton JW, McCarthy SM, Kohorn EI. Pelvic MR imaging findings in gestational trophoblastic disease, incomplete abortion and ectopic pregnancy: are they specific? *Radiology* 1993; 186(1):163-8.
8. Hricak H, Demas BE, Braga CA. Gestational trophoblastic neoplasm of the uterus: MR assessment. *Radiology* 1986;161(1):11-6.
9. Imaoka I, Sugimura K, Masui T. Abnormal uterine cavity: differential diagnosis with MR imaging. *MagnResonImaging* 1999;17(10):1445-55.
10. Zhou Q, Lei XY, Cardoza JD. Sonographic and Doppler imaging in the diagnosis and treatment of gestational trophoblastic disease: a 12 year experience. *J Ultrasound Med* 2005; 24(1):15-24.
11. Fishman DA, Padilla LA, Ken P. Management of twin pregnancy consisting of a complete hydatidiform mole and a normal fetus. *Obstet Gynaecol* 1998; 91:546-550.
12. Dighe M, Cuevas C, Moshiri M, Dubinsky T, Dogra VS. Sonography in first trimester bleeding. *J Clin Ultrasound* 2008; 36(6):352-66.

Source of Support: Nil

Conflict of Interest: None