

## Ovarian ectopic pregnancy- a report of 2 cases and review of literature

Ruchi Rathore<sup>1\*</sup>, Ruchi Bansal<sup>1</sup>, Ritu Sharma<sup>2</sup>, Rita Jindal<sup>2</sup>, Namrata Nargotra<sup>1</sup>

<sup>1</sup>Assistant professor, Department of Pathology, NDMC and Hindu Rao Hospital, New Delhi, India

<sup>2</sup>Senior Resident, Department of Pathology, NDMC and Hindu Rao Hospital, New Delhi, India

<sup>3</sup>Associate Professor, Obstetrics and Gynecology Department, NDMC and Hindu Rao Hospital, New Delhi, India

<sup>4</sup>Consultant, Obstetrics and Gynecology Department, NDMC and Hindu Rao Hospital, New Delhi, India

<sup>5</sup>Head of Department, Department of Pathology, NDMC and Hindu Rao Hospital, New Delhi, India

### ABSTRACT

Ovarian pregnancy is a rare form of ectopic pregnancy accounting upto .3-3% of all non tubal ectopics. Even though the incidence of ovarian ectopic pregnancies is on a rise attributable to recent advancements in the field of reproductive medicine especially the assisted reproductive techniques, primary ovarian ectopic is still a rarely encountered entity in clinical practice. We present 2 such rare cases diagnosed clinically and proven histopathologically. We conclude that owing to the risk of circulatory failure as well as permanent damage to the ovaries it is imperative to keep a high suspicion index and diagnose them early in the course of disease.

**Key Words:** Ovary, Ectopic Pregnancy, Ruptured Ovary, Human Chorionic Gonadotropin, Ectopic Gestation

### Introduction

Ectopic pregnancy is defined as implantation of fertilized ovum outside the uterine cavity, either in tubes, ovary or in abdominal cavity. Tubal gestation is by far the most common form of ectopic pregnancy (97%). With an incidence of merely 0.3-3% [1], ovarian pregnancy is a rare form of nontubal ectopic pregnancy. Such cases are usually diagnosed at the time of surgery. Although the exact etiology is still unknown, studies have revealed that intrauterine contraceptive devices and fertility treatments are important associated risk factors [2]. Even though the incidence of ovarian ectopic pregnancies is on a rise attributable to recent advancements in the field of reproductive medicine especially the assisted reproductive techniques, primary ovarian ectopic is still a rarely encountered entity in clinical practice. We present 2 such rare cases diagnosed clinically and proven histopathologically.

\*Correspondence

**Dr. Ruchi Rathore**

Assistant Professor, Department of Pathology, NDMC and Hindu Rao Hospital, New Delhi, India.

**E Mail:** [ruchirathore13@gmail.com](mailto:ruchirathore13@gmail.com)

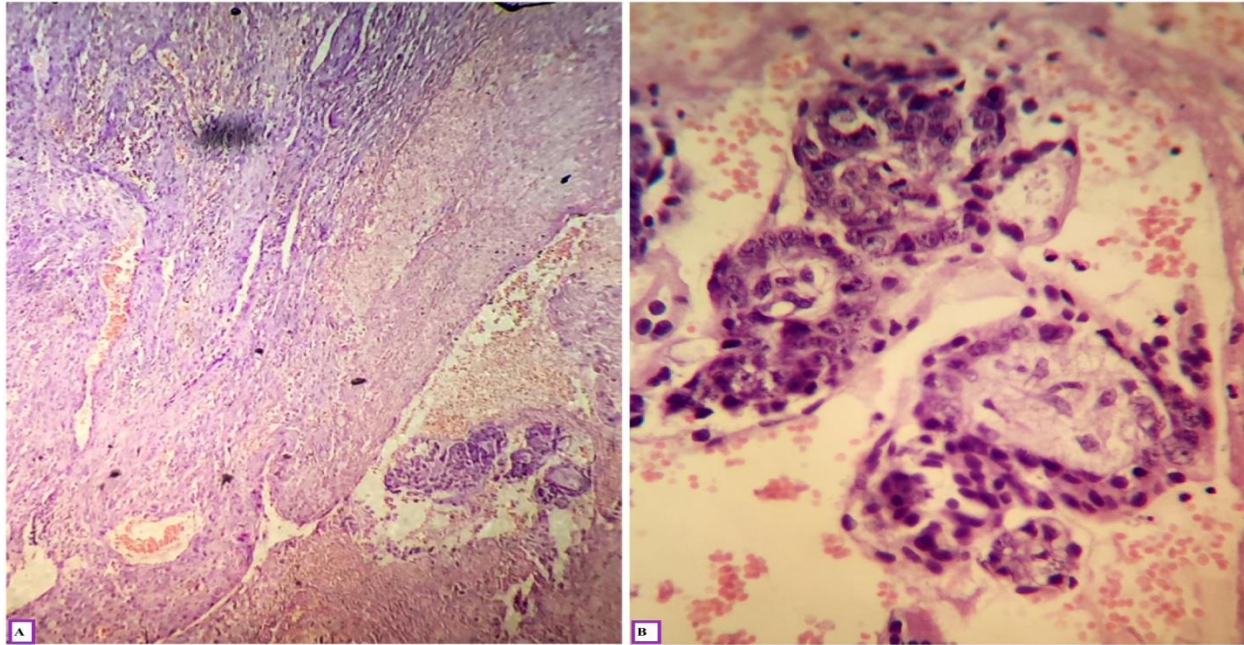
### Case Report

#### Case 1

A 28 years (Gravida5Para 2 Live 2Abortion1) female came to gynecology emergency with history of amenorrhea and pain abdomen for 6 weeks, bleeding per vaginum for 4 days. Her urine pregnancy test was positive. Her past obstetric history involved 2 normal vaginal deliveries with last childbirth 2 years back followed by an abortion 4 months back. There was no history of irregular menstrual bleeding or use of any contraceptive device. No history of any medical illness, pelvic inflammatory disease or tuberculosis was noted. On examination the patient was pale with a pulse of 80/min and BP of 110/80mm Hg. On investigation her hemoglobin was 7gm/dl, total leucocyte count was 11000/cumm and rest of the investigations were within normal limits. On per abdomen examination mild tenderness was present in right iliac fossa. Per speculum examination revealed a healthy cervix and vagina with bloody discharge. Per vaginum examination revealed a bulky and anteverted uterus with tenderness in right fornix. On ultrasound however there was no intrauterine gestational sac and a right sided adenexal hypoechoic mass not separate from the ovary was seen. There was free fluid in the pouch of douglas. Considering the clinical and radiological

findings, a diagnosis of ectopic pregnancy was made and surgery was planned. On laparotomy uterus and bilateral tubes were normal and blood was oozing from a ruptured right ovary. Right oophorectomy was done and sample was sent for histopathology. Grossly grey

brown hemorrhagic tissue was received in multiple pieces. On microscopic examination chorionic villi and trophoblastic tissue were found in the ovarian parenchyma. A diagnosis of ruptured ovarian ectopic pregnancy was confirmed on microscopy (Figure 1)

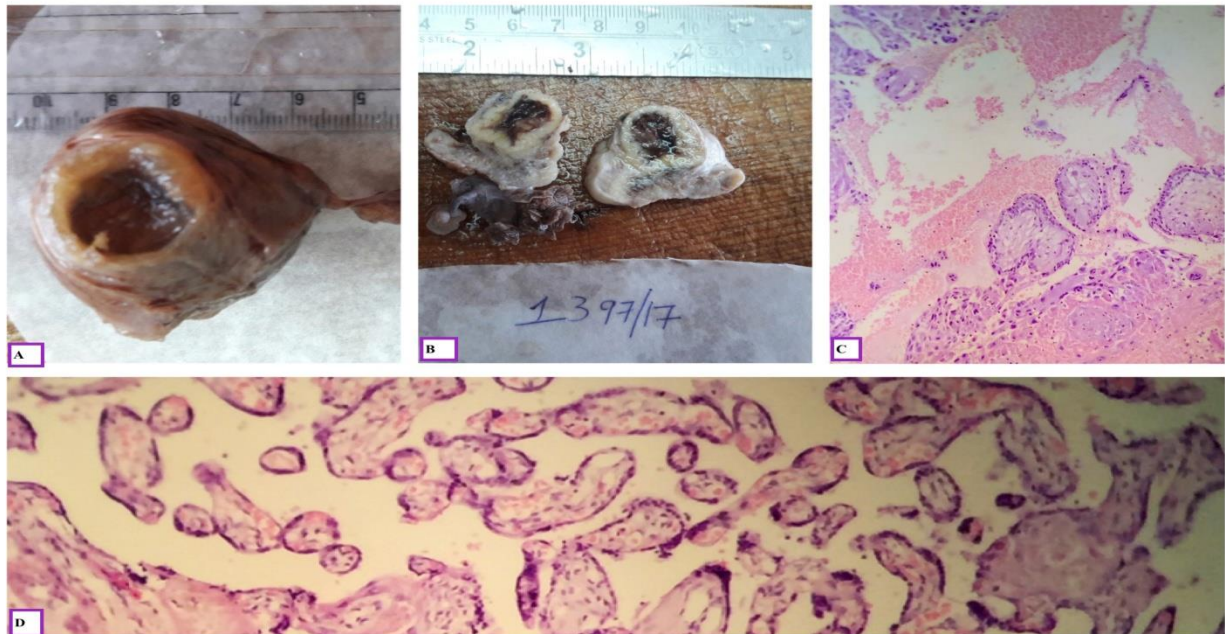


**Figure 1: (A) Low power image of chorionic villi seen invading the ovarian parenchyma surrounded by hemorrhage. (H&E, 100 X). (B) High power image showing chorionic villi(H&E 400 X).**

## Case 2

A 32 years G4P3L3 female patient came to emergency department with history of 6 weeks of amenorrhea, pain abdomen and dizziness. Her urine pregnancy test was positive and beta HCG levels were raised. She had all 4 normal vaginal deliveries with last child birth one and a half year back. Her previous menstrual history was normal and history of any chronic medical illness was absent. There was no history of use of intrauterine contraceptive device or fertility treatment in the past. On examination, patient had mild pallor, BP was 100/78Hg and a pulse of 84/min was noted. On investigation Hb was 9gm% and rests all the investigations were within normal limits. Per abdominal examination was unremarkable except for mild tenderness in the right iliac fossa. On per vaginal examination, uterus was bulky and tenderness was present in right fornix. Ultrasonography suggested of an empty uterine cavity with a right sided tubo-ovarian

mass. A diagnosis of heterotopic pregnancy was suggested and patient was given methotrexate. However even after medication beta HCG levels did not fall, so an emergency laparotomy was performed and right salpingo-oophorectomy was done. Simultaneously endometrial biopsy was also done. Samples were sent for histopathology. On gross examination ovary was intact with a ruptured follicle on its surface. Cut section revealed a brownish haemorrhagic area measuring 1x1cm. Microscopic examination revealed a ruptured corpus luteal cyst in the area of ruptured follicle along with presence of chorionic villi and trophoblastic tissue in ovarian parenchyma. Endometrial biopsy showed decidual changes only. A diagnosis of primary ovarian pregnancy was thus confirmed on histopathology.(figure 2)



**Figure 2: (A & B) Gross images of the ovary showing gestation sac surrounded by corpus luteum. (C & D) Low and high power images of Chorionic villi within ovarian parenchyma. (H&E, 100 X & 400 X)**

### Discussion

In literature incidence of ovarian pregnancy is 0.001%-0.013% of normal pregnancy accounting for nearly 3% of all the ectopic gestations[4]. Chronic pelvic pain is the most common chief complaints in majority of the patient (93%) followed by vaginal bleeding (71%) and circulatory collapse (43%)[5]. Due to similar clinical signs and symptoms to tubal pregnancy or a bleeding corpus luteum the differential diagnosis include ruptured haemorrhagic corpus luteum, chocolate cyst or tubal ectopic pregnancy[6]. Owing to the rarity of this disease a majority of them are still misdiagnosed as corpus luteal haemorrhagic in the clinical settings. The overall incidence of ectopic pregnancy has been found to be on a rise recently. This may be due to increased prevalence of sexually transmitted diseases, pelvic inflammatory diseases, induced abortion, assisted reproductive techniques and increased availability of diagnostic facilities. Joseph and Irvine have reviewed cases over 15 years and found that infertility treatment and IUCDs are the major reason accounting for 18.1% and 19.3% respectively [7]. Presence of IUCD leads to changes in prostaglandin synthesis that increases the tubal motility, leading to implantation in ovary itself. Intrauterine contraceptive devices (IUCD) are thought to be responsible for ectopic gestation in 14-30% of non-ovarian and 57-

90% of primary ovarian pregnancies. Both our cases however did not have history of any IUCD insertion.

In true ovarian pregnancy, the ovum is fertilized in graffian follicle, while leaving the follicle in the abdominal cavity itself. Depending on the location of fertilization of ovum, ovarian ectopics are further classified into primary and secondary ovarian ectopic pregnancies[3]. Primary ectopic pregnancy is usually a result of ovarian dysfunction whereas secondary ectopic results from secondary implantation in ovarian stromal tissue after tubal abortion or perforation.

The diagnosis of primary ovarian pregnancy is made on the age old criteria of Spiegelberg of 1878[8]. These include

1. Intact tube on the involved side.
2. Gestation sac in the region of ovary.
3. Histologically proven gestation sac in ovarian tissue.
4. Ectopic pregnancy attached to the uterus by the utero-ovarian ligament.

In both our cases the fallopian tubes of involved side were intact with histologically proven gestation in ovarian parenchyma. Therefore a diagnosis of primary ovarian pregnancy was made. On Ultrasonography, both grey scale and color Doppler along with high serum HCG may lead to suspicion. Quite often however the diagnosis is made on surgery but

confirmed only on histopathology. Transvaginal ultrasound has also been found to play some role in the diagnosis[9] It is estimated that only in 28% of cases the diagnosis is made on surgery and a majority of these cases are misdiagnosed as hemorrhagic corpus luteum intraoperatively[10] In one of our cases where the ovary was intact, we could only confirm a corpus luteum hemorrhagicum initially. Due a strong clinical suspicion and the conviction of our gynecologist in this case we extensively grossed the specimen and processed it all. It was then that it was diagnosed as primary ovarian gestation along with corpus luteal hemorrhagicum in the same ovary. Mainstay of the treatment in primary ovarian pregnancy still remains surgery. In cases presenting early a trial of medical termination with methotrexate can be done as was done in one of our cases. The options of surgeries could range from ovarian wedge resection, ovarian pregnancy

enucleation, trophoblast curettage with coagulation of bed of ovarian pregnancy and oophorectomy depending on how much ovary can be salvaged. In contrast to tubal ectopics which rupture early in the course of their disease, the fate of ovarian pregnancies differ, as some of them may even last upto third trimester. Devi Goyal et al[7] have even reported a case of term ovarian pregnancy with live birth of the fetus. According to the literature 91% of the ovarian pregnancies rupture by the end of first trimester, 5.3% in second and 3.7% lasts up to the third trimester [7]. This may be due to presence of ample space for the ovaries to accommodate the gestation as compared to the fallopian tubes. Apart from this however since ovaries have a much higher vascularity during pregnancy, they may also rupture if not diagnosed timely leading to haemorrhage and hypovolemic haemorrhagic shock[11].

**Table 1: Comparison of Clinicopathological features and risk factors amongst various studies**  
@ Obstetric History; # Amenorrhea \$ultrasound ; \* Intrauterine gestation sac

STUDY	Age	Obs his <sup>@</sup>	Side	UPT	Clinical features	Risk Factors	USG\$	SURGERY
Dhaiya S et al[12]	30Y	G2P1L1	Left	Positive	1½ months amen#. Pain in lower abdomen & syncope	-		
Shinde S et al[13]	32Y	G4P3L3	Right	Positive	7 Weeks amen. pain abdomen and BPV <sup>\$</sup> 2 days	-	No Intrauterine gestational sac* (I/U g sac) Hemoperitoneum and hypochoic shadow in right adenexa. Uterine cavity empty	
Mendiratta SL et al[8]	23Y	G2P1L1	Left	Positive	No amen. Pain abdomen and vomiting, syncope X 1 day.	OCPX 2 years	No I/U gsac * Left adenexa bulky	Left sided partial oophorectomy with cystectomy
Singh N et al[3]	25Y	G2P1L1	Right	positive	6 weeks ammenorrhoea with Bleeding P/V since 5 days and pain abdomen since 10 hours		No I/U gsac. Anirregular right adenexal hypochoic mass present	Right salpingo-oophorectomy after wedge resection
Singh N et al[3]	27Y	G3P2L2	Right	positive	5 weeks ammenorrhoea with Pain abdomen past one week	-	No I/U gsac heterogenous hyperechoic lesion containing irregular g sac	Right ovarian wedge resection followed by ovarian reconstruction.
Singh S et al <sup>14</sup>	23 Y	G2P1L1	Right	positive	2 months ammenorrhoea with pain abdomen on and off since 1 month		No I/U gsac right adenexal gsac with fetal pole approx.. 5 weeks 6 days with cardiac activity and free fluid in cul de sac.	Right sided partial ovariectomy.
Present study	28 Y	G5P2L2A1	Right	positive	6 weeks amenorrhea with pain abdomen and spotting per vagina sine 4 days		No I/U gsac with right sided adenexal hypochoic mass not separated from the ovary with free fluid in pouch of douglas.	Right oophorectomy
Present study	32 Y	G4P3L3	Right	positive	6 weeks of amenorrhea, pain abdomen and dizziness		No I/U gsac tubo-ovarian mass	rightsalpingo-oophorectomy

## Conclusion

Ovarian ectopic pregnancies are rare. However due to the advent of assisted reproductive techniques and increased use of IUCDs their incidence is on a rise. They are often misdiagnosed as corpus luteal cysts and pose a diagnostic challenge to the clinician and to the pathologists if not grossed extensively. Not only due to the risk of circulatory failure but also to salvage ovaries, it is imperative to keep a high suspicion index and diagnose them early in the course of disease.

## References

1. Salas Valien JS, Reyero Alvarez MP, Gonzalez Moran MA, Garcia Meyaro M, Nieves Diez C. Ectopic ovarian pregnancy. *An Med Intern.* 1995;12:192-4.
2. Sandviedsandstad E, Steir JA. Ovarian Pregnancy associated with intrauterine contraceptive device. *Acta Obstet Gynecol Scand.* 1987;66:137-41
3. Singh N, Sarmalkar M, Mehendale M, Nayak A. Ruptured primary ovarian ectopic pregnancy: A case series. *Int J Reprod Contracept Obstet Gynaecol.* 2016;5(10):3641-3644.
4. Scritiero G, Di Gioia P, Spade A, Greco P. Primary ovarian pregnancy and its management. *JSLs.* 2012; 16:492-494.
5. Goyal LD, Tondon R, Goel P and Sehgal A. ovarian ectopic pregnancy: a 10 years' experience and review of literature. *Iron J Reprod Med.* Dec 2014; 12(12): 825-830.
6. J. Hallat. Primary ovarian pregnancy. A report of twenty-five cases. *American J Obstet Gynaec.* 1982; 143:50-60
7. Joseph RJ Irvine LM. Ovarian ectopic pregnancy: Aetiology, diagnosis, and challenges in surgical management. *J Obstet Gynac.* 2012;32(5): 472-474.
8. Spigelberg O. Casusistik der ovarial schwangerschaft. *Arch Gynecol* 1878;13 :73
9. Bouyer J, Coste J, Fernandez H et al. Site of ectopic pregnancy. A ten year population-based study of 1800 cases. *Human Reproduction* 2002;17(12): 3224-3230
10. Ciortea R, Costin N, Chiroiu B, Malutan A, Mocan R, Hudacsko A, et al. Ovarian pregnancy associated with pelvic adhesions. *Clujul Med.* 2013;86:77-79
11. Mendiratta SL, Anand S, Mittal R, Khan F, Nargotra N. Primary ovarian pregnancy: Early diagnosis still a myth. *Int J Reprod Contracept Obstet Gynecol* 2016;5:3238-41.
12. Dhaiya S, Khan S, Premi H K, Amrin S, Srivastava S. Ovarian ectopic pregnancy: A rare case report. *Int J AdvInteg Med Sci* 2016; 1(1): 23-24.
13. Shinde S, Aher G, Gavali U. Case report of primary ovarian ectopic pregnancy: *Int J Healthcare and Biomed research.* July 2015; 3(4): 68-70
14. Singh S, Alwani M, Malukani K. Ruptured Primary Ovarian Ectopic Pregnancy: A rare case report. *Int J Reprod Contracept Obstet Gynecol* 2015; 4:480-2.

**Source of Support:** Nil

**Conflict of Interest:** None